

DURBAN UNIVERSITY OF TECHNOLOGY

**THE INTRA- AND INTER-EXAMINER RELIABILITY
OF THE RADIOGRAPHIC ASSESSMENT
OF THE CERVICAL LORDOSIS**

Dave Matthew Rankin

2016

**THE INTRA- AND INTER-EXAMINER RELIABILITY
OF THE RADIOGRAPHIC ASSESSMENT
OF THE CERVICAL LORDOSIS**

By

Dave Matthew Rankin

Dissertation submitted in partial compliance with the requirements for the
Master's Degree in Technology: Chiropractic

Durban University of Technology

I, Dave Matthew Rankin, do hereby declare that this dissertation is representative of my own
work in both conception and execution (except where acknowledgements indicate to the
contrary)

.....

Date:

Dave M. Rankin

Approved for Final Submission

.....

Date:

Dr. J. Shaik
M. Tech. Chiro., M. Med. Sci. (SM), MCASA
Supervisor

DEDICATION

I dedicate this dissertation to my parents, Marcel and Denise Rankin.

You are more than just my parents; you are the greatest role models I could have in my life. Your unconditional love, support and encouragement is the reason I am here today.

Thank you.

ACKNOWLEDGEMENTS

It is with my sincere gratitude and appreciation that I would like to thank the following individuals:

1. My supervisor, Dr. J. Shaik, of the Department of Chiropractic, Faculty of Health Sciences, Durban University of Technology, for his expert guidance in the planning of this research project, for his assistance with the analyses and interpretation of the data, and for his editorial advice. Without his continued help, patience and belief in me, this dissertation may never have materialised. His knowledge on the subject has been invaluable.
2. The radiograph examiners, who have preferred to remain anonymous, without whose help this dissertation would never have been completed.
3. The statistician, Mr. Deepak Singh, for his assistance with the statistical analyses used in this study.
4. The Durban University of Technology, for its financial support towards this study.
5. My parents, Marcel and Denise Rankin. I thank them for all the sacrifices, love and support throughout the years so that I could achieve my goals and for the good morals and faith that they have instilled in me.

ABSTRACT

Aim: To determine the intra- and inter-examiner reliability of the radiographic assessment of the cervical lordosis of asymptomatic adult males.

Participants: Eighty lateral plain film radiographs of the cervical spine of asymptomatic males aged 18-45 years (taken in a previous study) were utilised for this study. However, due to the obstruction of the C7 vertebral body by the trapezius muscle, the examiners were unable to assess the CL on all 80 plain film radiographs. Three examiners took part in the study viz. Examiner One who was a qualified chiropractor with three years of clinical experience, Examiner Two who was a qualified chiropractor with six years of clinical experience and Examiner Three who was a chiropractic master's student.

Methodology: The initial set of assessments of the CL using the C1-C7 and C2-C7 modified Cobb methods was completed by Examiner One and captured on an Excel spread sheet for Round One. The procedure was then repeated for Examiners Two and Three. The process was repeated for the second set of assessments (Round Two). Each examiner was given a maximum of two weeks to complete their assessments for each round. The data was statistically analysed using SPSS 22.0 and Stata 13. Descriptive data was presented in tables as mean and standard deviation at a 95% confidence interval while intra- and inter-examiner reliability was determined using the Kappa coefficient.

Results: The mean (\pm SD) CL values obtained by each examiner using the C1-C7 modified Cobb method for Round One was: Examiner One: $45.6^\circ (\pm 10.4^\circ)$ ($n = 70$), Examiner Two: $44.0^\circ (\pm 11.0^\circ)$ ($n = 75$) and Examiner Three: $43.8^\circ (\pm 12.0^\circ)$ ($n = 72$). The mean (\pm SD) CL values obtained by each examiner using the C1-C7 modified Cobb method for Round Two was: Examiner One: $46.7^\circ (\pm 10.7^\circ)$ ($n = 72$), Examiner Two: $43.3^\circ (\pm 11.1^\circ)$ ($n = 74$) and Examiner Three: $43.8^\circ (\pm 11.5^\circ)$ ($n = 72$).

The mean (\pm SD) CL values obtained by each examiner using the C2-C7 modified Cobb method for Round One was: Examiner One: $15.9^\circ (\pm 9.2^\circ)$ ($n = 72$), Examiner Two: $22.6^\circ (\pm 9.7^\circ)$ ($n = 75$) and Examiner Three: $17.2^\circ (\pm 9.7^\circ)$ ($n = 72$). The mean (\pm SD) CL values obtained by each examiner using the C2-C7 modified Cobb method for Round Two was: Examiner One: $16.3^\circ (\pm 9.4^\circ)$ ($n = 72$), Examiner Two: $20.5^\circ (\pm 9.0^\circ)$ ($n = 74$) and Examiner Three: $16.9^\circ (\pm 9.2^\circ)$ ($n = 72$).

The intra-examiner reliability obtained by each examiner using the C1-C7 modified Cobb method for Round One and Round Two was: Examiner One: $K = 0.16$, Examiner Two: $K = 0.11$ and Examiner Three: $K = 0.16$. The intra-examiner reliability obtained by each examiner using the C2-C7 modified Cobb method for Round One and Round Two was: Examiner One: $K = 0.21$, Examiner Two: $K = 0.04$, Examiner Three: $K = 0.22$.

The inter-examiner reliability obtained by each examiner using the C1-C7 modified Cobb method for Round One and Round Two respectively was: Examiner One vs Examiner Two: $K = 0.03$; $K = 0.09$, Examiner One vs Examiner Three: $K = 0.19$; $K = 0.15$, Examiner Two vs Examiner Three: $K = 0.03$; $K = 0.08$. The inter-examiner reliability obtained by each examiner using the C2-C7 modified Cobb method for Round One and Round Two respectively was: Examiner One vs Examiner Two: $K = 0.00$; $K = 0.01$, Examiner One vs Examiner Three: $K = 0.19$; $K = 0.11$, Examiner Two vs Examiner Three: $K = 0.02$; $K = 0.05$.

There was a significant difference in the intra-examiner findings for both the modified Cobb methods ($p < 0.05$). Using the C1-C7 modified Cobb method, there was a significant difference in the inter-examiner reliability findings between all three examiners for both rounds ($p < 0.05$). There was no significant difference in the inter-examiner findings of the CL using the C2-C7 modified method between Examiner One versus Examiner Two for Round One ($p = 0.33$) and Round Two ($p = 0.23$) but there was a significant difference in the findings between Examiner One versus Examiner Three ($p < 0.05$) and between Examiner Two versus Examiner Three ($p < 0.05$) for Round Two only.

Conclusion: The results of this study are in agreement with those of a previous study which reported that the C1-C7 modified Cobb method over-valued the magnitude of the curve while the C2-C7 modified Cobb method under-valued the curve. A significant difference in the intra-examiner findings suggests that recall bias did not significantly affect the assessments while inter-examiner findings suggest that experience and skill of the examiners as well as assessments that require drawing of lines and measuring of angles might lead to differences in the results obtained. Further studies which would utilise a large number of digitised radiographic images from both asymptomatic and symptomatic individuals are required to confirm the findings of this study.

LIST OF SYMBOLS AND ABBREVIATIONS

=:	Equals to
>:	Greater than
<	Less than
°:	Degrees
ABCS:	Alignment, Bone, Cartilage and Soft tissue
AF:	Annulus fibrosis
ALL:	Anterior longitudinal ligament
AP:	Antero-posterior
C1:	First cervical vertebra
C2:	Second cervical vertebra
C7:	Seventh cervical vertebra
CDC:	Chiropractic Day Clinic
CL:	Cervical lordosis
DISH:	Diffuse idiopathic skeletal hyperostosis
DUT:	Durban University of Technology
F:	Females
IVD:	Intervertebral disc
IVDs	Intervertebral discs
IVF:	Intervertebral foramina
K:	Kappa coefficient
km:	Kilometre
kVp:	Peak kilovoltage
<i>n</i>:	Sample size or count
N/A:	Not applicable or Not available
NP:	Nucleus pulposus
M:	Males

mm:	Millimetres
mAs:	Milliampere second
PLL:	Posterior longitudinal ligament
SD:	Standard deviation
SE:	Standard Error
SP:	Spinous process
SPSS:	Statistical Package for the Social Sciences
TVP:	Transverse process
TVPs:	Transverse processes
VB:	Vertebral body
vs:	Versus
yrs:	Years

LIST OF TABLES

CHAPTER TWO

Table 2.1	The major muscles of the cervical spine	8
Table 2.2	Factors that could influence the cervical lordosis	9
Table 2.3	Radiographic positioning, visible structures and alignment factors for the cervical spine	12
Table 2.4	A summary of the radiographic methods utilised to evaluate the cervical lordosis	14
Table 2.5	Factors which impact on intra- and inter-examiner reliability	21

CHAPTER THREE

Table 3.1	The modified Cobb methods for evaluating the cervical lordosis utilised in this study	27
------------------	---	----

CHAPTER FOUR

Table 4.1	The mean, standard deviation, standard error, minimum, maximum and range of the cervical lordosis using the C1-C7 modified Cobb method for each examiner over the two rounds	31
Table 4.2	The mean, standard deviation, standard error, minimum, maximum and range of the cervical lordosis using the C2-C7 modified Cobb method for each examiner over the two rounds	31
Table 4.3	The intra-examiner reliability of the radiographic assessment of the cervical lordosis using the C1-C7 modified Cobb method	33

Table 4.4	The intra-examiner reliability of the radiographic assessment of the cervical lordosis using the C2-C7 modified Cobb method	33
Table 4.5	The inter-examiner reliability of the radiographic assessment of the cervical lordosis using the C1-C7 modified Cobb method for Round 1	34
Table 4.6	The inter-examiner reliability of the radiographic assessment of the cervical lordosis using the C1-C7 modified Cobb method for Round 2	35
Table 4.7	The inter-examiner reliability of the radiographic assessment of the cervical lordosis using the C2-C7 modified Cobb method for Round 1	35
Table 4.8	The inter-examiner reliability of the radiographic assessment of the cervical lordosis using the C2-C7 modified Cobb method for Round 2	35

CHAPTER SIX

Table 6.1	Guidelines to improve the reliability of radiographic assessments	46
------------------	---	----

LIST OF FIGURES

CHAPTER FIVE

- Figure 5.1** Examples of the variations in the position of the lines drawn during the assessment of the cervical lordosis using the modified Cobb methods 41

LIST OF APPENDICES

Appendix A: Ethics Clearance Certificate

Appendix B: Permission by the Head of the Chiropractic Programme for the use of the radiographs and portable radiographic viewing box

Appendix C: Letter of Information and Consent*

* The participants wished to remain anonymous and, therefore, their names and signatures do not appear on **Appendix C**. However, each participant did sign this form before commencing participation in this study which is in the possession of the researcher (kept in the research file)

LIST OF DEFINITIONS

Asymptomatic	The absence of pain or symptoms (Dorland and Newman, 2007).
Clinical practice	The means of delivering health care by doctors, nurses and other health professionals (Segen, 2012).
Clinical setting	Pertaining to a clinic or to a bedside for actual observation and/or treatment of patients (Segen, 2012).
Confidence interval	The range of values within which statisticians are 95% confident that the results can be generalised to the population (Petrie and Sabin, 2009).
Cohen's Kappa	Cohen's Kappa measures the agreements between two examiners. A Kappa of <0.0 is regarded as a poor agreement, 0.00-0.20 slight, 0.21-0.40 fair, 0.41-0.60 moderate, 0.61-0.80 substantial and more than 0.80 almost perfect agreement (Landis and Koch, 1997).
Cervical lordosis	The angle formed by curvature of the cervical spine (Yochum and Rowe, 2005).
Cervical spine	The seven vertebrae (C1-C7) which connect the skull and the thoracic spine (Moore and Dalley, 2006).
Plain film radiograph	Plain film x-ray records of the internal structures of the body (Dorland and Newman, 2007).
Reliability	Yielding the same results in different clinical assessments (Segen, 2012).
Repeatability	The ability of an observer to achieve the same outcome when the measurements are repeated under the same circumstances (Petrie and Sabin, 2009).

TABLE OF CONTENTS

DEDICATION	i
ACKNOWLEDGEMENTS	ii
ABSTRACT	iii
LIST OF SYMBOLS AND ABBREVIATIONS	v
LIST OF TABLES	vii
LIST OF FIGURES	ix
LIST OF APPENDICES	x
LIST OF DEFINITIONS	xi
CHAPTER ONE.....	1
1.1 INTRODUCTION TO THE STUDY	1
1.2 AIM AND OBJECTIVES OF THE STUDY	3
1.3 HYPOTHESIS OF THE STUDY	3
1.4 SCOPE OF THE STUDY	3
CHAPTER TWO.....	4
2.1 INTRODUCTION	4
2.2 AN OVERVIEW OF THE RELEVANT BONY ANATOMY AND SOFT TISSUE ANATOMY OF THE CERVICAL SPINE	4
2.2.1 Atypical Cervical Vertebrae	4

2.2.2	Typical Cervical Vertebrae	5
2.2.3	The Ligaments of the Cervical Spine	6
2.3	THE MUSCLES OF THE CERVICAL SPINE	7
2.4	THE CURVATURE OF THE VERTEBRAL COLUMN	8
2.4.1	The Cervical Lordosis	9
2.4.2	Factors that Could Influence the Cervical Lordosis	9
2.5	RADIOGRAPHIC EVALUATION OF THE CERVICAL SPINE	11
2.5.1	The Role and Approach to the Evaluation of Plain Film Radiographs of the Cervical Spine in Clinical Practice	11
2.5.2	The Importance of Radiographs in Chiropractic	13
2.6	THE RADIOGRAPHIC ASSESSMENT OF THE CERVICAL LORDOSIS	13
2.7	THE CONCEPTS OF INTRA- AND INTER-EXAMINER RELIABILITY	18
2.8	STUDIES ON INTRA- AND INTER-EXAMINER RELIABILITY OF RADIOGRAPH INTERPRETATION	19
2.9	FACTORS AFFECTING THE INTRA- AND INTER-EXAMINER RELIABILITY OF RADIOGRAPH EXAMINATION	21
2.10	MISINTERPRETATION AND ERRORS IN RADIOGRAPH REPORTING	23
2.11	CONCLUSION	24
	CHAPTER THREE.....	25
3.1	STUDY DESIGN	25
3.2	POPULATION AND SAMPLE SIZE	25

3.3 SAMPLING METHOD	25
3.4 INCLUSION AND EXCLUSION CRITERIA	25
3.4.1 Inclusion Criteria	25
3.4.2 Exclusion Criteria	26
3.5 PERMISSION FOR OBTAINING THE RADIOGRAPHS	26
3.6 INSTRUMENTS	26
3.7 THE SELECTION OF THE EXAMINERS	26
3.8 THE RADIOGRAPHIC ASSESSMENT OF THE CERVICAL LORDOSIS	27
3.9 RESEARCH PROCEDURE	27
3.10 STATISTICAL ANALYSIS	28
3.11 ETHICAL CONSIDERATION	29
CHAPTER FOUR.....	30
4.1 THE SOURCE OF THE PLAIN FILM RADIOGRAPHS	30
4.2 THE MAGNITUDE OF THE CERVICAL LORDOSIS	30
4.3 THE INTRA-EXAMINER RELIABILITY OF THE RADIOGRAPHIC ASSESSMENT OF THE CERVICAL LORDOSIS USING THE MODIFIED COBB METHODS	32
4.4 THE INTER- EXAMINER RELIABILITY OF THE RADIOGRAPHIC ASSESSMENT OF THE CERVICAL LORDOSIS USING THE MODIFIED COBB METHODS	33
CHAPTER FIVE.....	36
5.1 EXPLANATION FOR THE MISSING ASSESSMENTS OF THE CERVICAL LORDOSIS	36

5.2 THE MAGNITUDE OF THE CERVICAL LORDOSIS	36
5.2.1 The C1-C7 Modified Cobb Method	36
5.2.2 The C2-C7 Modified Cobb Method	37
5.3 THE INTRA- AND INTER-EXAMINER RELIABILITY OF THE ASSESSMENT OF CERVICAL LORDOSIS	37
5.4 THE RELEVANCE OF THE FINDINGS OF THE STUDY	42
5.5 LIMITATIONS OF THE STUDY	42
CHAPTER SIX.....	44
6.1 CONCLUSION	44
6.2 GUIDELINES TO IMPROVE INTRA- AND INTER-EXAMINER RELIABILITY OF RADIOGRAPHIC INTERPRETATION	46
6.3 RECOMMENDATIONS	47
REFERENCES.....	48
APPENDICES.....	56

CHAPTER ONE

INTRODUCTION

1.1 INTRODUCTION TO THE STUDY

Plain film or digitised radiographic images are the primary diagnostic modalities of choice in medical and chiropractic clinical practice (Ory, 2003) because they are relatively inexpensive, readily available and allow for sufficient visualization especially of the bony anatomy (Yochum and Rowe, 2005). The use of radiographs from asymptomatic individuals allows for the development of normative reference values. These values assist clinicians to diagnose pathological conditions, to evaluate abnormal biomechanical changes to the skeletal system, and to determine the response to treatment (Roopnarian, 2011). Patients often present to the chiropractor for cervical spine-related complaints (e.g. neck pain). Radiographs of the cervical spine may be ordered by the clinician to evaluate any abnormalities, to confirm a diagnosis or to guide the management protocol (Yochum and Rowe, 2005; McAviney et al., 2005). A cervical spine radiograph can be evaluated by using the ABCS (Alignment, Bone, Cartilage and Soft Tissue) method described by Yochum and Rowe (2005). This approach enables the clinician to conduct a thorough examination of the radiograph as it assists in assessing the bony structures of the body, as well as the structural alignment and abnormalities (Yochum and Rowe, 2005; Fast and Goldsher, 2007). During a cervical spine radiographic assessment, one important radiographic parameter that is normally assessed is the cervical lordosis (CL).

The CL is defined as the angle formed by curvature of the cervical spine (Yochum and Rowe, 2005). It can be evaluated using non-radiographic methods and on a lateral view of a cervical spine radiograph using various approaches described previously (Wilson, 2012). The purpose of the CL is to respond to axial compression forces as well as to maintain the centre of gravity of the head over the spine (Moore and Dalley, 2006). Any change to the CL caused by direct trauma, degeneration or poor posture allows for deterioration of the important biomechanical functions which include weight distribution, structural support, energy transfer and shock absorption (Yochum and Rowe, 2005).

The maintenance of the normal CL is important for determining treatment outcomes, prevention of the development of chronic neck pain and degeneration of the cervical spine (McAviney et al., 2005). There are various radiographic methods of assessment of the CL. These, together with

the differences in the interpretation of the exact anatomical landmarks, contribute to the considerable variation in reported values (Hardacker et al., 1997; Harrison et al., 2000). These radiographic assessments, whether conducted pre-operatively or post-operatively, may influence the resultant cervical spine biomechanics (Ohara et al., 2006). The Cobb method, which was initially developed to assess spinal deformities in the coronal plane, was modified to assess the lordosis in the cervical spine through the use of angles utilising the vertebral endplate lines. The most common method for measuring the CL is the modified Cobb method developed by Harrison et al. (2000) due to its repeated high reliability and reproducibility (Vrtovec et al., 2009). Although there is a considerable responsibility on chiropractors (or any other clinician) to correctly interpret radiographs, often they have no system of confirming their radiographic diagnosis. Misunderstandings in the interpretation of the radiographic report or findings between practitioners may also occur (Berlin, 2000; Brealey et al., 2005).

The reliability of an examination is an important concept in the assessment of competence in medical and allied health practice, predominantly when assessments are conducted by multiple examiners (Rubinstein and van Tulder, 2008). The reliability of an examination must include acceptable intra- and inter-examiner reliability. This means the findings must be the same or close to those of the original assessment by the same examiner on subsequent assessments (i.e. intra-examiner reliability) and to the findings of other examiners (i.e. inter-examiner reliability) (Lindell et al., 2007). Previous studies have reported on the reliability of radiographic assessments in the lumbosacral and other regions by chiropractors compared to radiologists and radiographers (Philips et al., 1986; Coste et al., 1991; Taylor et al., 1995; Assendelft et al., 1997; Espeland et al., 1998; de Zoete et al., 2002). The findings showed that the most recognized reasons for variation and unreliability in radiographic assessment included limitations of assessment technique, misleading or incomplete clinical data, incomplete scanning of the radiograph, misinterpretation of perceived findings, lack of knowledge and errors in judgment, as well as variations in anatomical structure (Robinson, 1997; Resnick and Taylor, 2000; Fitzgerald, 2001; Tins and Cassar-Pullicino, 2004; Yochum and Rowe, 2005; Bono et al., 2010). Robinson (1997) found that interpretations which varied between the examiners were regarded as errors. Moreover, the findings of examiners who did not achieve significant agreement and whose results varied were considered as examiner variation. A recommendation for reducing these variations included attention to viewing conditions, training of the examiners, availability of previous films and relevant clinical history and the method of assessment (Robinson, 1997). If there are considerable differences in intra- and inter-examiner reliability in the assessment and

reporting of values of the CL, this may have an impact on both treatment and prognostic outcomes.

1.2 AIM AND OBJECTIVES OF THE STUDY

The aim of the study was:

To determine the intra- and inter-examiner reliability of the plain film radiographic assessment of the CL of asymptomatic* adult males.

Specific objectives were identified and these included:

1.2.1 To determine the intra-examiner reliability of the radiographic film assessment of the cervical lordosis using the C1-C7 and C2-C7 modified Cobb methods.

1.2.2 To determine the inter-examiner reliability of the radiographic film assessment of the cervical lordosis using the C1-C7 and C2-C7 modified Cobb methods.

* The absence of pain or symptoms (Dorland and Newman, 2007)

1.3 HYPOTHESIS OF THE STUDY

The Alternate Hypothesis (H_a) was set which stated that there would be a significant difference in the intra- and inter-examiner reliability of the CL of asymptomatic adult males.

1.4 SCOPE OF THE STUDY

Eighty lateral plain film radiographs of the cervical spine of asymptomatic males (which were taken in a previous study) aged between 18-45 years were utilised for this study. The CL was assessed by three examiners using the C1-C7 and C2-C7 modified Cobb methods described previously (Harrison et al., 2000). The CL values, mean, standard deviation, standard error, minimum, maximum and range as well as the intra- and inter-examiner reliability of the CL for the three examiners for each of the two rounds are reported in this dissertation.

CHAPTER TWO

LITERATURE REVIEW

2.1 INTRODUCTION

In this chapter the literature on the CL with respect to the description, evaluation, radiographic assessment and clinical importance is presented. In addition, a concise overview of the anatomy and function of the cervical spine is described. The concepts of intra- and inter-examiner reliability and their relevance to radiographic assessment is also addressed.

2.2 AN OVERVIEW OF THE RELEVANT BONY AND SOFT TISSUE ANATOMY OF THE CERVICAL SPINE

The cervical spine is the connection between the head, trunk and limbs (Moore and Dalley, 2006). It connects the skull and the thoracic spine and is made up of seven vertebrae (C1-C7). The cervical spine consists of typical and atypical bony vertebrae, soft tissue structures such as muscles, ligaments, the intervertebral discs (IVDs), blood vessels (e.g. subclavian arteries and veins, internal and external jugular veins and the brachiocephalic trunk) and neural structures (e.g. spinal cord, vagus and phrenic nerves, and cervical portion of the sympathetic trunks). The cervical spine helps to protect the spinal cord and its nerves as well as supporting the weight of the head by assisting in its posture and movement (Moore and Dalley, 2006).

2.2.1 Atypical Cervical Vertebrae

a) The Atlas (C1)

The atlas is the first cervical vertebra (C1) and it supports the head (Standring, 2005). It is annular-shaped, lacks a vertebral body (VB) and a spinous process (SP); instead it consists of two lateral masses connected by a short anterior and a longer posterior arch (Standring, 2005; Moore and Dalley, 2006). The anterior arch is convex anteriorly and forms the anterior tubercle which is the site for the attachment of the anterior longitudinal ligament (ALL). The posterior surface of the anterior arch provides a facet for the odontoid process of the axis. The union between the head and atlas through the atlanto-occipital joints is strong, and allows only for

flexion, extension and lateral movements of the head (Collins et al., 2005). The head and the atlas move and function effectively as one component (Bogduk and Mercer, 2000).

b) The Axis (C2)

The axis serves as a pivot for the rotation of the atlas and the head around the odontoid process which projects superiorly from the VB of C2. The odontoid process is approximately 15mm in length and usually tilts no more than five degrees (Yochum and Rowe, 2005). The axis is also the site of attachment of the ALL on its anterior VB border and for the posterior longitudinal ligament (PLL) on its posterior VB border (Standring, 2005). The superior articular processes of the axis are convex to receive the lateral masses of the atlas (Yochum and Rowe, 2005). The vertebral arch is posterior to the VB and its structure is attributed to the union of the left and right pedicles and laminae of the relevant vertebral segment. The pedicles are identified as small and stout processes which project posteriorly to connect the vertebral arch to the VB.

2.2.2 Typical Cervical Vertebrae

Typical cervical vertebrae (C3-C7) consist of a small VB, a short bifid SP, the pedicles, laminae, transverse processes (TVPs) and the superior and inferior articular processes (Moore and Dalley, 2006). The VB is small and wider transversely than antero-posteriorly; it is concave superiorly and convex inferiorly while the superior borders are raised to form the uncinat processes (Moore and Dalley, 2006). The SP of the typical vertebra is usually short from C3 to C5, but at C6 and C7 it is longer and bifid with two tubercles (Moore and Dalley, 2006). The TVPs contain a foramen for the vertebral vessels to pass through and they terminate laterally as the anterior and posterior tubercles (Standring, 2005; Moore and Dalley, 2006). The pedicles are found in the centre between the distal surfaces of the VB which is directed posterolaterally. The pedicles connect to the superior and inferior articular processes which are directed supero-posteriorly and infero-posteriorly, respectively (Standring, 2005; Moore and Dalley, 2006). The laminae, which arise from the articular processes, are directed postero-medially and form a triangular-shaped vertebral foramen. The vertebral foramen is enclosed by the VB anteriorly, the spinous process and laminae posteriorly and the pedicles laterally (Moore and Dalley, 2006).

a) Facet Joints

The joints that form the vertebral arch are called facet joints or zygapophyseal joints. These are located between the superior and inferior articular processes of adjacent vertebrae. The superior articular facets are angled in a superior direction and the inferior articular facets are angled in an inferior direction. The direction of the facet joints in the cervical spine helps to limit the movements of lateral flexion and rotation which contributes to the stability of the cervical spine (Moore and Dalley, 2006).

b) Intervertebral Discs

The IVDs are found between adjacent surfaces of the vertebral bodies (VBs) and serve as a connection between the articulating surfaces of the endplates from the sacrum to the axis. There is no IVD between the atlas and axis (Collins et al., 2005; Moore and Dalley, 2006). The IVDs constitute a third of the vertebral column height and form part of the anterior border of the intervertebral foramen (IVF). The components of the IVD include the fibrous annulus fibrosis (AF), the gelatinous nucleus pulposus (NP) and a cartilaginous endplate (Moore and Dalley, 2006). The IVDs are relatively thick in the cervical spine compared to the thoracic spine and are typically thickest at the level of C6-C7. The anterior thickness contributes to the formation of the CL (Moore and Dalley, 2006).

c) Intervertebral Foramina

These short tunnel-like structures, also known as the lateral or nerve root canals, enclose and transmit the lateral termination of the anterior and posterior nerve roots. The IVF is bounded anteriorly by the IVD and adjacent VBs, posteriorly by the facet joints and inferiorly by the pedicles (Middleditch and Oliver, 2005; Moore and Dalley, 2006).

2.2.3 The Ligaments of the Cervical Spine

a) Anterior Longitudinal Ligament

The ALL extends from the antero-lateral aspects of the sacrum to the anterior tubercle of C1 and the anterior aspect of the foramen magnum (Standring, 2005). The ligament is made up of strong fibrous bands which cover the VBs and IVDs. The ligament tends to be thicker in the

cervical and lumbar regions of the spine (Moore and Dalley, 2006; Standring, 2008). It helps maintain stability between the VB and IVD joint (Middleditch and Oliver, 2005) and prevents hyperextension of the vertebral column to some extent (Moore and Dalley, 2006).

b) Posterior Longitudinal Ligament

The posterior longitudinal ligament (PLL) lies in the vertebral canal. It prevents hyperflexion of the vertebral column by attaching to the posterior surfaces of the VBs. It is a component of the anterior wall of the spinal canal as it is attached firmly to the IVD and loosely to the VB. The PLL helps prevent herniation of the IVD posteriorly (Middleditch and Oliver, 2005; Moore and Dalley, 2006).

c) Ligamentum Flavum

The paired ligamentum flava are strong elastic ligaments which are long, thin and wide in the cervical spine, thicker in the thoracic region and thickest in the lumbar region (Standring, 2005; Moore and Dalley, 2006). The ligament extends between the inferior aspects of the posterior arch of the atlas to the lamina of the axis below (Moore and Dalley, 2006). It lengthens laterally to the facet joint and enters the fibrous composition of the joint. It helps support the neck and preserves the normal curvatures of the vertebral column and assists the muscles to extend a flexed neck. It also assists in the restoration of the body to an erect posture after flexion which protects the IVDs from possible injury. This is attained by breaking the movement produced in neck hyperflexion and also by preventing the end range of motion to be reached rapidly (Middleditch and Oliver, 2005; Moore and Dalley, 2006).

2.3 THE MUSCLES OF THE CERVICAL SPINE

The primary muscles producing movement of the cervical spine are shown in **Table 2.1**.

Table 2.1 The major muscles of the cervical spine

Flexor muscles	Extensor muscles	Rotation and lateral flexion muscles
Sternocleidomastoid	Splenius capitis	Sternocleidomastoid
Longus colli	Splenius cervicis	Scalene group
Longus capitis	Semispinalis capitis	Splenius capitis
Rectus capitis anterior	Longissimus capitis	Splenius cervicis
Sternocleidomastoid	Longissimus cervicis	Longissimus capitis
	Trapezius	Levator scapulae
	Interspinalis	Longus colli
	Rectus capitis posterior major	Illiocostalis cervicis
	Rectus capitis posterior minor	Multifidi
	Obliquus capitis superior	Intertransversarii
		Obliquus capitis inferior
		Obliquus capitis superior
		Rectus capitis lateralis

Adapted from Naicker (2012)

The muscles of the cervical spine are responsible for providing the support and stability needed to move the head and neck. This occurs by the interaction between muscle groups and the ligaments of the cervical spine (Moore and Dalley, 2006). The short muscles of the neck (longus colli, the anterior, middle and posterior scalenes) and the sternocleidomastoid are responsible for flexion and lateral flexion of the cervical spine (Standring, 2005; Moore and Dalley, 2006). The muscle group responsible for extension of the cervical region assists in the upright posture of the head (Standring, 2005; Moore and Dalley, 2006). These muscles, acting together, support the head and neck in the upright position, steady the skull against the effects of gravity, allow for movement and assist in range of motion (Jackson and McManus, 1994; Berthonnaud et al., 2005; Roussouly et al., 2005).

2.4 THE CURVATURE OF THE VERTEBRAL COLUMN

The vertebral column has four distinct curves when viewed from the lateral aspect; these are further divided into primary and secondary curves (Moore and Dalley, 2006). The primary curves are the thoracic and sacral curves, which are concave anteriorly while the cervical and lumbar curves are the secondary curves and are concave posteriorly (Moore and Dalley, 2006). The curvature of the cervical spine is primarily due to the biconvex shape of the IVD which is thinner posteriorly than anteriorly (Nordin and Frankel, 2001; Moore and Dalley, 2006). This allows for greater weight distribution, structural support, energy efficiency and shock absorption. The loss of a normal CL will result in a decreased range of motion and greater biomechanical changes to the cervical spine (Wilson, 2012).

2.4.1 The Cervical Lordosis

The CL is defined as the angle formed by curvature of the cervical spine (Yochum and Rowe, 2005). It can be evaluated using non-radiographic methods and on a lateral view of a cervical spine radiograph using various approaches described previously (Wilson, 2012). The cervical curve arises at the atlas and terminates at T2, with the apex between C4 and C5. During the fetal stage, the thoracic and sacral curvatures begin to develop. Within the first few months of life, as infants develop strength to hold their head upright, the cervical curve will form (Bagnall et al., 1977; Moore and Dalley, 2006). The purpose of the CL is to respond to axial compression forces as well as to maintain the centre of gravity of the head over the spine (Moore and Dalley, 2006). The CL is significant as a change in the curve due to degeneration, muscle spasm or trauma may lead to the development of clinical symptoms (Yochum and Rowe, 2005). The radiographic methods of assessment of the CL are described in **Table 2.4** and discussed thereafter.

2.4.2 Factors that Could Influence the Cervical Lordosis

Previous reports on the CL have described the factors that relate to changes in the CL (Standring, 2005; Grob et al., 2007; Roopnarian, 2011; Naicker, 2012; Wilson, 2012; **Table 2.2**). These include instability, muscle spasm, soft tissue injury, degenerative changes, tumours, trauma and differences in radiographic positioning. These factors could possibly be responsible for a hyper- and hypolordotic cervical curve (Peterson et al., 1999). A hyperlordotic curve is defined as an anterior curve greater than 45° and a hypolordotic curve as an anterior curve less than 16° (Yochum and Rowe, 2005).

Table 2.2 Factors that could influence the cervical lordosis

Alignment	Bone	Cartilage	Soft Tissue
Spondylolisthesis	Osteoarthritis	Joint space narrowing	Tumours
Increased thoracic kyphosis	Rheumatoid arthritis	IVD space narrowing	Surgery
Scoliosis	Ankylosing spondylitis		Trauma
Poor posture	DISH		
Obesity			
Increasing age			

Data summarised from Standring (2005); Grob et al. (2007); Roopnarian (2011); Naicker (2012); Wilson (2012)
DISH = Diffuse idiopathic skeletal hyperostosis; IVD = Intervertebral disc

Cervical posture is best assessed with the patient in an erect position. The lordosis allows for the forces acting on the VB both anteriorly and posteriorly to be minimal. It assists in determining the

position of the cervical structures as they change when supporting the head against gravity. Poor cervical posture is described as any point from which the head rests anterior to its anatomical points of reference (Kendall and McCreary, 1993). The change in head position contributes to inefficiency of the CL and can result in pain and joint dysfunction (Yochum and Rowe, 2005). Spondylolisthesis may cause a change in the CL due to irregular distribution of forces on the anterior cervical VB resulting from an enlargement of the articular processes (Harrison et al., 2000; Yochum and Rowe, 2005). The CL is increased in the presence of an increased thoracic kyphosis as it causes a forward gaze head posture (Boyle et al., 2002). Scoliosis may result in a loss of curvature in the spine since it causes lateral deviation and excessive rotation of the spine along the vertical axis (Anderson, 2007). The relationship between obesity and degeneration of the cervical spine was evaluated by Witsek and Benzel (2014). The results showed that obese patients had an increase in degeneration and a decrease in the biomechanical function of the cervical spine.

Osteoarthritic (i.e. degenerative) changes commonly involve the facet joints, endplates and IVDs which contribute to a change in the CL (Grob et al., 2007). The most common area for degenerative change is the lower cervical spine (Yochum and Rowe, 2005). Facet hypertrophy, thinning of the endplates and narrowing of the IVDs are known to change the curvature of the cervical spine as a result of degeneration. Facet joint and IVD space narrowing is indicative of degeneration in the spine which is of concern as these joints are weight bearing joints (Yochum and Rowe, 2005). Visible signs on a radiograph that point towards IVD degeneration are loss of IVD height, the presence of osteophytes and endplate sclerosis (Yochum and Rowe, 2005). The most common site for IVD space narrowing is at the apex (C5) of the cervical curve. This leads to decreased mobility in the cervical spine and is most noticeable in individuals over 50 years of age (Gore et al., 1986; Stupar et al., 2003; Yochum and Rowe, 2005).

A study conducted over a ten-year period found that in asymptomatic patients, there is a gradual increase in the CL with age (Gore et al., 1986). An appreciable increase in the CL was noted in patients between the ages of 50 to 70 years of age (Marchiori and Henderson, 1996; Okada et al., 2009; Yukawa et al., 2012). On the other hand, studies have reported that a decrease in or the development of a kyphotic cervical curve has been related to changes in biomechanical function (Braaf and Rosner, 1975; Vernon et al., 1992; Nagasawa et al., 1993). A change in the CL is also observed in patients with systemic inflammatory arthritis (e.g. rheumatoid arthritis and ankylosing spondylitis) (Collins et al., 2005; Yochum and Rowe, 2005). Diffuse idiopathic skeletal hyperostosis (DISH) is a generalised articular disorder which affects both spinal and

extra-spinal structures. It is associated with ligamentous calcification and ossification, mainly of the ALL, and eventually results in a decrease of the CL (Yochum and Rowe, 2005). These degenerative changes to the spine cause a decrease in the angle of the anterior or posterior vertebral column, which results in a change in the lordotic curvature of the cervical spine (Grob et al., 2007).

Destruction of the vertebrae, IVDs and surrounding soft tissue by tumours, infections or surgery of the cervical spine are also known to affect the CL. This results in mechanical instability of the cervical spine (Collins et al., 2005). Traumatic conditions such as whiplash may result in muscle spasm, which reduces the curvature of the cervical spine (Fice and Cronin, 2012). Following a whiplash injury, the cervical muscles contract rapidly in response to the impact and the potential for muscle injury due to lengthening contractions of the muscle increases (Brault et al., 2000). When a muscle is not functioning optimally it will result in compensatory changes in its functional partners. This will result in a reduction in the CL caused by the hypertonic flexor muscles which can be seen on a cervical spine lateral radiograph (Fice and Cronin, 2012).

2.5 RADIOGRAPHIC EVALUATION OF THE CERVICAL SPINE

2.5.1 The Role and Approach to the Evaluation of Plain Film Radiographs of the Cervical Spine in Clinical Practice

Plain film or digitised radiographic images are the primary diagnostic modalities of choice in medical and chiropractic clinical practice (Ory, 2003) because they are relatively inexpensive, readily available and allow for sufficient visualization especially of the bony anatomy (Yochum and Rowe, 2005). The reasons for this include relatively low costs, easy availability and sufficient visualization of the bony anatomy. A cervical spine radiograph can be evaluated by using the ABCS (Alignment, Bone, Cartilage and Soft Tissue) method popularised by Yochum and Rowe (2005). This simple and effective method of assessment enables one to conduct a thorough examination of the radiograph as it covers all the alignment parameters, as well as the bony and soft tissue structures (Yochum and Rowe, 2005; Fast and Goldsher, 2007). The standard radiographic views for the assessment, positioning and alignment of the cervical spine are tabulated in **Table 2.3**.

Table 2.3 Radiographic positioning, visible structures and alignment factors for the cervical spine

View	Patient Positioning	Visible Structures	Alignment Factors
AP	Erect or supine	Uncovertebral joints Facet joints IPD Pedicles Spinous process Vertebral body	The spinous processes and laterolisthesis should be assessed. A normal coupled rotation with lateral flexion and scoliosis is noticeable by the spinous process deviating in a uniform, progressive manner to the convexity. An intersegmental rotation between spinous processes or an increase in interspinous space may be an indicator of facet subluxation or dislocation.
AP open-mouth	Erect or supine	Skull Odontoid process Atlas and Axis complex Lateral masses of the atlas Atlantoaxial joint	The atlas lateral mass should not extend beyond the lateral margin of the axis by more than 2mm. The lateral atlantodental interspaces should be equal and the width of the atlas lateral masses should be equal. No more than 5° of tilt should be seen in the dens.
Lateral	Erect lateral; standing or sitting	Skull IVD Odontoid process Atlas and axis complex Facet joints	There are 4 visual lines of alignment that should be assessed: The anterior and posterior VBs, spinolaminar lines and the tips of the spinous processes. The shape of the cervical lordosis and the atlantodental interspace should also be assessed and measured.
Oblique	Erect or recumbent	Uncovertebral joints IVD IVF Facet joints	Alignment of the laminae should be vertical. The opposing facet surfaces should be parallel and overlapping.

Data summarised from Yochum and Rowe (2005)

AP = Antero-posterior; IPD = Interpedicular distance; IVD = Intervertebral disc; IVF= Intervertebral foramen; VBs = Vertebral bodies

Plain film radiographs are commonly utilised in clinical practice to detect degenerative joint disease, bony metastases and trauma to the cervical spine (Rybak and Rosenthal, 2001; Wiegand et al., 2003; Pouletaut et al., 2010). The antero-posterior (AP) view of the lower cervical spine is useful for evaluating traumatic, arthritic, neoplastic conditions and congenital anomalies. The AP open-mouth view is vital for assessing fractures and congenital anomalies of the upper two cervical vertebrae in particular the odontoid process (Yochum and Rowe, 2005). The evaluation of fractures, dislocations, IVD space integrity and stenosis can be done on the lateral views (Lim and Wong, 2004; Yochum and Rowe, 2005). When assessing alignment on

the lateral view, the examiner attempts to visualise four contour lines viz. the anterior and posterior VB lines, the spinolaminar line and the tips of the SP. These assist the clinician in defining the bony margins of the spinal canal and misalignment which can lead to impingement on the spinal cord (Yochum and Rowe, 2005). The CL is also evaluated on the lateral view. This is discussed in **Section 2.6**. The cervical oblique views are used to assess any narrowing or widening of the IVF (Yochum and Rowe, 2005).

2.5.2 The Importance of Radiographs in Chiropractic

Chiropractors utilise radiographs to determine the presence or absence of pathology and to analyse structure, posture and biomechanics of the spinal column (Peterson and Bergmann, 2002; Gatterman, 2003). Previous authors have reported that radiographs are also utilised by chiropractors for assessing contraindication to spinal manipulation and for medico-legal protection (Philips, 1992; Gatterman, 2003). They further report that financial gain or routine spinal screening are other possible reasons for ordering radiographs even though radiographs should not be for general screening without a specific clinical indication. It has even been argued that even if possible contraindications are seen on the radiograph, there is not always conformity on what these are and to what degree they can be viewed as a contraindications (Taylor et al., 1995). This discrepancy is primarily due to radiograph misinterpretation or misunderstandings between those reporting and those receiving reports (Robinson, 1997; Berlin, 2000).

2.6 THE RADIOGRAPHIC ASSESSMENT OF THE CERVICAL LORDOSIS

The lack of a standardised method for determining the CL has resulted in several reported normative reference means and ranges. There is also insufficient information with regards to the validity of each technique (Peterson et al., 1999; Ohara et al., 2006). A summary of the radiographic methods that have been evaluated are shown in **Table 2.4**.

Table 2.4 A summary of the radiographic methods utilised to evaluate the cervical lordosis

Reference	Sample	Method	Reported value of CL [#]
Borden et al. (1960)	180 asymptomatic M and F (90 each) between 21-80 yrs.	Depth of the cervical curve: A line (A) drawn from the superior posterior aspect of the odontoid process to the posterior inferior aspect of the VB of C7. Another line (B) drawn along the posterior aspect of the intervening cervical VB. A third line (C) intersects perpendicularly at the point of the longest distance between A and B. The length of C is the depth of CL.	Mean (F): 12.16 mm Mean (M): 11.56 mm
Drexler (1962)	N/A	Drexler's method*	Mean: 40°
Jochumsen (1969)	N/A	Method of Jochumsen:* A line is drawn from the anterior border of the atlas anterior tubercle to the anterosuperior corner of C7 VB. The distance from this line to the anterior border of the C5 vertebral body is measured (Yochum and Rowe, 2005).	Range: 3-8mm
Gore et al. (1986)	100 M and 100 F (all asymptomatic) between 20 - 65 yrs.	Method of Gore: The CL is measured by the angle created by lines parallel to the posterior surface of the VB of C2 and the VB of C7.	Mean: 23°
Owens and Hoiris (1990)	N/A	Posterior tangent method: Tangents are drawn on the posterior VB margins of C2 to C7. Segmental angles (relative rotation angles) are formed at each pair of adjacent tangents, and a global angle of the curvature is measured between the tangents on C2 and C7.	Mean: 22.3°
Harrison et al. (1996)	400 randomly selected lateral C-spine radiographs of subjects with some form of micro	Geometric model of the static sagittal cervical spine: Lines were constructed along the posterior vertebral body margins of C2-C7, the cervical	Mean ± SD: 34° ± 9° Range: 16.5°-66°

	or macro trauma. 237 M and 163 F with an average age of 35.4 yrs. A subgroup of 252 subjects who did not have cervico-cranial symptomatology was determined.	lordosis was measured as an angle between Jackson's physiologic lines at the posterior margins of C2 and C7.	
Hardacker et al. (1997)	100 asymptomatic adults in the erect posture.	Modified Cobb method (C0-C7): A line is drawn along the foramen magnum and another line is drawn through and parallel to the inferior endplate of C7. Perpendiculars are drawn to the point of intersection and the resultant angle is recorded.	Mean ± SD: 40° ± 9.7°
Harrison et al. (2000)	30 lateral radiographs were selected from clinical files and digitized twice by each of the 3 examiners.	Modified Cobb method (C1-C7): A line is drawn through and parallel to the inferior endplate of C7 and another is drawn through the midpoints of the anterior and posterior tubercles of the atlas. Perpendiculars are drawn to the point of intersection and the resultant angle is measured.	Mean: 53.6°
		Modified Cobb method (C2-C7): A line is drawn through and parallel to the inferior endplate of C7 and another is drawn through and parallel to the inferior endplate of C2, perpendiculars are drawn to the point of intersection and the resultant angle is recorded.	Mean: 17.2°
		Posterior tangent method	Mean: 25.8°
McAviney et al. (2005)	Retrospective study of 277 randomly selected lateral cervical radiographs of both symptomatic and asymptomatic patients between the ages of 9 -78 yrs.	Posterior tangent method	Symptomatic group: mean: 9.6° Asymptomatic group: mean: 23.4°

Roopnarian (2011)	80 healthy, asymptomatic M from 4 different ethnic groups between the ages of 18-45 yrs.	Modified Cobb method (C1-C7)	Mean \pm SD: 45.7 $^{\circ}$ \pm 10.2 $^{\circ}$
		Modified Cobb method (C2-C7)	Mean \pm SD: 15.9 $^{\circ}$ \pm 9.1 $^{\circ}$
Naicker (2012)	80 apparently healthy F from 4 different ethnic groups between the ages of 18-45 yrs.	Modified Cobb method (C1-C7)	Mean \pm SD: 38.9 $^{\circ}$ \pm 11.5 $^{\circ}$
		Modified Cobb method (C2-C7)	Mean \pm SD: 11.3 $^{\circ}$ \pm 7.8 $^{\circ}$

Table adapted from Naicker (2012)

M = Males; F = Females; C = Cervical; CL = Cervical lordosis; VB = Vertebral body; SD = Standard deviation; N/A = Not Applicable; Yrs = Years

The values recorded are exactly as stated in the articles

* The researcher was unable to view the original references despite an extensive literature search

One of the first proposed assessment techniques, the depth of the cervical curve method, is useful yet uncommon. The results were unable to be transformed into angular measurements which made comparison between patients difficult (Borden et al., 1960). This resulted in this technique not gaining popularity. The Drexler method involved assessing each individual cervical segment with lines drawn along each endplate and measuring the resultant angle. The total sum of each segment was the value of the CL (Drexler, 1962; Yochum and Rowe, 2005). Although it is accurate when utilised correctly, it is, laborious which adds to human error (Borden et al., 1960; Yochum and Rowe, 2005; Wilson, 2012). The Jochumsen (1969) method is not well known and, therefore, limited literature is available.

The method proposed by Gore et al. (1986) is a simple technique when compared to the depth of the cervical curve. There was no discrepancy of the measurement of the angles with regards to magnification and patient size variation, the resultant mean value of the CL was similar to those in previous reports of asymptomatic individuals. When compared to other techniques to measure the CL, the method of Gore was uncommon among examiners (McAviney et al., 2005). The Harrison posterior tangent method has a smaller standard error of measurement, but the use of the many landmarks and lines drawn contributes to an increase in human error (Harrison et al., 2000). The modified Cobb method was first described by Hardacker et al. (1997) using the C0 (foramen magnum in the occiput) and C7 (inferior endplate) anatomical landmarks. This method was further modified and developed by Harrison et al. (2000) as described in **Table 2.4**.

When compared to the modified Cobb method, the posterior tangent method had a decrease standard error (SE) of measurement (Harrison et al., 2000). However, due to the laboriousness of the posterior tangent method, it is not often used in a clinical setting (Harrison et al., 2000). In the opinion of Cote et al. (1997), the most common method for measuring the CL was the modified Cobb method (C0-C7) due to its high reliability. There were, however, differences of opinion with regards to the correct bony landmarks to be used (Hardacker et al., 1997; Harrison et al., 2000). These differences revolved around the anatomical landmarks to be utilised and around the tilt and structure of the endplates; therefore, the angles constructed did not reflect the changes in the curvature of the cervical spine (Vrtovec et al., 2009). It has been reported that the C1-C7 Cobb method overvalued while the C2-C7 method undervalued the curve. The causes of this are thought to be the inferior endplates of the VB and the concave shape of the antero-inferior body of C2 (Harrison et al., 2000). Nevertheless, the C1-C7 and C2-C7 modified Cobb methods described by Harrison et al. (2000) have since gained popularity amongst health care practitioners (e.g. radiologists and chiropractors) over the C0-C7 modified method for evaluating the lordotic curve of the cervical spine (Naicker, 2012). Therefore, both these methods were utilised for the radiographic assessment of the CL in the present study.

Several studies did not specify whether the CL was determined from radiographic data belonging to symptomatic or asymptomatic individuals (Drexler, 1962; Jochumsen, 1969; Owens and Hoiris, 1990; Harrison et al. (2000) **(Table 2.4)**). The mean CL reported by Harrison et al. (1996) included the combined results of asymptomatic and symptomatic individuals. The results of Harrison et al. (2000), who utilised the same method of assessments of the CL as the present study, were obtained from records in clinical files. The proportion of asymptomatic versus symptomatic cases was not specified in the article and the sample size was also small ($n = 30$). The comparison of the mean CL between asymptomatic and symptomatic individuals was reported in only one study (McAviney et al., 2005). The authors reported that the mean CL was higher in asymptomatic than in symptomatic individuals **(Table 2.4)**. The various factors that could explain this result have been discussed in **Section 2.4.2**.

The differences in the conclusions reached on the value of CL in the various studies **(Table 2.4)** may possibly be due to the differences in the measurement techniques and anatomical landmarks chosen for each study. The inter-examiner reliability is questionable if examiners are utilising different methods (Peterson et al., 1999, Wilson, 2012). Therefore, in addition to the results obtained from the measurement of the CL, the method of assessment needs to be stated as this will have a direct result on the interpretation of the results between clinicians and, hence,

on the clinical intervention. The benefits of assessing the CL on a radiograph allow for a more accurate diagnosis and the correct treatment to be provided. Harrison et al. (2002) described a treatment intervention of both cervical manipulation and cervical spine traction in order to restore the CL. The study revealed that both treatment interventions resulted in a significant improvement in the CL of 13.6° which was assessed using the modified Cobb method (C2-C7).

2.7 THE CONCEPTS OF INTRA- AND INTER-EXAMINER RELIABILITY

The reliability of an examination is an important issue in the assessment of competence in medical and allied health practice, predominantly when assessments are conducted by multiple examiners (Rubinstein and van Tulder, 2008). Reliability includes the three concepts of repeatability, reproducibility and agreement (Petrie and Sabin, 2009). Repeatability focuses on the ability of an observer to achieve the same outcome when the measurements are repeated under the same circumstances. Reproducibility draws attention to observer agreement i.e. whether two or more examiners utilising the same method of measurement attain the same outcome, while agreement focuses on the outcome that is accepted by all participants in an assessment (Segen, 2012).

The reliability of an examination must include acceptable intra- and inter-examiner reliability. This means the measurement must be comparable to several other examiners and by the same examiner on numerous instances (Lindell et al., 2007). In order to statistically assess reliability, the Kappa coefficient (K), which is a measurement of agreement, needs to be determined. Cohen's Kappa measures the agreements between two examiners. A Kappa of <0.0 is regarded as a poor agreement, 0.00-0.20 slight, 0.21-0.40 fair, 0.41-0.60 moderate, 0.61-0.80 substantial and more than 0.80 almost perfect agreement (Landis and Koch, 1997).

There is a paucity of literature on the intra- and inter-examiner reliability of the radiographic assessment of the CL. This is important as there is a need for sufficient interpretation of techniques so as to not exclude subtle signs of pathology (Robinson, 1997; Espeland et al., 1998). This is of particular importance to a chiropractor, as manual therapy is a contraindication when a procedure will negatively impact a patient's health (Peterson and Bergmann, 2002; Gatterman, 2003; Marais, 2011).

2.8 STUDIES ON INTRA- AND INTER-EXAMINER RELIABILITY OF RADIOGRAPH INTER- PRETATION

It is important that clinical and radiographic practitioners are familiar with the principles involved in producing and evaluating diagnostic radiographic plain film or digital images. Radiographic images, whether plain film or digital, must be produced utilising the lowest possible radiation dose while still allowing for reliable diagnostic quality. Therefore, an understanding of the regulation of the exposure factors (kVp and mAs) affecting the image quality by the practitioner is essential to ensure the image corresponds to the diagnostic query (Holmes et al., 2013). The mAs determines the density of the radiographic image. If the mAs is increased, the image density is also increased. The kVp determines the beam quality and contrast of the image. The examiner will need to increase the kVp, as the thickness of an object increases (Yochum and Rowe, 2005). The exposure factors for the lateral cervical spine radiographs utilised in this study were 70kVp and 20mAs which are in keeping with those utilised by the Radiography Clinic at the Durban University of Technology (DUT) (Roopnarian, 2011).

Norgaard et al. (1990) assessed the variation in the assessment of pulmonary venous hypertension (PVH) in plain film chest radiographs. The study evaluated 171 radiographs obtained over a four-year period and utilised two residents in their second year of training and two clinically-experienced radiologists. The average level of agreement between the examiners was moderate ($K = 0.51$ and $K = 0.56$) which was considered unsatisfactory in the interpretation of PVH (Norgaard et al., 1990). It was concluded that the difference in agreement was not due to the variation in training or clinical skills but rather the method utilised (patients were either standing or sitting) to assess the radiographs (Norgaard et al., 1990).

Taylor et al. (1995) assessed the mean percentage of correctly-identified pathology in the lumbosacral region among 496 medical and chiropractic professionals and students with zero (students) to more than 30 years (clinicians) of experience in practice. The participants included 22 medical students, 183 chiropractic students, 27 medical radiology residents, 13 chiropractic radiology residents, 66 medical clinicians (12 general practice physicians, 25 orthopaedic surgeons, 21 orthopaedic residents, and eight rheumatologists), 46 chiropractic clinicians, 48 general medical radiologists, 55 chiropractic radiologists, and 36 skeletal radiologists and fellows. The study utilised 35mm slides rather than plain film radiographs for the study, which did not represent current practice in the clinical setting at the time. They found that the results of skeletal radiologists were significantly higher than other medical groups ($p < 0.05$). The results of

medical radiologists and medical residents were significantly higher than those of the medical clinicians. The results of medical students were significantly poorer than those of the other medical groups. Chiropractic radiologists and chiropractic radiology residents had significantly higher results than chiropractic clinicians and students. There was no significant difference in the mean values of the chiropractic clinicians and chiropractic students ($p > 0.05$). The results of the chiropractic radiologists, chiropractic radiology residents and chiropractic students were significantly higher than those of the general radiologists, medical radiologists and medical students. There was no significant difference in the results of chiropractic radiologists and skeletal radiologists or between chiropractors and clinicians. A limitation of this study was the use of mean percentage values to compare the reliability of participants rather than the Kappa coefficient utilised earlier by Norgaard et al. (1990) and later by Tudor et al. (1997), Stupar et al. (2003) and Bouliane et al. (2013). It was noted that even though all the examiners utilised the same equipment, it was not possible to recreate identical viewing conditions at each test site during the study.

Tudor et al. (1997) utilised five consultant radiologists and 50 plain film radiographs (chest, abdominal and musculoskeletal) viewed over five months apart to assess the inter-examiner agreement and accuracy of radiographic reporting. The inter-examiner variation in the interpretation of the radiographs ranged from fair ($K = 0.31$) to moderate ($K = 0.58$) for inter-examiner reliability. This result revealed disagreement of more than 20% among the examiners (Tudor et al., 1997). It was found that inter-examiner agreement was higher for radiographs with visible pathology than in those without pathology and the agreement among examiners was increased during Round 2 of the assessments (Tudor et al., 1997). The reason for the increase in inter-examiner agreement was due to the introduction of clinical history during Round 2 of the examination. Although the inter-examiner agreement had increased with clinical history, this did not always result in the correct diagnostic pathology being identified (Tudor et al., 1997). It was, therefore, concluded that sufficient clinical information needs to be available to increase the accuracy and reproducibility of radiographic examination (Tudor et al., 1997).

Stupar et al. (2003) utilised two inexperienced examiners (two fourth year chiropractic students) and 320 cervical spine plain film radiographs from patients ranging from 40-79 years of age, to determine the inter-examiner reliability of the diagnosis of cervical pillar hyperplasia. The radiographs had been of good radiographic quality (absence of artefacts, good collimation and appropriate mAs and kVp factors). The inter-examiner reliability for the assessment was

moderate ($K = 0.51$). They concluded that the radiographic diagnosis of cervical pillar hyperplasia did not require expert skills (Stupar et al., 2003).

Bouliane et al. (2013) determined the intra- and inter-examiner reliability for Hill-Sachs and bony glenoid lesions using digital radiographs of the shoulder. The radiographs selected for this study were taken between April 2008 and June 2010. Four examiners (three orthopaedic surgeons and one radiologist) assessed 49 shoulder radiographs over two rounds (the years of clinical experience were not noted). The intra-examiner reliability ranged from moderate to almost perfect ($K = 0.41$ to $K = 0.86$) for the presence of Hill-Sachs and moderate to substantial ($K = 0.56$ to $K = 0.74$) for the evaluation of bony glenoid lesions. The results of the study emphasised the relevance of simple radiographic assessment methods in a clinical setting.

2.9 FACTORS AFFECTING THE INTRA- AND INTER-EXAMINER RELIABILITY OF RADIOGRAPH EXAMINATION

Several factors that affect intra- and inter-examiner reliability of assessing radiographs are summarised in **Table 2.5**.

Table 2.5 Factors which impact on intra- and inter-examiner reliability

Radiographic Factors	Anatomical Factors	Storage Factors	Experience Factors	Other Factors
Patient position	Anatomical obstruction	Exposure to chemicals	Poor assessment and	Examiner
Exposure factors	Anatomical landmark	Exposure to sunlight	interpretation of radiographs	concentration
Centering of the radiographic beam	differences		Clinical experience of examiner	Examiner fatigue
Display system used				
Equipment maintenance				
Poor darkroom film processing				

Data summarised from Taylor (1995); Roopnarian (2011); Edeh et al. (2012); Holmes et al. (2013)

These factors should be taken into consideration by the practitioner to establish the most appropriate radiographic image quality needed to obtain the correct diagnosis. They include proper patient positioning, ensuring that there is no movement while allowing for patient comfort. The direction of the radiographic beam, correct centering of the beam, collimation of the area of interest and the display system used for optimal viewing conditions are essential considerations (Holmes et al., 2013). Care has to be taken with regards to the maintenance of equipment which

requires regular calibration to reduce the amount of rejected plain film radiographs. Mentoring of inexperienced radiographers is needed in order to decrease the quantity of unacceptable diagnostic images being produced. The processing of these films in the dark room by the correct placement and removal from the film developer is important, as these play an essential role in the production of optimum radiographic images (Edeh et al., 2012).

Obstruction of landmarks as well as variations in the correct identification of the anatomical structures can cause confusion among examiners (Schulze and Doll, 2002; Roopnarian, 2011; Sicuressa et al., 2012). Schulze and Doll (2002) determined the variation in landmark identification on digital versus film-based cephalometrics radiographs. The study utilised eight post-graduate orthodontic students with 1-17 years of clinical experience. The examiners recorded six landmarks over two rounds on three film-based and three digital images. The study did not utilise the Kappa coefficient to determine the reliability but utilised the square differences of the Maloney-Rastogi tests. The results showed that intra- and inter-examiner reliability between the two image modes did not differ significantly, although, landmark variation for both assessments had been noted (Schulze and Doll, 2002). Furthermore, it was recommended that modern alternatives for assessment need to demonstrate a reliable diagnostic ability to formulate a gold standard before they are substituted for conventional methods of assessment. Roopnarian (2011) assessed the CL on plain film radiographs using the modified Cobb methods (C1-C7 and C2-C7). He reported that the obstruction of the trapezius muscle on the C7 VB landmark resulted in some incomplete assessments of the CL on the lateral radiograph (Roopnarian, 2011). Sicuressa et al. (2012) assessed the intra- and inter-examiner reliability in the accuracy of landmark identification on digital posterior-anterior cephalograms (PAC). The study involved three post-graduate orthodontists with 10–12 years of clinical experience. The results showed a large deviation in the correct identification of landmark positions amongst the examiners. This was due to the variability in the radiographic factors (**Table 2.5**) and soft tissue obstruction (Sicuressa et al., 2012).

Exposing plain film radiographs to chemicals can directly affect the ability to view and examine the radiograph as these can cause scratching, fading and deterioration of the image. Exposure to extreme temperatures and humidity will accelerate staining and cause peeling, flaking and cracking of the film. This will impact on the radiographic evaluation to be performed by the examiners by affecting image quality (Yochum and Rowe, 2005).

Experienced examiners are also vulnerable to errors in their own judgement as they may rely on 'rule of thumb' and 'subjective probability estimates' (Wood, 1999; Fitzgerald, 2001). Therefore, examiners need to be encouraged to improve their own skills by attending educational programs (Edeh et al., 2012). This is supported by research which highlight the significance of examiner training and review sessions to improve inter-examiner agreement in assessments of clinical performance that involve multiple examiners (Reubenson et al., 2012). Furthermore, the level of skill and number of years in practice reportedly had no effect on the inter-examiner reliability of clinical assessments (Reubenson et al., 2012); a finding consistent with those of previous studies on radiographic interpretation (Herman and Hessel, 1975; Norgaard et al., 1990; Taylor et al., 1995). Examiner fatigue can contribute to poor judgement and decision-making. This results in impaired performance and a decrease in the examiner's concentration (Grandjean, 1968; Dinges, 1995).

2.10 MISINTERPRETATION AND ERRORS IN RADIOGRAPH REPORTING

Misinterpretation and error in radiograph reporting between examiners has been widely documented (Robinson, 1997; Tudor and Finlay, 2001). When considering any measurement of error, a gold standard is needed in order to formulate a comparison. Taylor et al. (1995) suggested continued education of the examiner as a way to increase accuracy and improve clinical performance, but there is insufficient literature in the radiographic discipline to confirm this (Davis et al., 1992; Oxman et al., 1995; Davis et al., 1995; Tudor and Finlay, 2001).

Considerable responsibility is placed on chiropractors to correctly interpret a radiograph as they often have no method of confirming their diagnosis. Misunderstandings in the interpretation of the radiographs between practitioners (including chiropractors) may occur even if the radiologist's report is available (Berlin, 2000; Brealey et al., 2005). The reasons for variation and misinterpretation in radiographic assessments include limitations of technique, ambiguous or incomplete clinical data, incomplete scanning of the radiograph, misunderstanding of perceived findings, lack of knowledge, inaccuracy in judgement, as well as differences in anatomical structures which result in variation in the landmarks and measurements being utilised (Resnick and Taylor, 2000; Robinson, 1997; Fitzgerald, 2001; Tins and Cassar-Pullicino, 2004; Yochum and Rowe, 2005; Bono et al., 2010). Being unaware of or not appreciating the clinical history of a patient have been noted to reduce the overall accuracy of the final diagnosis (Taylor et al., 1995; Robinson, 1997; Tudor et al., 1997; Resnick and Taylor, 2000). Taylor et al. (1995) reported that restrictions in time allocations for viewing radiographs were known to cause incomplete

assessment of the radiograph. The authors were of the view that this did not mimic clinical situations and, therefore, examiners were content with only one perceived diagnosis or an irrelevant finding. The radiographs selected for a particular study play a significant role in the outcome of the results. They also recommended that future studies include radiographs more suitable for a particular health care profession as this would allow for a greater accuracy to be obtained during the examiners' assessments owing to a greater knowledge and understanding of the subject material.

2.11 CONCLUSION

The assessment of the CL is significant in a clinical setting as it may influence the clinical outcomes with regards to treatment of the patient. Although there are various methods to evaluate the CL radiographically, no agreement has been reached on a definitive method nor on specific normative reference values or ranges. Nevertheless, the most popular and widely-used techniques are the C1-C7 and C2-C7 modified Cobb methods which have been described by Harrison et al. (2000). Therefore, these methods were selected for the present study. The use of radiographs from asymptomatic individuals allows for the development of normative reference values. Intra- and inter-examiner reliability in the assessment of radiographs is important in the health care profession as considerable responsibility is placed on health care practitioners, including chiropractors, to correctly and reliably interpret radiographs. Misinterpretation and error in radiograph reporting between examiners and observers has been widely documented. This could apply to the CL as well because there is a need for sufficient interpretation of techniques as to not exclude subtle signs of pathology. However, there is a paucity of literature on chiropractors' inter- and intra-examiner reliability of the radiographic assessment of the CL. In addition to determining the intra- and inter-examiner reliability of the radiographic assessment of the CL, it is anticipated that the findings of this study will highlight the factors that may have an impact on the intra- and inter-examiner reliability of the plain film radiographic assessment of the CL by chiropractors. Determining a normal CL in a patient is important as it may influence the diagnosis and management of a patient by a chiropractor (Roopnarian, 2011; Naicker, 2012).

CHAPTER THREE

STUDY DESIGN

3.1 STUDY DESIGN

This research was designed as a quantitative, intra- and inter-examiner reliability study. Approval to conduct this study was obtained from the Durban University of Technology's Institutional Research Ethics Committee (IREC) (**Ethics Clearance Certificate No. REC82/14; Appendix A**)

3.2 POPULATION AND SAMPLE SIZE

The population was 80 lateral plain film radiographs of the cervical spine of asymptomatic males aged between 18-45 years (taken in a previous study). Upon completion of the previous study, the plain radiographs were stored individually in brown paper jackets in a dark room away from direct sunlight in the Chiropractic Day Clinic (CDC) at the DUT. Therefore, the sample size is the same as the population.

3.3 SAMPLING METHOD

No sampling method was utilised as all the available radiographs were included in this study.

3.4 INCLUSION AND EXCLUSION CRITERIA

3.4.1 Inclusion Criteria

Lateral plain film radiographs of the cervical spine of asymptomatic adult males between 18-45 years of age. These radiographs were taken of participants in a previous study and were still of good quality to be evaluated (Roopnarian, 2011). The use of radiographs belonging to males only allowed for the results to be representative of a homogenous group.

3.4.2 Exclusion Criteria

Any radiographic view besides a lateral radiograph of the cervical spine.

3.5 PERMISSION FOR OBTAINING THE RADIOGRAPHS

Permission for the use of the radiographs for this study was obtained from the Head of the Chiropractic Programme at the DUT (**Appendix B**).

3.6 INSTRUMENTS

The following instruments and measuring tools were utilised in this study:

- Portable x-ray viewing box with good lighting (the same viewing box was utilised throughout the study to reduce variation in lighting)
- A 30cm ruler
- Protractor (for measurement of angles)
- Staedtler® white eraser (to remove lines drawn on the plain film radiographs)
- HB clutch pencil (this was used to mark the angles and lines on the plain film radiographs)

All research participants utilised the same set of instruments to minimize measurement error and variability.

3.7 THE SELECTION OF THE EXAMINERS

The research examiners were as follows:

- Examiner One was a qualified chiropractor with three years of clinical experience whose Masters research involved the radiographic assessment of selected spinal parameters.
- Examiner Two was a qualified chiropractor with six years of clinical experience whose Masters research also involved the radiographic assessment of selected spinal parameters.
- Examiner Three was the researcher who is a chiropractic Master's student and based at the DUT with minimal clinical experience.

Examiners One and Two were chosen for their experience with radiographs as well as their availability for the study. Both examiners are in full-time private practice and are based within a 20km radius of the CDC.

3.8 THE RADIOGRAPHIC ASSESSMENT OF THE CERVICAL LORDOSIS

The CL was assessed according to the modified Cobb methods described in **Table 3.1**.

Table 3.1 The modified Cobb methods for evaluating the cervical lordosis utilised in this study

Reference	Method	Description
Harrison et al. (2000)	Modified Cobb method (C1-C7)	A line was drawn through and parallel to the inferior endplate of C7 and another was drawn through the midpoints of the anterior and posterior tubercles of the atlas. Perpendiculars were constructed to the point of intersection and the resultant angle was measured.
Harrison et al. (2000)	Modified Cobb method (C2-C7)	A line was constructed through and parallel to the inferior endplate of C7 and another was drawn through and parallel to the inferior endplate of C2. Perpendiculars were constructed to the point of intersection and the resultant angle was measured.

3.9 RESEARCH PROCEDURE

Prior to commencement of the study, a meeting was held amongst the three examiners to discuss the research procedure (**Appendix C**). The methods for the study were discussed with the examiners and each examiner had an opportunity to ask questions regarding the methods. The examiners were informed not to view their initial assessments when doing their second set of assessments or to communicate with each other to discuss their results. Each examiner was given a maximum of two weeks to complete each of their assessments.

3.9.1 Step One

The initial assessment of the CL using the two methods described in **Table 3.1** was completed by Examiner One and captured on an Excel spreadsheet (Microsoft Office Excel 2007). This was

labelled as “First CL Assessments Examiner One” and emailed to the supervisor of this research prior to commencement of the second assessment.

3.9.2 Step Two

The researcher collected the radiographs and instruments from Examiner One. The supervisor then erased any identifiable markings on the radiographs. The researcher then transported the radiographs and instruments to Examiner Two for the first set of assessments. These assessments were captured on an Excel spreadsheet and emailed to the supervisor labelled “First CL Assessments Examiner Two”.

3.9.3 Step Three

The procedure was repeated for Examiner Three. The assessments done by Examiner three were captured on an Excel spreadsheet and emailed to the supervisor labelled, “First CL Assessments Examiner Three”.

3.9.4 Step Four

The radiographs were handed to the supervisor to erase any identifiable markings on the radiographs. The researcher then transported the radiographs and instruments to Examiner One for the second set of assessments one month after the completion of the first set of assessments. The second set of assessments was captured on an Excel spreadsheet and emailed to the supervisor labelled “Second CL Assessments Examiner One”.

3.9.5 Step Five

The procedure, as described in Step Four, was repeated for Examiner Two and, thereafter, for Examiner Three.

3.10 STATISTICAL ANALYSIS

The data was statistically analysed using SPSS 22.0 and Stata 13 by an experienced statistician (Singh, 2015). Descriptive data were presented in tables as mean, standard deviation at a 95% confidence interval, standard error, minimum, maximum and range while intra- and inter-

examiner reliability were determined using the Cohen Kappa coefficient as recommended by Haas (1991) and utilised by Fryer (2005). Cohen's Kappa measures agreements between two examiners. Conventionally, a Kappa of <0.0 is considered poor agreement, 0.00-0.20 slight, 0.21-0.40 fair, 0.41-0.60 moderate, 0.61-0.80 substantial and more than 0.81 near total agreement. Given that Kappa is an estimate from a sample, the standard error (SE) provides an estimate of error (Landis and Koch, 1997). The 95% confidence interval (CI) is $Kappa \pm 1.96 SE$. While concordance is typically used as a scalar measurement of agreement, a 95% confidence interval of Kappa that does not cross the zero value allows a conclusion that signifies concordance exists (Landis and Koch, 1997). The significant difference in the intra-and inter-examiner reliability findings was determining using the *p*-values which are inherent of the Kappa statistics. A *p*-value <0.05 was considered statistically significant (Singh, 2015).

3.11 ETHICAL CONSIDERATION

There was no need to enrol and x-ray any participants which ruled out ionisation exposure to any participants (if they had to be enrolled for this study) and the researcher. Permission was obtained from the Head of the Chiropractic Programme before the radiographs were utilised for assessment (**Appendix B**). All radiographs were already coded so it was not possible for the researcher or anyone else to identify who the radiographs belonged to. In keeping with the standard operating procedure of the CDC, all patients and research participants sign a consent form that their clinical and radiographic records may be utilised for research purposes with the proviso that their identities are not revealed. All participants of Roopnarian's (2011) study signed this consent form which is in their clinic files. Informed consent was obtained from both examiners prior to their participation in the study (**Appendix C**). Ethical clearance was obtained from IREC before commencing this study (**Appendix A**).

CHAPTER FOUR

RESULTS

4.1 THE SOURCE OF THE PLAIN FILM RADIOGRAPHS

Eighty lateral radiographs of the cervical spine of asymptomatic males aged 18-45 years taken at a previous study (Roopnarian, 2011) were utilised for the present study. There were no names or other identifiable data on the radiographs or the data sheet.

4.2 THE MAGNITUDE OF THE CERVICAL LORDOSIS

The mean, standard deviation, standard error, maximum, minimum and range of the CL evaluated using the C1-C7 and C2-C7 modified Cobb methods by each examiner are shown in **Tables 4.1-4.2**. In some instances the correct identification of the necessary landmarks was either missed or clearly invisible as the C7 VB was obstructed by the trapezius muscle on the lateral radiograph. This would account for the decrease in the number (*n*) of complete radiographs assessed by all examiners although each examiner received 80 radiographs to assess at each time point.

A smaller mean, minimum and maximum value for the CL using the C2-C7 method was observed when compared to the C1-C7 method for CL across all examiners for both rounds. Larger minimum and maximum values were observed for the CL using the C1-C7 method when compared to the C2-C7 method. There was no major difference in the standard deviation or the standard error for all three examiners for both methods (**Tables 4.1-4.2**).

Examiner One reported higher means using the C1-C7 method for both rounds compared to the other two examiners (**Table 4.1**). The highest minimum value of the CL using the C1-C7 method was reported by Examiner One while the lowest minimum value was reported by Examiner Three in Round 1 (**Table 4.1**). The highest maximum value of the CL using the C1-C7 method was reported by Examiners One (Round 2) and Two (Round 1) while the lowest maximum value was reported by Examiner Two (Round 2). The highest range of the CL using the C1-C7 method was reported by Examiner Three (Round 1) and the lowest was by Examiner Two (Round 2) (**Table 4.1**).

For the C2-C7 method, Examiner Two reported higher means over both rounds than the other two examiners (**Table 4.2**). The lowest mean was reported by Examiner One in Round 1. The minimum value of the CL using the C2-C7 method was low for all three examiners with Examiner One reporting negative values over both rounds (**Table 4.2**). The highest maximum value of the CL using the C2-C7 method was reported by Examiner Two (Round 1) while Examiner One reported the lowest maximum value (Round 1). The highest range of the CL using the C2-C7 method was reported by Examiner Three (Round 1) while the lowest was reported by Examiners One (Round 1) and Two (Round 2).

Table 4.1 The mean, standard deviation, standard error, minimum, maximum and range of the cervical lordosis using the C1-C7 modified Cobb method for each examiner over the two rounds

	Examiner 1		Examiner 2		Examiner 3	
	Round 1	Round 2	Round 1	Round 2	Round 1	Round 2
Number	70	72	75	74	72	72
Mean	45.6	46.4	44.0	43.3	43.8	43.8
Std. deviation	10.4	10.7	11.0	11.1	12.0	11.5
Std. error	1.2	1.2	1.2	1.3	1.4	1.3
Minimum	18.0	18.0	15.0	16.0	12.0	14.0
Maximum	68.0	71.0	71.0	64.0	69.0	68.0
Range	50.0	53.0	56.0	48.0	57.0	54.0

Std = Standard; values are in degrees

Table 4.2 The mean, standard deviation, standard error, minimum, maximum and range of the cervical lordosis using the C2-C7 modified Cobb method for each examiner over the two rounds

	Examiner 1		Examiner 2		Examiner 3	
	Round 1	Round 2	Round 1	Round 2	Round 1	Round 2
Number	71	72	75	74	72	72
Mean	15.9	16.3	22.6	20.5	17.2	16.9
Std. deviation	9.2	9.4	9.7	9.0	9.7	9.2
Std. error	1.0	1.1	1.1	1.0	1.1	1.0
Minimum	-3.0	-2.0	5.0	5.0	0.50	1.0
Maximum	37.0	41.0	47.0	45.0	45.0	45.0
Range	40.0	43.0	42.0	40.0	44.5	44.0

Std = Standard; values are in degrees

4.3 THE INTRA-EXAMINER RELIABILITY OF THE RADIOGRAPHIC ASSESSMENT OF THE CERVICAL LORDOSIS USING THE MODIFIED COBB METHODS

In order to measure intra-examiner reliability (i.e. agreement) amongst the three examiners, Cohen's Kappa was used. The Kappa statistic measure of agreement is scaled between $K = 0$, which suggests that the agreement is what would be expected to be observed by chance, and $K = 1$ which implies a perfect agreement.

These were interpreted according to the suggested values by Landis and Koch (1997):

Below 0.0	Poor
0.00 – 0.20	Slight
0.21 – 0.40	Fair
0.41 – 0.60	Moderate
0.61 – 0.80	Substantial
0.81 – 1.00	Almost perfect

The Cohen's Kappa (K) scores for the intra-examiner reliability (agreement) are presented in **Tables 4.3-4.4** for the CL of both the modified Cobb methods for each round.

The intra-examiner agreement for the C1-C7 modified Cobb method over the two rounds was slight amongst the three examiners, ranging from $K = 0.11$ to $K = 0.16$ in the individual examiners. Examiner Two demonstrated a 13.70% agreement (actual) for the repeated measurements, while Examiner Three demonstrated an 18.06% agreement and Examiner One an 18.57% agreement. Applying a confidence interval of 95% as the criterion for the statistical significance of the C1-C7 method, the intra-examiner results demonstrated a statistical significant reliability ($p < 0.05$).

The intra-examiner agreement for the C2-C7 modified Cobb method over the two rounds was slight to fair among the three examiners, ranging from $K = 0.04$ to $K = 0.22$ in the individual examiners. Examiner Two demonstrated a 6.85% agreement for the repeated measurements, while Examiners Two and Three demonstrated a 23.94% and 25.00% agreement respectively. Applying a confidence interval of 95% as the criterion for the statistical significance of the C2-C7 method, the intra-examiner results demonstrated a statistical significant reliability ($p < 0.05$).

Table 4.3 The intra-examiner reliability of the radiographic assessment of the cervical lordosis using the C1-C7 modified Cobb method

	Kappa	Std. error	Agreement		p-value	CI (95%)
			Actual	Expected		
Examiner One	0.16	0.01	18.57%	2.65%	0.00	0.20
Examiner Two	0.11	0.02	13.70%	3.00%	0.00	0.14
Examiner Three	0.16	0.01	18.06%	1.91%	0.00	0.19

Std = Standard; CI = Confidence Interval

Table 4.4 The intra-examiner reliability of the radiographic assessment of the cervical lordosis using the C2-C7 modified Cobb method

	Kappa	Std. error	Agreement		p-value	CI (95%)
			Actual	Expected		
Examiner One	0.21	0.02	23.94%	3.11%	0.00	0.62
Examiner Two	0.04	0.02	6.85%	2.95%	0.02	0.07
Examiner Three	0.22	0.01	25.00%	2.76%	0.00	0.26

Std = Standard; CI = Confidence Interval

4.4 THE INTER-EXAMINER RELIABILITY OF THE RADIOGRAPHIC ASSESSMENT OF THE CERVICAL LORDOSIS USING THE MODIFIED COBB METHODS

The Cohen's Kappa (K) scores for inter-examiner reliability (agreement) are presented in **Tables 4.5-4.8** for the CL of the modified Cobb methods C1-C7 and C2-C7 for each round.

The inter-examiner agreement for the C1-C7 modified Cobb method for Round One was slight among the three examiners, ranging from K = 0.03 to K = 0.19 (**Table 4.5**). The agreement (actual) for the C1-C7 method for Round 1 between the three examiners was low for Examiner One versus Examiner Two (5.71%) and Examiner Two versus Examiner Three (5.56%) (**Table 4.5**). The actual agreement increased between Examiners One and Two (11.27%) and between Examiners Two and Three (11.11%) in Round 2 (**Table 4.6**). There was a slight decrease in the actual agreement between Examiners One and Three from Round 1 (21.43%) (**Table 4.5**) to Round 2 (18.31%) (**Table 4.6**). The inter-examiner agreement was statistically significant from

chance ($p < 0.05$) among the three examiners for the C1-C7 measurements over the two rounds (**Tables 4.5-4.6**). There was considerable variations in the inter-examiner agreement, using Cohen Kappa, between the individual examiners in the two rounds (**Tables 4.5-4.8**).

The inter-examiner agreement for the C2-C7 modified Cobb method over the two rounds was slight among the three examiners ranging from $K = 0.00$ to $K = 0.19$ in Round 1 (**Table 4.7**) and $K = 0.01$ to $K = 0.11$ in Round 2 (**Table 4.8**). The agreement (actual) for the C2-C7 method for Round 1 between the three examiners was low for Examiner One versus Examiner Two (2.82%) and Examiner Two versus Examiner Three (5.56%) (**Table 4.7**). The actual agreement increased between Examiners One and Two (4.23%) and between Examiners Two and Three (8.33%) in Round 2 (**Table 4.8**). There was a decrease in the actual agreement between Examiners One and Three from Round 1 (21.13%) (**Table 4.7**) to Round 2 (14.08%) (**Table 4.8**).

For the C2-C7 method, the inter-examiner agreement was significantly different from chance ($p < 0.05$) between Examiners One and Three and between Examiners Two and Three over the two rounds. There was, however, no significant difference in the inter-examiner agreement between Examiners One and Two over the two rounds (**Tables 4.7-4.8**).

Table 4.5 The inter-examiner reliability of the radiographic assessment of the cervical lordosis using the C1-C7 modified Cobb method for Round 1

	Round 1					
	Kappa	Std. error	Agreement		p value	CI (95%)
			Actual	Expected		
E1 vs E2	0.03	0.01	5.71%	2.47%	0.03	0.06
E1 vs E3	0.19	0.01	21.43%	2.31%	0.00	0.23
E2 vs E3	0.03	0.01	5.56%	1.66%	0.00	0.06

E = Examiner; Std = Standard; CI = Confidence Interval

Table 4.6 The inter-examiner reliability of the radiographic assessment of the cervical lordosis using the C1-C7 modified Cobb method for Round 2

Round 2						
	Kappa	Std. error	Agreement		<i>p</i> -value	CI (95%)
			Actual	Expected		
E1 vs E2	0.09	0.01	11.27%	2.22%	0.00	0.12
E1 vs E3	0.15	0.02	18.31%	3.04%	0.00	0.19
E2 vs E3	0.08	0.01	11.11%	2.45%	0.00	0.12

E = Examiner; Std = Standard; CI = Confidence Interval

Table 4.7 The inter-examiner reliability of the radiographic assessment of the cervical lordosis using the C2-C7 modified Cobb method for Round 1

Round 1						
	Kappa	Std. error	Agreement		<i>p</i> -value	CI (95%)
			Actual	Expected		
E1 vs E2	0.00	0.01	2.82%	2.10%	0.33	0.04
E1 vs E3	0.19	0.01	21.13%	2.56%	0.00	0.22
E2 vs E3	0.02	0.01	5.56%	2.80%	0.07	0.06

E = Examiner; Std = Standard; CI = Confidence Interval

Table 4.8 The inter-examiner reliability of the radiographic assessment of the cervical lordosis using the modified C2-C7 Cobb method for Round 2

Round 2						
	Kappa	Std. error	Agreement		<i>p</i> -value	CI (95%)
			Actual	Expected		
E1 vs E2	0.01	0.02	4.23%	2.84%	0.23	0.05
E1 vs E3	0.11	0.02	14.08%	3.21%	0.00	0.15
E2 vs E3	0.05	0.02	8.33%	3.18%	0.00	0.09

E = Examiner; Std = Standard; CI = Confidence Interval

CHAPTER 5

DISCUSSION

5.1 EXPLANATION FOR THE MISSING ASSESSMENTS OF THE CERVICAL LORDOSIS

Eighty lateral radiographs of the cervical spine of asymptomatic males aged 18-45 years taken in a previous study were utilised for the present study. There were no names or other identifiable data on the radiographs or the data sheet. Examiner One reported that the C7 VB was obstructed by the trapezius muscle in 10 radiographs (C1-C7 method) and in nine radiographs (C2-C7 method) in Round 1. Interestingly, the obstruction was reported by the same examiner in eight radiographs over the Round 2 for both methods. Obstruction of the C7 VB by the trapezius muscle was also reported by Examiner Two for five radiographs for both methods in Round 1 and six radiographs for both methods in Round 2. Examiner Three observed the obstruction of the C7 VB by the trapezius muscle in eight radiographs for both methods over both rounds. This would account for the decrease in the number of complete radiographs assessed amongst all examiners although each examiner received 80 radiographs to assess at each time point.

5.2 THE MAGNITUDE OF THE CERVICAL LORDOSIS

5.2.1 The C1-C7 Modified Cobb Method

The mean values of the CL for the two methods are shown in **Tables 4.1-4.2**. The average of the combined means of the CL determined by all three examiners using the C1-C7 method (44.5°) was lower than that reported by Harrison et al. (2000) and higher than that obtained using the Drexler's method (Drexler, 1962) and the Method of Gore (asymptomatic adults) (Gore et al., 1986) (**Table 2.4**). All three examiners of the present study reported a lower mean (**Table 4.1**) than that observed by Harrison et al. (2000). The mean CL values (C1-C7) of the present study was higher than the mean CL observed by Hardacker et al. (1997) for asymptomatic adults, although they utilised a slightly different method (i.e. C0-C7 method). The average of the combined means was also slightly lower than that reported by Roopnarian (2011) (45.7°; C1-C7 method) who utilised the same radiographs used in this study. The average of the combined means observed in the present study and by Roopnarian (2011) was higher than that reported by Naicker (2012) (38.9°; C1-C7 method) in asymptomatic adult females. This finding suggests differences in the magnitude of the CL between the sexes.

5.2.2 The C2-C7 Modified Cobb Method

The average of the combined means of the CL determined by all three examiners using the C2-C7 method (18.2°) was higher than that reported by Harrison et al. (2000) (**Table 2.4**). Examiner One's average of the combined means over the two rounds (16.1°) was smaller than that reported by Harrison et al. (2000). On the other hand, the average of the combined means over the two rounds for Examiner Two (21.6°) was higher than that reported by Harrison et al. (2000). For Examiner Three, the combined average of the means over the two rounds (17.1°) was similar to that observed by Harrison et al. (2000). It should, however, be noted that Harrison et al. (2000) did not specify if their results were of asymptomatic or symptomatic individuals and their sample size was smaller than that of the present study.

The average of the combined means observed in this study was lower than that obtained by the method of Gore (1986) and the posterior tangent method utilised by Owens and Hoiris (1990) (**Table 2.4**) and higher than that reported by Roopnarian (2011) (15.9°) and Naicker (2012) (11.3°). The results of the present study for both methods as well those reported by Roopnarian (2012) reinforces the hypothesis that the magnitude of the CL is higher in males than females, which highlights the need for establishing sex-specific mean values for the CL. The results of the present study are also in agreement with those of Harrison et al. (2000) who observed that the C1-C7 modified method over-valued the magnitude of the curve while the C2-C7 modified method under-valued the curve. The causes of this are thought to be the inferior endplates of the VB and the shape of the antero-inferior body of C2 (Harrison et al., 2000).

5.3 THE INTRA- AND INTER-EXAMINER RELIABILITY OF THE ASSESSMENT OF THE CERVICAL LORDOSIS

The intra-examiner agreement amongst the examiners for the C1-C7 method between both rounds, showed a slight measuring agreement as follows: Examiner One (K = 0.16); Examiner Two (K = 0.11) and Examiner Three (K = 0.16) (**Table 4.3**). The intra-examiner agreement was between slight and fair for the C2-C7 method as follows: Examiner One (K = 0.21), Examiner Two (K = 0.04) and Examiner Three (K = 0.22), respectively (**Table 4.4**). These results show a large variation in the consistency between each examiner for both the C1-C7 and C2-C7 methods. The results of the present study are consistent with the findings of previous studies although in the latter, other conditions were assessed and not the CL (Norgaard et al., 1990; Tudor et al., 1997; Stupur et al., 2002; Bouliane et al., 2013).

The inter-examiner agreement between the examiners, for the C1-C7 method for both rounds, showed a slight agreement between each other (**Tables 4.5-4.6**). Similar agreements between examiners were observed for the C2-C7 method for both rounds (**Tables 4.7-4.8**).

The results of this study did not find that the C2-C7 method had a higher inter-examiner reliability than the C1-C7 modified Cobb method and is, therefore, not in agreement with Norgaard et al. (1990) who concluded that the method of examination utilised plays a significant role in the inter-examiner assessment of radiographs. It is, therefore, recommended that the study is repeated with a larger sample size using both manual and digital assessment methods in order to determine the inter-examiner reliability of both methods. A direct comparison of the results of this study could not be made with the inter-examiner reliability studies of Norgaard et al. (1990), Taylor et al. (1995), Tudor et al. (1997), Stupar et al. (2003) and Bouliane et al. (2013) (**Section 2.8**) due to the differences in the radiographic conditions (diagnoses) selected for those studies. Moreover, the examiners (i.e. the participants) of those studies not have to evaluate the radiographs by drawing lines and assessing the measurements.

The plain film radiographs used in the present study were stored in dim-lit room (each in a brown paper jacket) for three years prior to this study. Deterioration of the radiographic film has been reported to cause poor evaluation in the examination of the radiograph (Yochum and Rowe, 2005). Although it is possible that prolonged storage might have impacted on the image quality and identification of anatomical landmarks, it is important to note that no examiner reported poor image quality. An anatomical landmark, specifically the trapezius muscle, obstructed the correct identification of the C7 VB in some radiographs as described in **Section 5.1**.

Examiner fatigue and concentration may have impacted on both the intra- and inter-examiner reliability findings. Each examiner was given a total of two weeks per round for their assessment of the radiographs; this allowed for about six (80 radiographs/14 days) radiographic assessments per day. The assessment of six radiographs per day was suggested as a rough guideline. The time interval between each radiographic assessment and the number of assessments per day for each examiner was, however, unknown to the researcher. The examiners could have assessed the radiographs after a busy day in practice which may have impacted on their judgement and accuracy. Even though each examiner utilised the same set of radiographs, viewing box and assessment tools (viz. 30cm ruler, protractor, Staedtler® white eraser and HB clutch pencil), it was impossible for the viewing conditions to be identical for each examiner. The use of the HB clutch pencil allowed for the drawing of lines of uniform thickness

by all three examiners which could also be easily erased without deteriorating the image quality. The exposure factors (70kVp and 20mAs) of the radiographs were not deemed significant factors in the examiners' reliability as these were set according to the guidelines of the Radiography Clinic at DUT when the radiographs were first taken and the images were of a good quality (Roopnarian, 2012). It is possible that the different examination sites had variable viewing conditions. The time of day of the examination assessment, the use of natural lighting or artificial lighting in the examination room, white light versus yellow lighting in the room might have had an impact on optimal viewing conditions (Taylor et al., 1995; Edeh et al., 2012; Holmes et al., 2013).

The level of experience between the examiners involved in this study varied substantially. Examiner One was a qualified chiropractor with three years of clinical experience, Examiner Two was a qualified chiropractor with six years of clinical experience and Examiner Three was a chiropractic master's student with little clinical experience. Examiners One and Two were also involved previously in studies on radiographic assessments. The agreements between the examiners was different to previous reports (Taylor et al., 1995; Edeh et al., 2012; Reubenson et al., 2012), as the level of skill and number of years in clinical practice for the examiners in this study possibly had an effect on the inter-examiner (for the C2-C7 Cobb modified method), but not intra-examiner, reliability of the results. One would have expected to find a non-significant difference in the intra-examiner findings if the skill and experience of the examiners influenced the second set of assessments. The significant difference in the intra-examiner reliability ($p < 0.05$) also suggests that recall bias (the ability to remember the previous assessments and findings) did not significantly influence the outcome of the assessments.

For the C1-C7 modified Cobb method, all three examiners achieved a significant difference ($p < 0.05$) for the inter-examiner reliability in both rounds (**Tables 4.5-4.6**). Therefore, the clinical experience and skill of each examiner did not have a significant impact in the assessment of the CL using this method. It is also important to report that previous inter-examiner reliability studies which reported on the role of the experience and skill of the examiners (Taylor et al., 1995; Edeh et al., 2012; Reubenson et al., 2012) only involved the correct identification of pathology between examiners and did not require the examiners to assess a radiograph through manual drawing of lines on identified anatomical landmarks.

For the C2-C7 modified Cobb method, Examiner One and Examiner Two, who are both in private clinical practice and have three and six years of clinical experience, respectively, the

inter-examiner reliability was significantly different ($p < 0.05$) (**Table 4.8**) or close to significantly different (although still non-significant) ($p = 0.07$) to Examiner Three (**Table 4.7**). This finding suggests that for this method of assessing the CL, the clinical experience and skill of each examiner did influence the results.

All the examiners were aware that the radiographs belonged to asymptomatic adult males. Therefore, the knowledge of the brief history of the radiographs would not have significantly affected the outcome of the results. The plain film radiographs selected for assessments were suited towards the profession of the participants (i.e. chiropractic) of this study. Although selection of discipline-specific radiographs reportedly allowed for greater reliability and accuracy to be obtained during the examiners assessments (Taylor et al., 1995), this was not observed in this study. This suggests that assessments that require drawing of lines and measuring of angles might lead to differences in the results obtained from examiners as opposed to results obtained simply by “reading” the radiograph, which was the case in previous studies (Norgaard et al., 1990; Taylor et al. 1995; Tudor et al., 1997; Stupar et al., 2003; Bouliane et al., 2013). It has been previously reported that the differences in the tilt and structure of the endplates may influence the angles constructed during radiographic assessment (Vrtovec et al., 2009).

The correct identification of the anatomical landmarks and the subsequent drawing of the lines possibly varied among the examiners of the present study. When drawing the line on the inferior vertebral endplate of C2 and C7, variations might have occurred with regards to the line being drawn on the apex of the endplate or the on anterior and posterior lipping of the endplate. When drawing the line for the C1 measurement, variations might have occurred as to the exact midpoint of the anterior and posterior tubercles (**Figure 5.1**). These variations in the identification of the anatomical landmarks which are similar and consistent to those reported in previous studies (Hardacker et al., 1997; Harrison et al., 2000; Vrtovec et al., 2009), could have contributed to differences in the results of the CL between the examiners of the present study.

The level of agreement amongst the examiners between the two rounds indicates that we can accept the Alternate Hypothesis (H_a) that there was a significant difference ($p < 0.05$) in the intra-examiner reliability of the CL using both modified Cobb methods. We can accept the Alternate Hypothesis (H_a) for the inter-examiner reliability of the CL using the C1-C7 modified Cobb method, as the results showed significant differences ($p < 0.05$) between all three examiners over the two rounds. For the inter-examiner reliability of the C2-C7 modified Cobb method, however, we partially accept the Alternate Hypothesis (H_a) as the inter-examiner

reliability showed no significant difference of the CL for the C2-C7 modified Cobb method in the ratings between Examiner One versus Examiner Two ($p = 0.33$) for Round One and for Round Two ($p = 0.23$), but there was a significant difference in the ratings between Examiner One and Examiner Three for both rounds ($p < 0.05$) and between Examiner Two and Examiner Three for Round Two ($p < 0.05$).

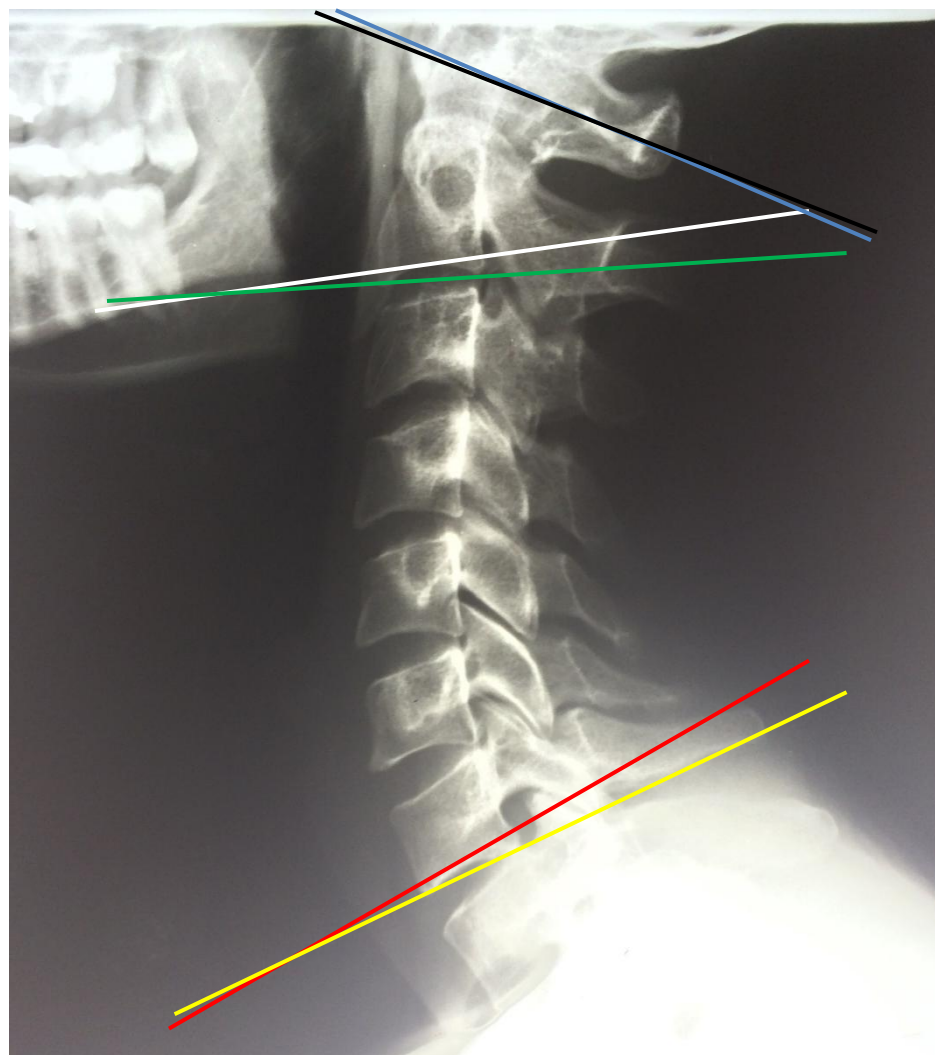


Figure 5.1 Examples of the variations in the position of the lines drawn during the assessment of the cervical lordosis using the modified Cobb methods

KEY

- Blue line : A line drawn through the midpoints of the anterior and posterior tubercles of the C1
- Black line : A line drawn through the midpoints of the anterior and posterior tubercles of the C1
- Green line : A line drawn tangential to the apex of the convexity of the endplate of the C2
- White line : A line drawn through the anterior and posterior lip of the endplate of the C2
- Yellow line : A line drawn tangential to the apex of the convexity of the endplate of C7
- Red line : A line drawn through the anterior and posterior lip of the endplate of C7

5.4 THE RELEVANCE OF THE FINDINGS OF THE STUDY

The difficulty of, length of time of and unfamiliarity with the numerous techniques utilised to assess CL increases human error (Drexler, 1962; Gore et al. 1986, Harrison et al., 1996; Hardacker et al., 1997). These factors may have contributed to the differences in the mean values of the CL reported in the literature (Jochumsen, 1969; Owens and Hoiris, 1990; Lim and Wong, 2004; Gore et al., 2006) and in the present study. The results of the present study reinforce the need for determining specific normative reference values or ranges for each of the sexes to assist clinicians (e.g. chiropractors and spinal surgeons) in their radiographic assessment of the CL. Furthermore, it is also important that the method of assessment utilised for the examination of the CL is provided as it will assist the examiners in their interpretation of the radiographic findings. The values obtained using the different techniques vary considerably and if a clinician is unaware of the normative reference value obtained using a particular technique, this may impact on the diagnosis and even management of cervical spine disorders (if the desired outcome is to achieve a normal lordotic curve following treatment).

Intra- and inter-examiner reliability is a significant outcome when assessing competence in the examination of the CL in the medical and allied health professions. The findings of this study were not related to identifying pathology, but to the drawing of lines and assessment of the angle of an important radiographic parameter. The results of this study have shown considerable differences in intra- and inter-examiner reliability in the assessment and reporting of values of the CL. This may impact on the assessment of the CL in clinical practice (especially with regards to intra-examiner assessments) and, hence, the management and treatment outcomes of the patient. Therefore, more attention needs to be focused on the choice of method of assessment, the standardisation of the examiners viewing conditions and the provision of previous clinical history of a patient to allow for improved examiner reliability and accuracy.

5.5 LIMITATIONS OF THE STUDY

Limitations of the study included the small number of examiners used for this study (three examiners) and the use of plain film radiographs that were in storage for about three years. The use of different examination venues and viewing conditions (e.g. variability in lighting of the room) for each radiographic examiner was not standardised. This might have contributed to the variability of viewing conditions. Since two of the examiners were in busy private clinical practices, and were not able to attend the DUT, it was not possible to conduct the assessments

in a single venue. The use of manual radiographic assessments which required drawing of a few lines and measuring angles possibly contributed to an increase in human error.

CHAPTER 6

CONCLUSION AND RECOMMENDATIONS

6.1 CONCLUSION

The mean (\pm SD) CL values obtained by each examiner using the C1-C7 modified Cobb method for Round One was:

- Examiner One: $45.6^\circ (\pm 10.4^\circ)$ ($n = 70$)
- Examiner Two: $44.0^\circ (\pm 11.0^\circ)$ ($n = 75$)
- Examiner Three: $43.8^\circ (\pm 12.0^\circ)$ ($n = 72$)

The mean (\pm SD) CL values obtained by each examiner using the C1-C7 modified Cobb method for Round Two was:

- Examiner One: $46.4^\circ (\pm 10.7^\circ)$ ($n = 72$)
- Examiner Two: $43.3^\circ (\pm 11.1^\circ)$ ($n = 74$)
- Examiner Three: $43.8^\circ (\pm 11.5^\circ)$ ($n = 72$)

The mean (\pm SD) CL values obtained by each examiner using the C2-C7 modified Cobb method for Round One was:

- Examiner One: $15.9^\circ (\pm 9.2^\circ)$ ($n = 71$)
- Examiner Two: $22.6^\circ (\pm 9.7^\circ)$ ($n = 75$)
- Examiner Three: $17.2^\circ (\pm 9.7^\circ)$ ($n = 72$)

The mean (\pm SD) CL values obtained by each examiner using the C2-C7 modified Cobb method for Round Two was:

- Examiner One: $16.3^\circ (\pm 9.4^\circ)$ ($n = 72$)
- Examiner Two: $20.5^\circ (\pm 9.0^\circ)$ ($n = 74$)
- Examiner Three: $16.9^\circ (\pm 9.2^\circ)$ ($n = 72$)

The intra-examiner reliability for the C1-C7 modified Cobb method for Round One and Round Two was:

- Examiner One: $K = 0.16$
- Examiner Two: $K = 0.11$
- Examiner Three: $K = 0.16$

The intra-examiner reliability for the C2-C7 modified Cobb method for Round One and Round Two was:

- Examiner One: $K = 0.21$
- Examiner Two: $K = 0.04$
- Examiner Three: $K = 0.22$

The inter-examiner reliability for the C1-C7 modified Cobb method for Round One and Round Two, respectively, was:

- Examiner One vs Examiner Two: $K = 0.03$; $K = 0.09$
- Examiner One vs Examiner Three: $K = 0.19$; $K = 0.15$
- Examiner Two vs Examiner Three: $K = 0.03$; $K = 0.08$

The inter-examiner reliability for the C2-C7 modified Cobb method for Round One and Round Two, respectively, was:

- Examiner One vs Examiner Two: $K = 0.00$; $K = 0.01$
- Examiner One vs Examiner Three: $K = 0.19$; $K = 0.11$
- Examiner Two vs Examiner Three: $K = 0.02$; $K = 0.05$

There was a significant difference in the intra-examiner findings for both the modified Cobb methods ($p < 0.05$). Using the C1-C7 modified Cobb method, there was a significant difference in the inter-examiner reliability findings between all three examiners for both rounds ($p < 0.05$). There was no significant difference in the inter-examiner findings of the CL using the C2-C7 modified method between Examiner One and Examiner Two for Round One ($p = 0.33$) and Round Two ($p = 0.23$) but there was a significant difference in the findings between Examiner

One and Examiner Three ($p < 0.05$) and between Examiner Two and Examiner Three ($p < 0.05$) for Round Two only.

6.2 GUIDELINES TO IMPROVE INTRA- AND INTER-EXAMINER RELIABILITY OF RADIOGRAPHIC INTERPRETATION

Based on the findings of this study, the following guidelines have been proposed to improve the reliability of radiographic assessments (**Table 6.1**):

Table 6.1 Guidelines to improve the reliability of radiographic assessments

Factors	Recommendations
Training of examiners	It is recommended that chiropractic clinicians continuously maintain their radiographic assessment skills by attending educational programs and training in order to improve agreement and accuracy of the radiographic assessment, especially with identifying anatomical landmarks and drawing of lines and measuring angles manually (Taylor et al., 1995; Edeh et al., 2012).
Viewing conditions	Standardisation of the examination equipment and the viewing site (room lighting, viewing box) need to be ensured in order to decrease examination variability and improve intra- and inter-examiner reliability (Taylor et al., 1995; Edeh et al., 2012).
Clinical history	As far as possible, the clinical history, even if it is brief, should be provided as the availability of the relevant clinical history of the patient for the examiner will improve the overall accuracy for the assessment of radiographs. This is especially important in the assessment of radiographs for radiographic signs of pathology. The presence of previous radiographic films of the patient is also known to improve diagnostic accuracy (Taylor et al., 1995; Robinson, 1997; Tudor et al., 1997; Resnick and Taylor, 2000).
Computer-assisted assessment	With advancements in medical technology, the use of image-processed radiographic films is being replaced with new generation computer-assisted digital image alternatives. These digital images are shown to improve the accuracy of interpretation and reduce examiner variation (Robinson, 1997). This will allow for the drawing of lines without manual erasing and eliminate image deterioration. However, the image resolution must be of a high degree. Therefore, a shift towards the latest digital imaging should improve intra- and inter-examiner reliability.

6.3 RECOMMENDATIONS

A similar study should be conducted to assess the CL utilising digitised radiographic images of both symptomatic and asymptomatic individuals, and using examiners from the chiropractic and medical disciplines. The radiographs selected should include a broader age spectrum (i.e. children to the elderly) as well.

A study should be conducted to assess the intra- and inter-examiner reliability of other radiographic assessments that require measurements (e.g. sagittal canal diameter or the prevertebral soft tissue spaces, both of which are assessed in the lateral view of the cervical spine) in both asymptomatic and symptomatic individuals.

REFERENCES

- Anderson, S.M. 2007. Spinal curves and scoliosis. *Radiologic Technology*; 79: 44-65.
- Assendelft, W., Bouter, L., Knipschild, P. and Wilmink, J. 1997. Reliability of lumbar spine radiograph reading by chiropractors. *Spine*; 22: 1235-1241.
- Bagnall, K.M. Harris, P.F. and Jones, P.R.M. 1977. A radiographic study of the human foetal spine Part I: The development of the secondary cervical curvature. *Journal of Anatomy*; 123: 777-782.
- Berlin, L. 2000. Malpractice issues in radiology: pitfalls of the vague radiology report. *American Journal of Roentgenology*; 174: 1511-1518.
- Berthonnaud, E., Dimnet, J., Roussouly, P. and Labelle, H. 2005. Analysis of the sagittal balance of the spine and pelvis using shape and orientation parameters. *Journal of Spinal Disorders and Techniques*; 18: 40-47.
- Bogduk, N. and Mercer, S. 2000. Biomechanics of the cervical spine Part I: Normal kinematics. *Clinical Biomechanics*; 15: 633-648.
- Bono, C., Schonenfeld, A., Anderson, P., Harrop, J., France, J., Vaccaro, A., Dvorak, M. and Fehlings, M. 2010. Observer variability of radiographic measurements of C2 (axis) fractures. *Spine*; 32: 1206-1210.
- Borden, A.G.B., Rechtman, A.M. and Gershon-Cohen, J. 1960. The normal cervical lordosis. *Radiology*; 74: 806-809.
- Bouliane, M., Chan, H., Kemp, K., Glasgow, R., Lambert, R., Beaupre, L. and Sheps, D. 2013. The intra- and inter-rater reliability of plain radiographs for Hill–Sachs and bony glenoid lesions: evaluation of the radiographic portion of the instability severity index score. *Shoulder and Elbow*; 5: 33-38.
- Boyle, J.J.W., Milne, M. and Singer, K.P. 2002. Influence of age on cervicothoracic spinal curvature: An *ex vivo* radiographic survey. *Clinical Biomechanics*; 17: 361-367.
- Braaf, M.M. and Rosner, S. 1975. Trauma of the cervical spine as a cause of chronic headache. *Journal of Trauma and Acute Care Surgery*; 15: 441-446.

Brealey, S., King, D., Hahn, S., Crowe, M., Williams, P., Rutter, P. and Crane, S. 2005. Radiographers and radiologists reporting plain radiograph requests from accident and emergency and general practice. *Clinical Radiology*; 60: 710-717.

Brault, J.R., Siegmund, G.P. and Wheeler, J.B. 2000. Cervical muscle response during whiplash: Evidence of a lengthening muscle contraction. *Clinical Biomechanics*; 15: 426-435.

Collins, P., Wigley, C.B. and Newell, R.L.M. 2005. Head and neck. In Standring, S. Gray's Anatomy. 40th ed. Spain: Elsevier Churchill Livingstone.

Coste, J., Paolaggi, J. and Spira, A. 1991. Reliability of interpretation of plain lumbar spine radiographs in benign, mechanical, low-back pain. *Spine*; 16: 426-428.

Cote, P., Cassidy, J.D., Yong-Hing, K., Sibley, J. and Loewy, J. 1997. Apophyseal joint degeneration, disc degeneration and sagittal curve of the cervical spine. *Spine*; 22: 859-864.

Davis, D.A., Thomson, M.A., Oxman, A.D. and Haynes, R.B. 1992. Evidence for the effectiveness of CME. A review of fifty randomised controlled trials. *Journal of the American Medical Association*; 268: 1111-1117.

Davis, D.A., Thomson, M.A., Oxman, A.D. and Haynes, R.B. 1995. Changing physician performance: a systematic review of continuing medical education strategies. *Journal of the American Medical Association*; 274: 700-705.

de Zoete, A., Assendelft, W., Algra, P., Oberman, W., Vanderscheuren, G. and Bezemer, P. 2002. Reliability and validity of lumbosacral spine radiograph reading by chiropractors, chiropractic radiologists and medical radiologists. *Spine*; 27: 1926-1933.

Dinges, D. 1995. An overview of sleepiness and accidents. *Journal of Sleep Research*; 4: 4-14.

Dorland, I. and Newman, W.A. 2007. Dorland's Illustrated Medical Dictionary. 31st ed. Philadelphia: Saunders.

Drexler, L. 1962. Roentgenotomische Untersuchungen über Form und Krümmung der Halswirbelsäule in den verschiedenen Lebensaltern. *Hippocrates*. Stuttgart.

Edeh, V., Olowoyeye, O., Irurhe, N., Abonyi, L., Arogundade, R., Awosanya, G., Eze, C. and Omiyi, O. 2012. Common factors affecting radiographic diagnostic quality in x-ray facilities in Lagos. *Journal of Medical Imaging and Radiation Sciences*; 43: 108-111.

Espeland, A., Korsbrekke, K., Albrektsen, G. and Larsen, J. 1998. Observer variation in plain radiography of the lumbosacral spine. *British Journal of Radiology*; 71: 366-375.

Fast, A. and Goldsher, D. 2007. Navigating the Adult Spine. New York: Demos Medical Publishing.

Fice, J. and Cronin, D. 2012. Investigation of whiplash injuries in the upper cervical spine using a detailed neck model. *Journal of Biomechanics*; 45: 1098-1102.

Fitzgerald, R. 2001. Error in Radiology. *Clinical Radiology*; 5: 938-946.

Fryer, G. 2005. Factors affecting the intra-examiner and inter-examiner reliability of palpation for supine medial malleoli asymmetry. *International Journal of Osteopathic Medicine*; 9: 58-65.

Gatterman, M. 2003. Chiropractic Management of Spine Related Disorders. 2nd ed. USA: Lippincott Williams & Wilkins.

Gore, D.R., Sepic, S.B. and Gardner, G.M. 1986. Roentgenographic findings of the cervical spine in asymptomatic people. *Spine*; 11: 521.

Grandjean, E. 1968. Fatigue: its physiological and psychological significance. *Ergonomics*; 11:427-436.

Grob, D., Frauenfelder, H. and Mannion, A.F. 2007. The association between cervical spine and neck pain. *European Spine Journal*; 16: 669-678.

Haas, M. 1991. The reliability of reliability. *Journal of Manipulative Physiological Therapeutics*; 14:199-208.

Hardacker, J.W., Shuford, F.R., Copkotto, P.N. and Pryor, W.P. 1997. Radiographic standing cervical segmental alignment in adult volunteers without neck symptoms. *Spine*; 22: 1472-1480.

Harrison, D.D., Janik, T.J., Troyanovich, S.J. and Holland, B. 1996. Comparisons of lordotic cervical spine curvatures to a theoretical ideal model of the static sagittal cervical spine. *Spine*; 21: 667-675.

Harrison, D.E., Harrison, D.D., Calliet, R., Troyanovich, J.S., Janik, T.J. and Holland, B. 2000. Cobb Method or Harrison Posterior Tangent Method: Which to choose for lateral cervical radiograph analysis. *Spine*; 25: 2072-2078.

Herman, P.G. and Hessel, S.J. 1975. Accuracy and its relationship to experience in the interpretation of chest radiographs. *Investigative Radiology*; 10: 62-67.

Holmes, K., Elkington, M. and Harris, P. 2013. *Clark's Essential Physics in Imaging for Radiographers*. School of Medical Imaging Sciences. UK: Taylor and Francis Group.

Jackson, R.P. and McManus, A.C. 1994. Radiographic analysis of sagittal plane alignment and balance in standing volunteers and patient's with low back pain matched for age, sex, and size: a prospective controlled clinical study. *Spine*; 19: 1611-1618.

Jochumsen, O.H. 1969. Diagnostics. *Journal of Clinical Chiropractic*; 2: 88.

Kendall, F.P. and McCreary, E.K. 1993. Muscles, testing and function. *British Journal of Sports Medicine*; 18: 25-26.

Landis, J.R. and Koch, G. 1997. The measurement of observer agreement for categorical data. *Biometrics. International Biometric Society*; 33: 159-174.

Lim, J.K. and Wong, K.H. 2004. Variation of the cervical spinal Torg ratio with gender and ethnicity. *Spine*; 4: 396-401.

Lindell, O., Eriksson, L. and Strender, L. 2007. The reliability of a 10-test package for patients with prolonged back and neck pain: could an examiner without formal medical education be used without loss of quality? A methodological study. *BMC Musculoskeletal Disorders*; 8: 31-32.

Marchiori, D.M. and Henderson, C.N. 1996. A cross-sectional study correlating cervical radiographic degenerative findings to pain and disability. *Spine*; 21: 2747- 2751.

Marais, C. 2011. Chiropractors' inter- and intra-examiner reliability of cervical spine radiographic analysis and its impact on clinical management. M.Tech. Dissertation, Durban University of Technology.

McAviney, J., Schulz, D., Bock, R., Harrison, D.E. and Holland, B. 2005. Determining relationship between cervical lordosis and neck complaints. *Journal of Manipulative and Physiological Therapeutics*; 28: 187-193.

Middleditch, A. and Oliver, J. 2005. *Functional Anatomy of the Spine*. 2nd ed. USA: Elsevier Butterworth Heinemann.

Moore, L.K. and Dalley, F.A. 2006. *Clinically Oriented Anatomy*. 4th ed. Baltimore. Lippincott Williams & Wilkins.

Nagasawa, A., Sakakibara, T. and Takahashi, A. 1993. Roentgenographic findings of the cervical spine in tension-type headache. *Journal of Head and Face Pain*; 33: 90-95.

Naicker, J. 2012. Ethnic Variations of Selected Cervical Spine Radiographic Parameters of Females in KwaZulu Natal. M.Tech. Dissertation, Durban University of Technology.

Nordin, M. and Frankel, H. 2001. Basic Biomechanics of the Musculoskeletal System. 3rd ed. Baltimore: Lippincott Williams & Wilkins.

Norgaard, H., Gjorup, T., Brems-Dalgaard, E., Harteluis, H., and Brun, B. 1990. Interobserver variation in the detection of pulmonary venous hypertension in chest radiographs. *European Journal of Radiology*; 11: 203-206

Ohara, A., Miyamoto, K., Naganawa, T., Matsumoto, K. and Shimizu, K. 2006. Reliabilities of and correlations among five standard methods of assessing the sagittal alignment of the cervical lordosis. *Spine*; 31: 2585-2591.

Okada, E., Matsumoto, M. and Ichihara, D. 2009. Does the sagittal alignment of the cervical spine have an impact on disk degeneration? Minimum 10-year follow-up of asymptomatic volunteers. *European Spine Journal*; 18: 1644-1651.

Ory, P.A. 2003. Radiography in the assessment of musculoskeletal conditions. *Best Practice and Research Clinical Rheumatology*; 17: 495-512.

Owens, E.F. and Hoiris, K. 1990. Cervical curvature assessment using digitized radiographic analysis. *Chiropractic Research Journal*; 4: 47-62.

Oxman, A.D., Thomson, M.A., Davis, D.A. and Haynes, R.B. 1995. No magic bullets: a systematic review of 102 trials of interventions. *Canadian Medical Association Journal*; 153:1423-1427.

Peterson, C., Kirk, R., Isdahl, M. and Humphrey, B. 1999. Prevalence of hyperplastic articular pillars in the cervical spine and relationship with cervical lordosis. *Journal of Manipulative and Physiological Therapeutics*; 22: 390-394.

Peterson, D. and Bergmann, T. 2002. Chiropractic Technique: Principles and Procedures. 2nd ed. Michigan: Mosby Inc.

Petrie, A. and Sabin, C. 2009. Medical Statistics at a Glance. UK: Blackwell Science Ltd.

Philips, R. 1992. Plain film radiology in chiropractic. *Journal of Manipulative and Physiological Therapeutics*; 15: 47-50.

Philips, R., Frymoyer, J., MacPherson, B. and Newburg, A. 1986. Low back pain: A radiographic enigma. *Journal of Manipulative and Physiological Therapeutics*; 9: 183-187.

Pouletaut, P., Dalqamoni, H., Marin, F. and Ho Ba Tho, M.C. 2010. Influence of age, gender and weight on spinal osteoarthritis in the elderly: an analysis of morphometric changes using x-ray images. *Alliance for Engineering in Biology and Medicine*; 31: 141-147.

Resnick, D. and Taylor, J. 2000. Skeletal imaging: atlas of the spine and extremities. USA: WB Saunders.

Reubenson, A., Tanis Schnepf, T., Waller, R. and Edmondston, S. 2012. Inter-examiner agreement in clinical evaluation. *The Clinical Teacher*; 9: 119-122.

Robinson, P. 1997. Radiology's Achilles heel: error and variation in the interpretation of roentgen image. *British Journal of Radiology*; 70: 1085-1098.

Roopnarian, A. 2011. Ethnic Variations of Selected Cervical Spine Radiographic Parameters of Males in KwaZulu Natal. M.Tech. Dissertation, Durban University of Technology.

Roussouly, P., Gollagly, S., Berthonnaud, E. and Dimnet, J. 2005. Classification of the normal variation in the sagittal alignment of the human lumbar spine and pelvis in the standing position. *Spine*; 30: 346-352.

Rubinstein, S. and van Tulder, M. 2008. A best-evidence review of diagnostic procedures for neck and low-back pain. *Clinical Rheumatology*; 22: 471-482.

Rybak, L.D. and Rosenthal, D.I. 2001. Radiological imaging for the diagnosis of bone metastases. *Quarterly Journal of Nuclear Medicine*; 45: 53-64.

Schulze, R. and Doll, G. 2002. Landmark identification on direct digital versus film-based cephalometric radiographs: A human skull study. *American Journal of Orthodontics and Dentofacial Orthopaedics*; 12: 635-641.

Segen, J.C. 2012. Segen's Medical Dictionary. Philadelphia: Farlex, Inc.

Sicurezza, E., Greco, M., Giordano, D., Maiorana, F. and Leonardi, R. 2012. Accuracy of landmark identification on postero-anterior cephalograms. *Progress in Orthodontics*; 13: 132-140.

Singh, D. 6 July 2015. *Chiropractic Research*. E-mail to D. Rankin [Accessed 6 July 2015].

Standring, S. 2005. *Gray's Anatomy*. 39th ed. Spain: Elsevier Churchill Livingstone.

Stupar, M., Mauron, D. and Peterson, C.K. 2003. Inter-examiner reliability of the diagnosis of cervical pillar hyperplasia (CPH) and the correlation between CPH and spinal degenerative joint disease (DJD). *BMC Musculoskeletal Disorders*; 4: 28-29

Taylor, J., Clopton, P., Bosch, E., Miller, K. and Marcellis, S. 1995. Interpretation of abnormal lumbosacral spine radiographs: a test comparing students, clinicians, radiology residents and radiologists in medicine and chiropractic. *Spine*; 20: 1147-1154.

Tins, B. and Cassar-Pullicino, V. 2004. Imaging of acute cervical spine injuries: review and outlook. *Clinical Radiology*; 59: 85-880.

Tudor, G.R. and Finlay, D.B. 2001. Error review: can this improve reporting performance. *Clinical Radiology*; 56: 751-754.

Tudor, G., Finlay, D. and Taub, N. 1997. An assessment of inter-observer agreement and accuracy when reporting plain radiographs. *Clinical Radiology*; 55: 235-238.

Vernon, H., Steiman, I. and Hagino, C. 1992. Cervicogenic dysfunction in muscle contraction headache and migraine - a descriptive study. *Journal of Manipulative Physiological Therapeutics*; 15: 418-429.

Vrtovec, T., Pernus, F. and Likar, B. 2009. A review of methods for quantitative evaluation of spinal curvature. *European Spine Journal*; 18: 1-15.

Wiegand, R., Kettner, W.M., Brahee, D. and Marquina, N. 2003. Cervical spine geometry correlated to cervical degenerative disease in a symptomatic group. *Journal of Manipulative and Physiological Therapeutics*; 26: 341-346.

Wilson, N. 2012. A literature review of the effect of loss of cervical lordosis on the spinal cord and nervous system. Senior research project. Logan College of Chiropractic.


Witsek, A.M. and Benzel, E.C. 2014. Obesity in cervical spine surgery. *World Neurology*; 82: 147-148.

Wood, B.P. 1999. Decision-making in radiology. *Radiology*; 211: 601-603.

Yukawa, Y., Kato, F. and Suda, K. 2012. Age-related changes in osseous anatomy, alignment, and range of motion of the cervical spine. Part I: radiographic data from over 1,200 asymptomatic subjects. *European Spine Journal*; 21:1492-1428.

Yochum, T.R. and Rowe, L.J. 2005. *Essentials of Skeletal Radiology*. 3rd ed. Philadelphia: Lippincott Williams & Wilkins.

APPENDIX A



Institutional Research Ethics Committee
Faculty of Health Sciences
Room MS 49, Mansfield School Site
Gate 8, Ritson Campus
Durban University of Technology

P O Box 1334, Durban, South Africa, 4001

Tel: 031 373 2900
Fax: 031 373 2407
Email: lavishad@dut.ac.za
http://www.dut.ac.za/research/institutional_research_ethics

www.dut.ac.za

28 November 2014

IREC Reference Number: **REC 82/14**

Mr D M Rankin
16 Raleigh Road
Woodside
Westville

Dear Mr Rankin

The intra and inter examiner reliability of the radiographic assessment of the cervical lordosis

I am pleased to inform you that Full Approval has been granted to your proposal REC 82/14.


The Proposal has been allocated the following Ethical Clearance number **IREC 087/14**. Please use this number in all communication with this office.

Approval has been granted for a period of one year, before the expiry of which you are required to apply for safety monitoring and annual recertification. Please use the Safety Monitoring and Annual Recertification Report form which can be found in the Standard Operating Procedures [SOP's] of the IREC. This form must be submitted to the IREC at least 3 months before the ethics approval for the study expires.

Any adverse events [serious or minor] which occur in connection with this study and/or which may alter its ethical consideration must be reported to the IREC according to the IREC SOP's. In addition, you will be responsible to ensure gatekeeper permission.

Please note that any deviations from the approved proposal require the approval of the IREC as outlined in the IREC SOP's.

Yours Sincerely



Professor J K Adam
Chairperson: IREC

APPENDIX B

Dear Dr. A. Docrat
HoD: Department of Chiropractic

November 2014

I, Dave Rankin (20718722) do hereby request permission to utilize the portable radiographic viewing box and the selected radiographs in the department toward the completion of my Masters dissertation.

The provisional title of my study is, "The intra and inter examiner reliability of the radiographic assessment of the cervical lordosis."

The viewing box will be utilised off campus by 3 research participants. Great care will be taken into protecting the viewing box from all possible damage, for which I will take responsibility for if any incurs.


The selected cervical spine radiographs were taken by Dr. A Roopnarian (2011) for the completion of his study.

The portable radiographic viewing box to be utilised (*Asset No.78026*) is requested from the 20th November to the 01 March 2014.

I look forward to your favourable response.
Kind Regards




Dave Rankin
Research student
082 292 9921



Dr Junaid Shaik
Research supervisor

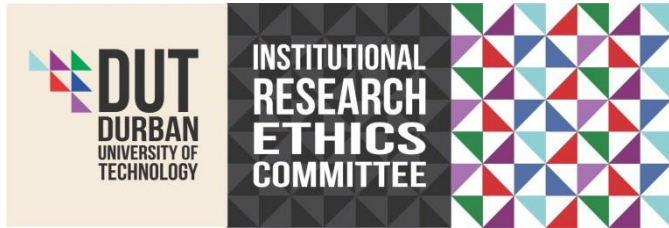I, Dr. A Docrat (Head of Chiropractic Program) do hereby grant permission for Dave Rankin, Student No. 20718722, to utilize the portable radiographic viewing box (*Asset No.78026*) and selected radiographs required for the duration of his Masters Dissertation.

Upon completion of his study, Mr D. Rankin is to return the radiographs to the Chiropractic Day Clinic for storage.



Dr. A. Docrat
Head of Chiropractic Program

APPENDIX C



Letter of information and consent

Title of the Research Study: The intra- and inter-examiner reliability of the radiographic assessment of the cervical lordosis.

Principal Investigator/s/researcher: Dave Rankin (BTech: Chiropractic)

Co-Investigator/s/supervisor/s: Dr. J. Shaik (MTech: Chiropractic)

Dear Examiner,

This letter will outline the research and purpose of my study. Should you have any questions please do not hesitate to enquire from me.

Brief Introduction and Purpose of the Study: The purpose of this study is to investigate the intra- and inter-examinable reliability of the radiographic assessment of the cervical lordosis of asymptomatic adult males.

Outline of the Procedures: Prior to commencement, a meeting will be held between the three examiners to discuss the research procedure. You, the examiners, are requested not to view your initial assessments when doing your second set of assessments. Please do not communicate with each other in any manner to discuss any aspect of your radiographic assessment or findings.

Each of you will be given 80 lateral plain film radiographs of the cervical spine of asymptomatic adult males between 18-45 years of age. These radiographs were taken of participants in a previous study and were already coded. Therefore, there is no way for you to identify to whom the radiographs belong.

Each of you will be given a maximum of two (2) weeks to complete the assessments. Please note that this time interval will be strictly followed as the research procedure needs to be standardized.

Step 1

The initial assessment of the cervical lordosis (CL) using the two methods described in the table below will be completed by Examiner 1 and captured on a Excel spread sheet. This will be labelled as "First CL Assessments Examiner 1" and you will need to email this to the supervisor of this research (junaid@dut.ac.za).

Step 2

I will then collect the radiographs, viewing box and instruments from Examiner 1. My supervisor will then erase any markings on the radiographs. I will then transport the radiographs, viewing box and instruments to Examiner 2 for the first set of assessments which need to be captured on an Excel spread sheet by you and then emailed to the supervisor labelled "First CL Assessments Examiner 2".

Step 3

I will then collect the radiographs, viewing box and instruments from Examiner 2. My supervisor will then erase any markings on the radiographs. I will then complete my set of assessments of the CL which will be captured on an Excel spread sheet and emailed to the supervisor labelled "First CL Assessments Examiner 3".

Step 4

The radiographs will then be handed to my supervisor to erase any markings left on the radiographs. I will then transport the radiographs, viewing box and instruments to Examiner 1 for the second set of assessments which need to be captured on an Excel spread sheet and emailed to my supervisor labelled "Second CL Assessments Examiner 1".

Step 5

I will then collect the radiographs, viewing box and instruments from Examiner 1. My supervisor will then erase any markings on the radiographs. I will then transport the radiographs, viewing box and instruments to Examiner 2 for the second set of assessments which need to be captured on an Excel spread sheet and emailed to my supervisor labelled "Second CL Assessments Examiner 2".

Step 6

I will then collect the radiographs, viewing box and instruments from Examiner 2. My supervisor will then erase any markings on the radiographs. I will then complete the second set of assessments which will be captured on an Excel spread sheet and emailed to my supervisor labelled "Second CL Assessments Examiner 3".

Table: The modified Cobb Methods for evaluating the cervical lordosis to be utilised in this study

Reference	Method	Description
Harrison et al. (2000)	Modified Cobb method (C1-C7)	A line will be drawn through and parallel to the inferior endplate of C7 and another will be drawn through the midpoints of the anterior and posterior tubercles of the atlas. Perpendiculars will be constructed to the point of intersection and the resultant angle will then be measured.
Harrison et al. (2000)	Modified Cobb method (C2-C7)	A line will be constructed through and parallel to the inferior endplate of C7 and another will be drawn through and parallel to the inferior endplate of C2. Perpendiculars will be constructed to the point of intersection and the resultant angle will then be measured.

INSTRUMENTS

The following instruments and measuring tools will be utilized in this study:

- Portable x-ray viewing box with good lighting (The same viewing box will be utilized throughout the study to reduce variation in lighting).

- A 30cm ruler
- Protractor (for measurement of angles)
- Staedtler® white eraser (to remove lines drawn on the plain film radiographs)
- A HB clutch pencil (this will be used to mark the angles and lines on the plain film radiographs)

All examiners will utilize the same viewing box and set of instruments to minimize measurement error.

Risks or Discomforts to the Participant: there are no risk to you, the examiner, for participating in my study. You may, however, be tired when evaluating the radiographs. You are, therefore, advised to complete the assessments when you are refreshed.

Reason/s why the Participant May Be Withdrawn from the Study: There will be no adverse consequences for you should you choose to withdraw from the research at any time.

Remuneration: Each of you will be financially compensated for your time and effort. You will receive R 1000.00 after the completion of all your assessments.

Persons to Contact in the Event of Any Problems or Queries:

Please contact the researcher 082 292 9921, my supervisor junaids@dut.ac.za or the Institutional Research Ethics administrator on 031 373 2900. Complaints can be reported to the DVC: TIP, Prof F. Otieno on 031 373 2382

