

Peer reviewed ORIGINAL ARTICLE

THE CHARACTERISTICS AND OUTCOMES OF PATIENTS UNDERGOING PERCUTANEOUS BALLOON PULMONARY VALVULOPLASTY IN THE PAEDIATRIC POPULATION

JK Adam¹ (PhD Clinical Technology) | S Govender² (B Clinical Technology) | EGM Hoosen² (FCP SA Cardiology)
A Amod² (B Clinical Technology) | WNS Rmaih¹ (MSc)

¹Department of Biomedical and Clinical Technology, Faculty of Health Sciences, Durban University of Technology

²Department of Paediatric Cardiology, Inkosi Albert Luthuli Central Hospital (IALCH), Durban, South Africa.

Corresponding author: Prof JK Adam | tel: +27 (31) 373 5291 | fax: +27 (31) 373 5295/5524 | email: adamjk@dut.ac.za

ABSTRACT

Background The immediate results along with short term and medium term results of percutaneous balloon pulmonary valvuloplasty (PBPV) for the treatment of pulmonary stenosis (PS) have been well documented in literature. On the other hand the results on long term follow up are few.

The purpose of this study was to document the immediate, short and long term results of PBPV and, to analyse the characteristics and outcomes of patients who have undergone PBPV at Inkosi Albert Luthuli Central Hospital (IALCH) Department of Paediatric Cardiology in Durban South Africa.

Methods The study comprised of 30 patients (20 females/67%, 10 males/33%) with isolated congenital pulmonary stenosis who underwent PBPV from June 2005 to June 2012. Their age ranged from 23 days to 11 years. Patients underwent clinical examination, angiography (Pre and post PBPV) and echocardiography on the day after the procedure, at 6 months and at one year. The difference in clinical examination and diagnostic findings were described over the above three time periods.

Results The results were categorized as "excellent" when the Peak Transvalvular systolic gradient (PTSG) was reduced by more than 50mmHg after the procedure, "good" when the PTSG was reduced by 25-50mmHg and "poor" when the PTSG was less than 25mmHg.

The mean pre PBPV pullback systolic pressure between the main Pulmonary Artery (MPA) to right ventricular outflow tract (RVOT) was 20.2±7.60 mmHg to 78.1±27.78 mmHg. The mean pre PBPV systolic pullback pressure gradient between the MPA to RVOT was 60.03±32.10. The mean post PBPV pullback systolic pressure between the MPA to RVOT was 20.13±8.22 mmHg to 48.13±24.47 mmHg. The mean post PBPV pullback systolic pressure gradient between the MPA to RVOT was 28.73±23.21

The mean±SD initial echocardiographic gradient was 110.1±35.58 mmHg. The mean±SD echocardiographic gradient the day after PBPV was 54.37±26.53 mmHg (excellent), the mean±SD echocardiographic gradient at the 6 months follow-up was 54.9±28.10 mmHg (excellent) and the mean±SD echocardiographic gradient at the one year follow-up was 53.2±32.27 mmHg (excellent).

Patients with Mild Pulmonary stenosis 9/30(30%) showed mean±SD reduction in the gradient between pre-procedure echocardiographic findings and at one year follow-up by 41.30±20.10 mmHg (good). Patients with moderate pulmonary stenosis 9/30(30%) showed post PBPV with a mean±SD reduction in the gradient between pre-echo and at the one year follow-up by 70.92±24.90 mmHg (excellent). Patients who presented with severe pulmonary stenosis [12/30(40%)] showed a mean±SD reduction in the gradient between pre-echo and at the one year follow-up by 81.21±35.85 mmHg (excellent).

Procedural complications included pulmonary regurgitation occurring in 16/30(53%) of patients and tear of a leaflet occurring in one patient 1/30(4%). The remaining 13/30(43 %) presented with no procedural complications.

Conclusion In this study Percutaneous Balloon Pulmonary Valvuloplasty as a treatment option of pulmonary stenosis in children showed excellent immediate, short and long term results.

KEYWORDS

Pulmonary Stenosis; Percutaneous Balloon Pulmonary Valvuloplasty.

INTRODUCTION

Because the pulmonary valve is the least likely valve to be affected by acquired heart disease, virtually all cases of pulmonary valve stenosis are congenital in origin. Most patients with stenosis have a conical or dome-shaped pulmonary valve formed by fusion of the valve leaflets. Occasionally, the valve may be thickened and dysplastic, with the stenosis caused by inability of the valve leaflets to separate sufficiently during ventricular systole.^[1]

Pulmonary valve stenosis in neonates, early infancy and childhood is a life-threatening condition. It comprises 8-12% of all

congenital heart defects in children.^[2] Mortality and morbidity is related to the severity of the valvular stenosis. Severe pulmonary stenosis is usually associated with reduced pulmonary flow, right ventricular hypertrophy and cyanosis, and with critical obstruction early congestive heart failure. The age of the patients at presentation is related to the severity of the obstruction. Patients who present with severe pulmonary stenosis are usually found during the neonatal and infancy period. Patients who have a mild obstruction usually present during childhood and may be asymptomatic.^[2]

Echocardiography is the most important non-invasive test to detect and evaluate pulmonary valve stenosis. The echocardi-

gram accurately documents an obstruction present at the valve and Doppler studies are used to estimate the degree of obstruction. The transducer is applied at standard locations directly on the chest wall to enable multiple views from parasternal, apical, sub-costal, suprasternal views.^[3]

A thickened pulmonary valve with restricted systolic motion (doming) in the parasternal short axis and subcostal views is shown.^[4] Multiple views as mentioned above are used to confirm the absence of coexistent congenital cardiac disease. Dilatation of the main pulmonary artery distal to the stenotic orifice commonly occurs. Markedly thickened, nodular, and immobile pulmonary valve leaflets may be recognized easily and suggest dysplastic pulmonary valves. The pulmonary valve annulus can also be visualized and measured. Measurements can be compared with normal values to determine if the annulus is hypoplastic. Such measurements are also useful in selecting the diameter of the balloon to be used during balloon valvuloplasty. Pulsed, continuous-wave (or high-frequency pulsed), and colour Doppler evaluation, in conjunction with 2-dimensional echocardiography, is most useful in confirming the clinical diagnosis and in quantitating the degree of obstruction.^[5]

Doppler studies can be used to accurately determine the velocity of flow at single or multiple levels, which then can be converted to reproducible pressure gradients by applying the modified Bernoulli equation, as follows: pressure gradient (in millimeters of mercury) = $4 \times (\text{velocity in meters/second})^2$. The use of several views and measurements increases the accuracy of the predicted gradient of peak systolic pressure.^[6]

The traditional method of treatment for this Pulmonary Stenosis was surgical valvotomy up to 1982, when Kan *et al.*^[7] introduced the technique of percutaneous balloon pulmonary valvuloplasty (PBPV). The short and mid-term results of PBPV have been so satisfactory that it has become the preferred method of therapy for pulmonary stenosis in both children and adults.^[8]

Cardiac catheterization is not indicated in mild pulmonary stenosis but is essential in severe stenosis and is an integral part of balloon pulmonary valvuloplasty. This procedure is used to confirm the diagnosis; to discern the degree of obstruction; to assess the morphology of the right ventricle, pulmonary outflow tract, and pulmonary arteries; and to exclude other associated cardiac abnormalities. It is also used to measure the pulmonary annulus to determine the diameter and length of the balloon to be used in the PBPV.^[6]

The aim of this study was to determine, in the South African clinical practice context, the clinical effectiveness and patient safety of percutaneous balloon pulmonary valvuloplasty for pulmonary stenosis.

METHODS

This was a retrospective study of 30 patients who underwent PBPV from June 2005 to June 2012, and met the inclusion criteria of the study.

The pulmonary stenosis was diagnosed by physical examination, electrocardiogram (ECG) and echocardiography. Once pulmonary stenosis was confirmed, the patient underwent cardiac catheterization PBPV if its criteria were met.

Inclusion criteria for the study included patients aged from birth to 12 years presenting with significant pulmonary valve stenosis as determined by physical examination and echocardiography that had undergone balloon pulmonary valvuloplasty for the reporting period.

Patients with any other associated congenital anomalies were excluded.

The Siemens Acuson Sequoia 512[®] echocardiography machine was used in the study. The transducer was applied at standard specific locations directly on the chest wall. These locations are parasternal, apical, sub-costal, suprasternal, so that many different views of the heart may be obtained. Pulmonary stenosis and the follow up evaluation after the balloon valvuloplasty, was diagnosed using echocardiography.

Colour Doppler was useful for the detection and quantification of pulmonary regurgitation, by measuring the jet length and planimetered jet area.

The following data was recorded for every patient included in the study: age, gender, height, weight, body surface area, annular size (mm), balloon diameter (mm), balloon length (cm), initial Echocardiography to measure the gradient across the valve, pre PBPV Right Ventricular systolic pressure, pre PBPV pullback systolic pressure gradient from the main Pulmonary Artery (MPA) to right ventricular outflow tract (RVOT), post PBPV Right Ventricular systolic pressure, post PBPV pullback systolic pressure gradient from the MPA to RVOT, Echocardiography to measure the gradient across the valve on day after PBPV, Echocardiography to measure the gradient across the valve 6 months after PBPV, Echocardiography to measure the gradient across the valve one year after PBPV, procedural success and procedure complications.

During cardiac catheterization the vascular access of the femoral vein was accessed percutaneously using the seldinger technique. And a 3-5F sheath with a diaphragm was introduced into the vein. All pressures and saturations were obtained and cardiac calculations were performed. The Axiom Sensis was used for haemodynamic monitoring and measuring of pressures and the GEM 4000 Premier analyzer was used for blood gas analysis. The ANGIOMAT ILLUMENA digital injector system was used for angiography.

After the baseline haemodynamic measurements and angiography was obtained in biplane projections using the angiomat illumena, the pulmonary valve was crossed with an angiographic catheter and a pullback was done to document the peak to peak gradient across the pulmonary valve. A end-holed catheter was placed in the Right Ventricular Outflow Tract (RVOT) with the left anterior oblique (LAO) view of 17° and with cranial angulation of 15°, and LAO 90°, angiography was then performed (1 cc/kg over one second) to measure the pulmonary valve annulus and assess the right ventricle morphology and valve anatomy. Lateral projection provided optimal images of the valve hinge point with minimal foreshortening. A catheter was manipulated into the right ventricle with its tip directed towards the RVOT.

The pulmonary valve was then crossed and the catheter was positioned in the left or right lower branch of either the right or left pulmonary artery. A balance middle weight (BMW) wire was placed in the peripheral pulmonary artery and the catheter was replaced with a coronary angioplasty balloon. The balloon was centred across the valve annulus in the lateral view and was rapidly inflated by hand. This was then removed and replaced with the Tyshak Balloon which was then passed over the wire and was inflated over the valve.

Rapidly inflating by hand with diluted contrast (75/25 of saline and contrast medium), patient monitoring is essential during this time, until the disappearance of the 'waist' in the balloon. An average of four inflations may be necessary for a successful result. The balloon is then removed while keeping the guide wire in the pulmonary artery. Constant suction on the attached syringe and counter clockwise rotation are important to deliver the deflated balloon.

The balloon size was determined according to the maximum internal diameter of the pulmonary valve from hinge point to hinge point during systole measured in the lateral view of the right ventricle angiogram and is corrected and calibrated for the magnification. The balloon diameter to pulmonary valve annulus ratio used in this study was 1:2.

The overall success of the closure, immediately and one day after the procedure would be measured by a reduction in the peak and mean gradient across the pulmonary valve, while overall failure of the procedure would be measured by failure to reduce the gradient across the valve. Overall success of the balloon valvuloplasty at six months and one year would be measured by no increase of the peak and mean gradient.

Continuous variables were expressed as mean±SD. The frequency distribution and percent frequency distributions were used to organize the data results.

RESULTS

In this study the female to male ratio was 2:1 = (67%/33%). Table 1 represents mean values +/- SD of patients' characteristics.

On initial echocardiography, of the 30 patients 9/30 (30%) presented with mild pulmonary stenosis, 9/30 (30%) presented with moderate pulmonary stenosis and 12/30 (40%) presented with severe pulmonary stenosis (Figure 1).

The mean initial echocardiographic gradient was 110.1±35.58 mmHg. The mean echocardiographic gradient the day after PBPV was 54.37±26.53 mmHg, the mean echocardiographic gradient at the 6 months follow-up was 54.9±28.10 mmHg and the mean echocardiographic gradient at the one year follow-up was 53.2±32.27 mmHg.

The mean pre PBPV right ventricular systolic pressure was 83.1±31.6 mmHg, while the mean post PBPV right ventricular systolic pressure was 49.33±24.59 mmHg, showing immediate reduction in the RVSP.

The immediate post procedural haemodynamic results showed that 9/30 (30%) patients had excellent improvement in right ventricular function (reduction of the right ventricle systolic pressure by >50mmHg), 11/30 (37%) patients showed good improvement in right ventricular function (reduction of right ventricular systolic pressure by 25-50 mmHg) (this implies 67% overall improvement in RV function) while 10/30 (33%) of patients showed no improvement in right ventricle function (a reduction of right ventricular pressure by 25mmHg or less).

The nine out of thirty patients who showed an excellent improvement in right ventricular function had a mean pre PBPV right ventricular systolic pressure of 115.7±37.4 mmHg and a mean post PBPV right ventricular systolic pressure of 51.1±36.6 mmHg.

Table 1: Characteristics of Patients with Pulmonary Stenosis.

Variables	Patients (n=30) (mean ± SD or %)
Age (months)	52.8±45
Gender	
Males (n=10)	33%
Females (n=20)	67%
Body weight (kg)	16.13±11.01
Height (cm)	94.23±29.74
BSA	0.63±0.32
Symptomatic	85%
Asymptomatic	15%
RVH	78%
RBBB/RAD	13%

BSA: Body surface area
 RVH: Right Ventricular hypertrophy
 RBBB/RAD: Right Bundle Branch Block/ Right Axis Deviation

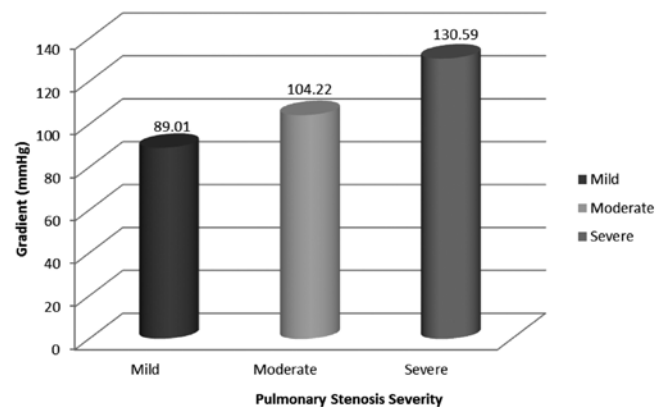


Figure 1: Mean Initial echo gradients for mild, moderate and severe pulmonary stenosis.

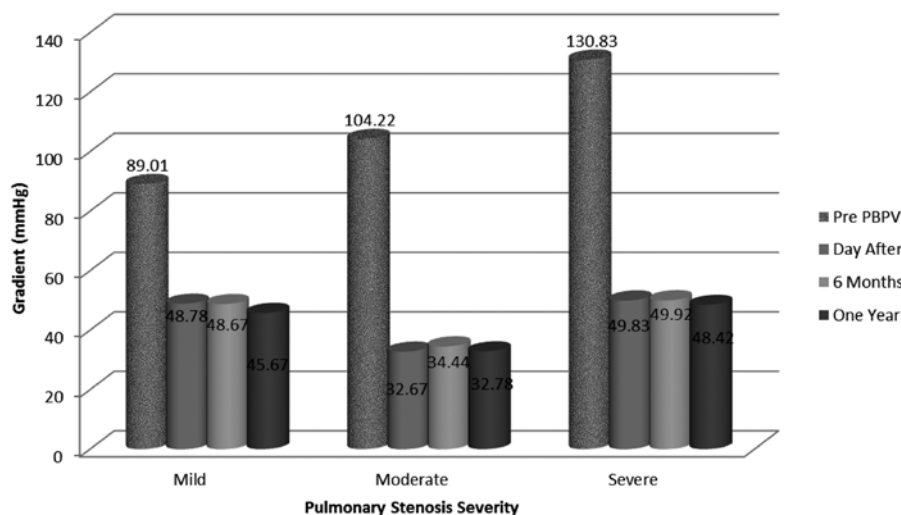


Figure 2: Mean Echocardiographic Evaluation of severity of pulmonary stenosis at Pre PBPV, Day After, at 6 Months and at One Year.

The eleven out of thirty patients who showed a good improvement in right ventricular function had a mean pre PBPV right ventricular systolic pressure of 73.5±10.8 mmHg and a mean post PBPV right ventricular systolic pressure of 37.1±7.6 mmHg.

The ten out of thirty patients who showed little or no improvement in right ventricular function had a mean pre PBPV right ventricular systolic pressure of 64.4±16.5 mmHg and a mean post PBPV right ventricular systolic pressure of 61.3±18.6 mmHg.

The mean balloon diameter was 13.13±4.33 mm while the mean balloon length was 5.23±2.23 cm.

Figure 2 illustrates that patients with Mild Pulmonary stenosis 9/30 (30%) showed mean±SD reduction in the gradient between pre-procedure echocardiographic findings and at one year follow-up by 41.30±20.10 mmHg (good). Patients with moderate pulmonary stenosis 9/30 (30%) showed post PBPV with a mean±SD reduction in the gradient between pre-echo and at the one year follow-up by 70.92±24.90 mmHg (excellent). Patients who presented with severe pulmonary stenosis [12/30 (40%)] showed a mean±SD reduction in the gradient between pre-echo and at the one year follow-up by 81.21±35.85 mmHg (excellent).

The pullback gradient is derived from the peak to peak transvalvular systolic gradient that occurs from the pulmonary artery to the right ventricle. The pullback gradient is expected to decrease after the PBPV, as the procedure aims to reduce the stenosis, therefore reducing the gradient. If the gradient is reduced >50 mmHg it is considered to be successful and an excellent result. If the gradient is reduced by between 50-25 mmHg it is considered a good result and if the gradient is reduced by <25 mmHg it is considered a poor result.

The mean±SD pre PBPV pullback systolic pressure between the main pulmonary artery (MPA) to right ventricular outflow tract (RVOT) was 20.2±7.60 mmHg to 78.1±27.78 mmHg. The mean±SD pre PBPV systolic pullback pressure gradient between the MPA to RVOT was 60.03±32.10. The mean±SD post PBPV pullback systolic pressure between the MPA to RVOT was 20.13±8.22 mmHg to 48.13±24.47 mmHg. The mean±SD post PBPV pullback systolic pressure gradient between the MPA to RVOT was 28.73±23.21. Therefore showing the immediate reduction in the pulmonary artery systolic pressure (PASP), RVOT systolic pressure and gradient post PBPV.

Figure 3 illustrates the mean pullback pressure gradient between the main pulmonary artery (MPA) and right ventricular outflow tract (RVOT) pre and post PBPV. In patients with mild stenosis the average pullback gradient decreased by 9.56±2.34 mmHg which is considered a poor result. With moderate stenosis, the average pullback gradient decreased by 26.10±13.24 mmHg (considered a good result). In patients who presented with severe stenosis, the average pullback gradient decreased by 60.08±24.30 mmHg (considered to be an excellent result).

The main complications that arose in the immediate post PBPV period were mild pulmonary regurgitation occurring in 10/30 (33%) of patients, moderate pulmonary regurgitation occurring in 3/30 (10%) and severe pulmonary stenosis occurring in 3/30 (10%). This complication arose immediately after the procedure. It improved, remained the same or had become worse over the closely monitored follow up period which comprised of the day

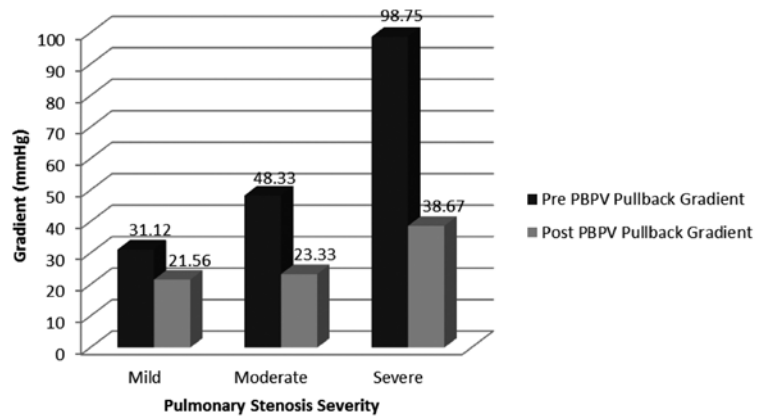


Figure 3: The Mean Pullback pressure gradient between the MPA and RVOT pre and post PBPV for mild, moderate and severe pulmonary stenosis.

MPA: Main Pulmonary Artery
RVOT: Right Ventricular Outflow Tract

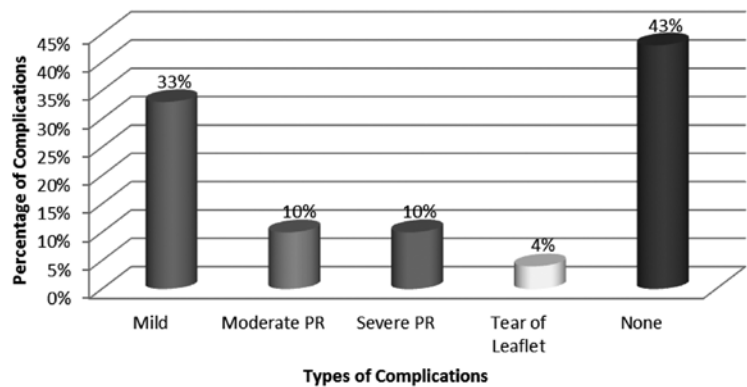


Figure 4: Post procedural complications.
PR: Pulmonary regurgitation

after procedure check-up, 6 months and one year follow ups.

The other complications occurred in the catheterization laboratory during the procedure, such as tear of leaflets which occurred in 1/30 (4%) and arrhythmias which occurred in 1/30 (4%) of the patients. Thirteen out of thirty (43%) patients presented with no complications (Figure 4).

DISCUSSION

In this study immediate successful outcomes of PBPV was reported in 20/30 (70%) of cases. These results are consistent with a previous study by Moura *et al.*^[9] It was also documented at the 6-month and at the one-year follow-up that the procedure was effective in 23/30 (77%) of cases. This could be due to the possible regression of dynamic infundibular stenosis during the day after the procedure in patients with suboptimal immediate results following the PBPV.

The mean pulmonary annulus diameter increased significantly after the PBPV during the follow-up period indicating growth of the right ventricle. These results are consistent with Kovalchin *et al.*^[10] who reported that the pulmonary valve annulus increased in size after PBPV in patients with pulmonary stenosis at a rate that paralleled or exceeded the rate of somatic growth.

Seven out of thirty (23%) of the patients did not show any improvement, however, no restenosis occurred as suggested by Rao *et al.*^[11] who found that 11% of pulmonary stenosis patients who underwent PBPV had restenosis at sometimes in their first 2 years post procedure.

Complications were few and not life threatening and that may be due to the correct balloon size used in the procedure.^{11,12}

The limitation of the study is the sample size limitation in proving effect size and power. Through the descriptive analysis, however, the difference is consistently documented.

CONCLUSION

It is evident from this study that there was immediate overall success of the PBPV procedure to treat pulmonary stenosis in children since there was significant reduction in the gradient and no restenosis immediately, the day after, at 6 months and at one year follow-up.

Complications of the procedure were few and not life-threatening.

REFERENCES

1. Koretzky E, Moller J, Kornis M, et al. Congenital pulmonary stenosis resulting from dysplasia of valve. *Circulation*, 1969; 40(1):43-53.
2. Handoka N.,El-Eraky A. Predictors of Successful Pulmonary Valvuloplasty in Infants with Severe Pulmonary Valve Stenosis. *Heart Mirror Journal*, 2007; 1(2):68-74.
3. Oh J, Seward J, Tajik A, (2006) Echo Manual from Mayo Clinic. Philadelphia: Lippincott, William & Wilkins.
4. Weyman A, Hurwitz R, Girod D, Dillon J, Feigenbaum H, Green D. Cross-sectional echocardiographic visualization of the stenotic pulmonary valve. *Circulation*. Nov 1977; 56(5):769-74.
5. Rao P. Doppler ultrasound in the prediction of transvalvar pressure gradients in patients with valvar pulmonary stenosis. *Int J Cardiol*. May 1987; 15(2):195-203.
6. Rao P, Berger S et al. Valvular Pulmonary Stenosis. (online), Available from: <http://emedicine.medscape.com/article/891729-overview> [Accessed: June 30 2012].
7. Kan J, White R Jr, Mitchell S, et al. Percutaneous balloon valvuloplasty: A new method for treating congenital pulmonary-valve stenosis. *N Engl J Med*, 1982; 307(9):540-2.
8. Shrivastava S.Kumar R.,Dev V. et al. Determinants of immediate and follow-up results of pulmonary balloon valvuloplasty. *Clin Cardiol*, 1993;16(6):497-502
9. Moura C, Carrico A, Baptista MJ, et al. Balloon pulmonary valvotomy performed in the first year of life. *Rev Port Cardiol*, 2004; 23(1):55-63.
10. Kolvachin JP, Forbes TJ, Nihill MR, et al. Echocardiographic determinants of clinical course in infants with critical and severe pulmonary valve stenosis. *J Am Cardiol*, 1997; 29(5):1095-101.
11. Rao PS, Galal O. Patnana M, et al. Results of three to 10 year follow-up of balloon dilatation of the pulmonary valve. *Heart*, 1998; 80(6):591-5.
12. Berman W, Fripp R, Raisher B Yabek SM. Significant pulmonary valve incompetence following oversize balloon pulmonary valvuloplasty in small infants: A long-term follow-up study. *Catheter Cardiovasc Interv.*, 1999; 48(1):61-5; discussion 66.