



The effectiveness of lemon and sandalwood essential oils in the treatment of post inflammatory facial pigmentation in African females aged 18-35 years

Submitted in fulfilment of the requirements for the degree of Master of Health Sciences:
Somatology in the Faculty of Health Sciences at

The Durban University of Technology

APPROVED FOR FINAL EXAMINATION

Ronell Naidoo

November 2019

Supervisor: Mrs D Borg

Co-supervisor: Dr N Govender

Signature:

Signature:

PREFACE

This study represents original work by the author and has not been submitted in any other form to another university. Where use was made of the work of others, it has been duly acknowledged in the text.

The research described in this dissertation was carried out in the Department of Somatology, Faculty of Health Sciences Durban University of Technology Durban, South Africa under the supervision and co-supervision of Mrs D Borg and Dr N. Govender

Mrs R Naidoo

Mrs D Borg
(Supervisor)

Dr N Govender
(Co-supervisor)

DECLARATION OF AUTHORSHIP

I, Mrs Ronell Naidoo, hereby declare the content of this research project is my own unaided original work, except where specific indication is given to the contrary (by reference). To the best of my knowledge and belief, this thesis has not been submitted to any other institution as part of an academic qualification and contains no material previously published or written by any other person except where due reference is made.

Mrs Ronell Naidoo

Student number: 20807147

Date: 29 November 2019

DEDICATION

I wish to dedicate this piece of work in its entirety to my first-born Zaiden Samuel Naidoo.

My little boy, your contagious smile lights up our lives. I am, and will always be, your biggest supporter. You have changed our lives for the better

To my loving husband and parents, your spiritual guidance, support and encouragement to always progress is greatly valued

To my Lord and Saviour Jesus Christ, this study would not have been possible without your faithfulness and grace

“Commit to the Lord whatever you do, and he will establish your plans.”

Proverbs 16:3

ACKNOWLEDGEMENTS

I would like to express my sincere gratitude to:

- My Supervisors: Dr Govender and Mrs Borg for their continuous guidance and unfailing support throughout this study.
- My heart-felt thanks to my husband (Riza) and son (Zaiden) for their continual support, patience, love and encouragement.
- My parents, Pastors Cyril and Shanthie Ganesh for their constant encouragement.
- To my family and friends for their support and encouragement throughout the write up of this dissertation.
- Professor Matthews for statistical assistance.
- Professor Mosam for diagnostic assistance.
- Dr Steele for meticulous editing and proof reading.
- Participants that have participated in the study.
- Environ Distribution for the generosity in sponsoring aqueous cream used in the study.
- Upfront Distribution for their donation of product during the study.
- The Durban University of Technology for financial assistance.

ABSTRACT

Introduction: Post inflammatory pigmentation (PIH) is a common dermatologic disorder globally. It is most prominent in darker skinned woman of childbearing age. PIH affects the physical and physiological features of the sufferer, altering their quality of life. The high costs and safety of treatment options available for PIH are questionable, thus creating an interest in the effects of natural remedies on PIH.

Aim: The study aimed to evaluate the effects of lemon and sandalwood essential oils on PIH present in African females aged 18-35 years.

Objective: The study objective was to determine the progression of PIH using sandalwood and lemon essential oils and a placebo treatment by means of a Skin Analyser[®] machine. Comparisons were made between the oils to determine their effectiveness in the treatment of PIH.

Methodology: This was a prospective, quantitative and double-blinded study with an experimental design, conducted at the Durban University of Technology. Participants were black female students, 18-35 years, with a sample size of 48. Participants were randomly assigned to experimental and control groups. A pre-test post-test method was used and follow up consultations took place at baseline 0 weeks and thereafter at 8, 16 and 24 weeks.

Results: The majority of participants were 18-22 years of age with 61.7% (n = 29) indicating the use of daily homecare treatments such as cleansers and moisturisers, while 54.3% (n = 25) reported a family history of pigmentation. Low-self-esteem was reported by 52% (n = 31), which is a concern. Improvements (facial spots, pore sizes, ultraviolet [UV] features) were noted in the skin as a result of treatment with both sandalwood and lemon oils. Significant results were demonstrated by sandalwood oil across key skin parameters (facial spot, pore sizes, UV features)

Discussion: The prevalence of common factors that influence the onset of PIH such as age, race and increased hormonal factors are high within this cohort, endorsing their susceptibility to PIH development. Our data also highlights waxing as the preferred hair removal method. However, waxing predisposes women to inflammation, blockage of pores and burns, leading to PIH.

Therefore, the increased incidence of pigmentation in our study may be associated with the higher usage of waxing. Overall, visible improvements were demonstrated in the skin for both oils. We observed significant physiological changes in the pore sizes as a result of both oils, as well as improved pore conditions with fewer enlarged and blocked pores. Thus, both groups showed a reduction in the prevalence of acne. Our data thus suggests that both oils may have a potential role in decreasing the development of acne and PIH.

TABLE OF CONTENTS

PREFACE.....	ii
DECLARATION OF AUTHORSHIP.....	iii
DEDICATION.....	iv
ACKNOWLEDGEMENTS.....	v
ABSTRACT.....	vi
TABLE OF CONTENTS.....	viii
LIST OF FIGURES	xi
LIST OF TABLES.....	xii
LIST OF APPENDICES.....	xiii
ABBREVIATIONS AND ACRONYMS	xiv
DEFINITION OF TERMS	xv
CHAPTER 1: INTRODUCTION	1
1.1 BACKGROUND.....	1
1.2 RESEARCH AIM AND OBJECTIVES	3
1.2.1 Aim.....	3
1.2.2 Research objectives	3
CHAPTER 2: LITERATURE REVIEW	4
2.1 Anatomy of the integumentary system.....	4
2.1.1 Cellular features of the epidermis	6
2.1.1.1 Keratinocytes	6
2.1.1.2 Merkel cells.....	7
2.1.1.3 Langerhans cells.....	7
2.1.1.4 Melanocytes	7
2.2 Melanin.....	8
2.2.1 Melanogenesis.....	9
2.3 PIGMENTARY SKIN DISORDERS	9
2.3.1 Melasma	10
2.3.2 Post-Inflammatory hyperpigmentation	11
2.3.2.1 Pathophysiology and aetiology of PIH	11

2.3.2.2	The PIH process	12
2.3.2.3	Acne in PIH development.....	13
2.4	Hyperkeratinisation	14
2.5	Treatment options for PIH.....	15
2.5.1	Lasers	15
2.5.2	Hydroquinone.....	16
2.6	Natural remedies for PIH.....	17
2.6.1	Essential oils.....	19
2.6.2	Lemon essential oil (<i>Citrus limon</i>).....	21
2.6.3	Sandalwood essential oil (<i>Santalum album</i>)	21
2.6.4	Role of lemon and sandalwood oils in pigmentation	22
CHAPTER 3: MATERIALS AND METHODS		23
3.1	Ethical considerations.....	23
3.2	Study design and setting	23
3.2.1	Inclusion criteria.....	23
3.2.2	Exclusion criteria.....	24
3.3	Study Sampling and recruitment	24
3.4	DATA COLLECTION	25
3.4.1	Allergy testing	25
3.4.2	Allocation of experimental products and essential oil blends.....	26
3.4.3	Assessment of skin parameters	27
3.5	Data analysis.....	27
CHAPTER 4: RESULTS.....		28
4.1	Demographics and lifestyle characteristics	28
4.2	Bivariate analysis between skin parameters, skincare regimen and family history of PIH.....	29
4.3	Photographic evidence.....	31
4.3.1	Lemon treatment group	31
4.3.2	Control group	32
4.3.3	Sandalwood treatment group.....	32
4.4	Descriptive analyses of the skin parameters.....	33
4.5	Effect of lemon and sandalwood essential oil on skin parameters	34
4.6	Changes in skin parameters over time among all groups	36

CHAPTER 5: DISCUSSION.....	39
5.1 Demographic and lifestyle characteristics.....	39
5.2 Acne and sunburn as common PIH contributors	43
5.2.1 Acne	43
5.2.2 Sunburn	44
5.3 The influence of Lemon and sandalwood oil on skin parameters	46
CHAPTER 6: CONCLUSION AND RECOMMENDATIONS	48
6.1 Conclusion.....	48
6.2 Limitations.....	49
6.3 Recommendations	49
LIST OF REFERENCES	51
APPENDICES	96

LIST OF FIGURES

Figure 2.1: Cellular layers of the epidermis.....	6
Figure 2.2: Difference in melanosome and melanocyte distribution among Africans, Asians and Europeans.....	9
Figure 2.3: Process of PIH formation in acne.....	12
Figure 2.4: The hyperkeratinisation process.....	14
Figure 2.5: Summary of the effects of lemon and sandalwood oil essential oil on PIH.....	22
Figure 4.1: (a) Image illustrating the facial appearance at baseline (0 weeks), (b) Image illustrating post treatment improvements with the visual characteristics of the skin in the lemon treatment group.	31
Figure 4.2: (c) Image illustrating the facial appearance at baseline (0 weeks), (d) Image illustrating post treatment improvements with the visual characteristics of the skin in the control (aqueous cream and SPF)	32
Figure 4.3: (e) Image illustrating the facial appearance at baseline (0 weeks), (f) Image illustrating post treatment improvements with the visual characteristics of the skin in the sandalwood treatment group	32
Figure 4.4: Graphs illustrating the changes in the percentages of the skin parameters over time in the treatment and control groups, (a) facial spot, (b) pore size, (c) skin roughness, (d) facial wrinkles, (e) UV acne, (f) UV spot, (g) UV moisture.....	38

LIST OF TABLES

Table 3.1: Skin parameters and indicators analysed by the Skin Analyser®	27
Table 4.1: Participant skin care management and family history (pigmentation)	30
Table 4.2: Evaluation of skin parameters at baseline (0 weeks) and post treatment (24 weeks) amongst those using the lemon treatment (n = 15)	33
Table 4.3: Evaluation of skin parameters at baseline (0 weeks) and post treatment (24 weeks) amongst those using the sandalwood treatment (n = 15)	34
Table 4.4: Effects of lemon and sandalwood essential oil on skin parameters.....	35

LIST OF APPENDICES

Appendix 1: IREC approval.....	96
Appendix 2: Request for permission to conduct research	97
Appendix 3: Letter of Information and Consent – English.....	98
Appendix 4: Letter of Information and Consent – isiZulu	100
Appendix 5: Consent form – English.....	102
Appendix 6: Consent form – isiZulu	103
Appendix 7: Advert – English	104
Appendix 8: Advert – isiZulu	105
Appendix 9: Questionnaire – English.....	106
Appendix 10: Questionnaire – isiZulu	111
Appendix 11: Agreement letter Prof. Mosam.....	117
Appendix 12: Basic treatment usage instructions.....	118
Appendix 13: Process of consultations	119
Appendix 14: Manuscript.....	120

ABBREVIATIONS AND ACRONYMS

With reference to this study the following abbreviations and acronyms apply:

EO	-	Essential oil
PIH	-	Post Inflammatory Hyperpigmentation
HQ	-	Hydroquinone
SEO	-	Sandalwood Essential oil
UV	-	Ultra Violet
UVA	-	Ultraviolet A
UVAB	-	Ultraviolet B
AV	-	Acne Vulgaris
<i>P. Acnes</i>	-	<i>Propionibacterium acnes</i>

DEFINITION OF TERMS

Acne: Acne vulgaris is a common pigmentary disorder of the pilosebaceous follicles affecting the face, chest, shoulders and back. It consists of comedones, papules, pustules, and nodules.

Cosmetics: These are scented preparations used to clean, soften skin and mask body odour and is linked to hygiene as its primary purpose. Cosmetics are used to enhance complexion, skin, hair, and nails.

Dermis: The dermis forms part of the integumentary system and is a fibrous elastic tissue that hosts vessels, nerves, and sensory receptors.

Epidermis: The epidermis is a superficial layer differentiated into multiple stratified squamous epithelium that is the first layer of the integumentary system. The basale, spinosum, granulosum, lucidum and corneum layers make up the epidermis.

Essential oils: These oils are extracted from roots, herbs, fruits and barks for use in various industries for their beneficial properties.

Hydroquinone: Hydroquinone (HQ) is a whitening agent known as 1,4 dihydroxybenzene and is considered the best treatment PIH

Hyperkeratinization: The hyperkeratinisation process occurs when the cells of the follicle become interconnected and do not shed normally onto the skin's surface, resulting in lesions characteristic of acne

Hypodermis: This is the last layer of the integumentary system containing adipose tissue, providing insulation to the skin.

Keratin: These are key fibrous structural proteins that make up hair, nails, and the outer layer of skin. Keratin is also the protein that protects epithelial cells from damage or stress.

Keratinocytes: Keratinocytes are building blocks of the epidermis, they function as an effective barrier against harmful elements.

Melanin: Melanin is responsible for pigmentation in skin, hair, and eyes. There are two types of melanin: eumelanin and pheomelanin.

Melanocytes: Melanocytes produce pigment located in the basal layer. Melanocytes are responsible for increased epidermal pigmentation

Pigmentary disorders: These disorders occur in the skin in response to ultraviolet (UV) exposure, genetic background, hormones and inflammation due to physical injury. The two most common pigmentary disorders are hyperpigmentation and melasma.

Tyrosinase: The enzyme tyrosinase is responsible for melanin production.

Fitzpatrick Scale: This scale is based for correlation between the risk of skin burning and tanning. The scale ranges from I – IV, with skin type I that always burns and never tans. The darker the skin is, the higher risk of burns occurring. This classification system was created by Thomas B. Fitzpatrick (1919-2004).

CHAPTER 1: INTRODUCTION

1.1 BACKGROUND

There has been a global reawakening in cosmeceutical markets for an improved facial aesthetic appearance (Sharma and Sharma 2012). While the biosafety of cosmetics was acceptable in the early 1950s, concerns arose when skin lightening products showed links to harsh reactions (Nohynek *et al.* 2010). These concerns peaked when harmful side effects of various skin lightening chemicals such as arbutin, kojic acid and hydroquinone were reported in products (Zhu and Gao 2008; Huang *et al.* 2012). Such harmful effects include irritation, inflammation, thinning of skin, scarring, kidney, liver, or nerve damage (Shroff, Diedrichs and Craddock 2018). These reportings subsequently increased demand for and access to natural products.

Pigmentary disorders rank among the five common complaints among Blacks, Arabs and South Asians (Konda, Geria and Halder 2012). This has led to an increase in usage of skin creams with bleaching properties among many black South African women (Dlova, Hendricks and Martin 2012). These women are in pursuit of treatment regimens that improve the appearance of pigmentation and overall skin tone (Swanson, Leo and Finlay 2014). Furthermore, those with pigmentary disorders are predisposed to poor self-confidence (Jiang *et al.* 2018), which affects their quality of life (Yadav 2018). Thus, the natural formulation of cosmetics is essential (Walters and Roberts 2008).

Pigmentation remains a challenge due to the limited availability of successful treatment options (Konda, Geria and Halder 2012). Despite the assured guarantee that hydroquinone (HQ) is a successful topical treatment, its link to allergic reactions and irritant contact dermatitis remains a concern (Woolery-Lloyd and Kammer 2011). There is an increased demand for the inclusion of natural treatment options for both facial and body rejuvenation. Chemical based cosmetics may be harmful to the skin, which has increased the interest of many consumers in the beneficial effects of natural products (Do *et al.* 2015).

Natural products have the ability to exfoliate, lighten skin, and reduce skin irritations (Thakur, Negi and Kush 2013). The biosafety of herbal cosmetics is far superior when compared to traditional cosmetics, as they are paraben free and less irritative (Joshi and Pawar 2015). Essential oils are natural compounds characterised by the strong odour formed by aromatic plants, thereby invoking such benefits (Bakkali *et al.* 2008). The safety and long-term use of natural ingredients, also known as essential oils, are beneficial in treating pigmentary disorders (Sundaram and Emer 2011). Essential oils are widely used in medical preparations, dietary supplements, aromatherapy, and cosmetology (Misharina and Samusenko 2008). They exhibit good stability during use, and support product blending with other carrier components.

Sandalwood oil imparts moisturising and balancing effects on skin texture, thus improving skin conditions and improving existing pigmentary conditions (Gite *et al.* 2013). Lemon oil, in contrast is known for its astringent, cleansing and depigmenting properties (Kole *et al.* 2005), characteristics which are also beneficial to the skin. Thus, both essential oils are known to exfoliate, lighten skin and reduce skin irritations (Reddy *et al.* 2011; Thakur, Negi and Kush 2013). However, the use of these oils in post-inflammatory hyperpigmentation (PIH), whether used independently or in combination with each other, remains unknown.

Pigmentation is a common dermatologic condition found in all skin types but is more prominent in dark skin (Woolery-Lloyd and Kammer 2011). To date, the common treatment agents for depigmentation are kojic acid, arbutin, catechins, HQ and azelaic acid (Zhu and Gao 2008; Huang *et al.* 2012).

The artificial combinations of these ingredients often result in irreversible cutaneous skin damage, resulting in limited usage (Konda, Geria and Halder 2012). For this reason, botanical and natural components in cosmetics have gained more popularity due to their tolerable effects (Leyden *et al.* 2011; Sumit *et al.* 2012). There is also an increased focus on identifying safe and effective skin depigmenting agents for pigmentation treatment (Huang *et al.* 2012). Therefore, this study aims to explore the effectiveness of lemon and sandalwood essential oils in the treatment of post-inflammatory facial pigmentation in African females aged 18 to 35 years.

1.2 RESEARCH AIM AND OBJECTIVES

1.2.1 Aim

The aim of this study was to evaluate the effectiveness of lemon and sandalwood essential oils in the treatment of post-inflammatory facial pigmentation among African females aged 18 to 35 years.

1.2.2 Research objectives

- To determine the progression of post inflammatory facial pigmentation using lemon essential oil and a placebo treatment by means of a Skin Analyser[®] machine
- To determine the progression of post inflammatory facial pigmentation using sandalwood essential oil and a placebo treatment by means of a Skin Analyser[®] machine
- To compare the effectiveness of lemon oil and sandal wood oil in the treatment of facial post inflammatory pigmentation in African females.

CHAPTER 2: LITERATURE REVIEW

2.1 Anatomy of the integumentary system

The skin is important for absorption, excretion, protection, thermoregulation, sensory perception and immunity (Stephen-Haynes 2014; Stephen-Haynes 2013; Proksch, Brandner and Jensen 2008). It is enclosed with a barrier lipid layer assisting moisture balance which prevents dehydration while providing waterproofing (Mizutani *et al.* 2009). This protective role is critical in preventing infiltration of microbial organisms, chemical irritants, toxins and solar radiation (Bangert, Brunner and Stingl 2011; Lueberding, Krueger and Kerscher 2013).

The skin responds to environmental changes, therefore, it maintains internal homeostasis (Singh and Maibach 2013). Skin varies in thickness according to function and area of the body. On the eyelids, the skin is 0.5mm thick and 3-4mm thick on the soles of the feet and hands (McLafferty, Hendry and Farley 2012). The cellular structure of the skin is multi-layered which prevents dehydration and provides temperature stability, insulation of fats, and vitamin D synthesis (Lai-Cheong and McGrath 2013; Shier, Butler and Lewis 2007; Duckney *et al.* 2013). The skin is made up of the epidermis, dermis and hypodermis (Venus, Waterman and McNab 2011).

The outermost layer, the epidermis, synthesises keratin a protein while the dermis contains collagen. The hypodermis contains adipose tissue, providing insulation (Arda, Göksügür and Tüzün 2014). Collectively they contribute to the integumentary system as an external protective barrier (Kolarsick, Kolarsick and Goodwin 2011; Bangert, Brunner and Stingl 2011). The epidermis is a continually renewing epithelium, divided into several layers (Baroni *et al.* 2012) which assist the epidermis in upholding its structure. The epidermis is a superficial layer differentiated into multiple stratified squamous epithelia (Lai-Cheong and McGrath 2013). The stratum layers (basale, spinosum, granulosum, lucidum and corneum) make up the epidermis.

The epidermis serves as a skin barrier (Darlenski and Fluhr 2012) that receives oxygen and nutrients by diffusion from the dermis (Jones 2014). Keratinocytes and dendritic cells make up the layers that form the epidermis (Wong *et al.* 2015). The epidermal layer houses pigment melanocytes, Langerhans cells and Merkel cells (Kolarsick, Kolarsick and Goodwin 2011; Rolstad, Ermer-Seltun and Bryant 2011). Melanocytes are responsible for providing skin colour and are the foundation of the pigmentation process (Lavers 2017).

The dermis is a fibrous elastic tissue that hosts vessels, nerves, and sensory receptors (Arda, Göksügür and Tüzün 2014). The strong fibre bundles interact with elastic fibres (Meyer and Seegers 2012) creating a tough, resilient layer, protecting the body against mechanical injury (Venus, Waterman and McNab 2011). The dermis is separated from the epidermis by the dermal epidermal junction (Wang *et al.* 2015). The dermis functions to provide nutrients and physical support to the epidermis (McLafferty, Hendry and Farley 2012). It is vascular, with lymphatic drainage and sensory receptors (Lai-Cheong and McGrath 2013). Dermal fibroblasts, immune cells, and hair follicles dominate this layer (Brohem *et al.* 2010).

The dermis includes the superficial papillary layer and the deeper reticular layer (Arda, Göksügür and Tüzün 2014; Barcaui *et al.* 2015). The dermal matrix lies beneath the basement membrane and provides energy and nutrition to the epidermis (McLafferty, Hendry and Farley 2012). This allows the body to transport immune cells via the circulatory system, and removal of damaged cells through lymphatic circulation (Brodell and Rosenthal 2008). The subcutaneous layer is composed of fat that provides insulation, protective padding, and energy storage (Hwa, Bauer and Cohen 2011). Thus, this layer protects the body from mechanical injury while concealing water. This process aids in thermal regulation.

The basal layer contains column-shaped keratinocytes that attach to the dermis. These cells contain the melanin pigment found within melanocytes (Kolarsick, Kolarsick and Goodwin 2011) and are responsible for stem cell replication and pigment distribution (Thomas 2010). Melanocytes make up 5-10% of the total cell population (Venus, Waterman and McNab 2010). They create melanin that protects the skin from harmful UVA/UVB effects. Melanin gathers in melanosomes that are transported by dendrites to surrounding keratinocytes (Lavers 2017). The epidermis is mainly responsible for pigmentation; therefore, the epidermis and its structures will be discussed in detail.

2.1.1 Cellular features of the epidermis

The predominant cell type of the epidermis is the keratinocyte found from the basal to the granular layer (Wickett and Visscher 2006). The epidermis also harbours melanocytes, Langerhans and Merkel cells (Kolarsick, Kolarsick and Goodwin 2011), as detailed in Figure 2.1. They form a barrier to infection from environmental pathogens and regulate transepidermal water loss (Baroni *et al.* 2012). The cellular components of the epidermis are important in pigmentation development therefore will be further elaborated upon.

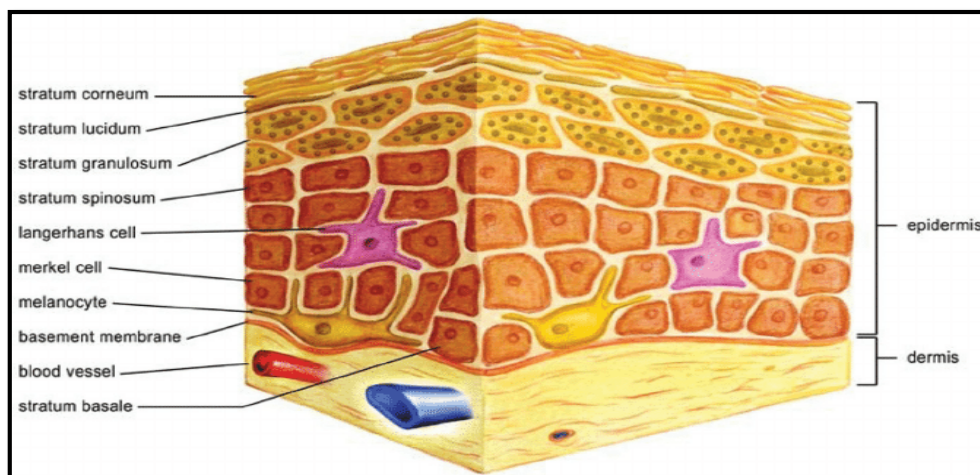


Figure 2.1: Cellular layers of the epidermis

Source: adapted from Miranda *et al.* (2007)

2.1.1.1 Keratinocytes

Keratinocytes are building blocks of the epidermis (Barcaui *et al.* 2015) and function as an effective barrier against harmful elements (Lulevich *et al.* 2010). Merkel, Langerhans and melanocyte interactions with keratinocytes are fundamental in the development and functioning of the skin (Sengupta *et al.* 2010; Arda, Göksügür and Tüzün 2014). These interactions are also necessary for the pigmentation process (Kolarsick, Kolarsick and Goodwin 2011). Keratinisation is a process of cytodifferentiation from their germinative state (stratum basale) to hardened cells filled with protein in the stratum corneum (Shetty and Gokul 2012). This process is important in the development and health of the cell (Bragulla and Homberger 2009).

Keratinocytes provide structure and strength to the cell (Hwa, Bauer and Cohen 2011). Cell division gives rise to keratinocytes that undergo differentiation as they pass through the layers (Tsuruta *et al.* 2002; Qiu *et al.* 2016). Although the epidermis is the major source of vitamin D, keratinocytes are significant in metabolising vitamin D to its active state (Bikle 2011). Humans synthesise vitamin D₃ when 7-dehydrocholesterol interact with ultraviolet (UV) light (Shahriari *et al.* 2010).

2.1.1.2 Merkel cells

Merkel cells are found at the base of the epidermis (Owens and Lumpkin 2014). They are found in the fingertips and lips (Woo, Lumpkin and Patapoutian 2015) providing the touch sensation.

2.1.1.3 Langerhans cells

Langerhans cells reside in the basal layer of the epidermis. They are located in the epithelia of the respiratory and digestive tracts and possess strong immunogenic properties involved in antimicrobial immunity (Chomiczewska *et al.* 2009). These cells are responsive to different environmental stimuli (Jaitley and Saraswathi 2012), protecting the body against foreign particles.

2.1.1.4 Melanocytes

Melanocyte cells produce pigment that is located within the basal layer (Thomas 2010). They are transferred through dendrites to keratinocytes and are critical in UV protection and determining skin colour (Goding 2007; Baroni *et al.* 2012; Lin and Fisher 2007). Melanocytes are responsible for the increased epidermal pigmentation (Nicolaidou and Katsambas 2014), that appear in higher concentrations in melanosomes (Kang and Ortonne 2010; Sarkar *et al.* 2016). The relationship between melanocytes and keratinocytes is vital in pigment development and transportation (Costin and Hearing 2007).

According to Lang, Mascarenhas and Shea (2013), melanin is produced by melanocytes in melanosomes as the epidermis renews (Wickett and Visscher 2006). Thus, the active export of melanosomes through the dendritic processes forms the foundation of skin pigmentation (Goding 2007).

Melanin production is dependent on the structural proteins of melanosomes, enzymes for melanin synthesis, and proteins for melanosome distribution (Yamaguchi and Hearing 2014). These factors have a crucial role in inflammatory responses and PIH (Plonka *et al.* 2009). A recent study indicates an improved understanding of skin pigmentation if the links between cellular and molecular interactions of melanocytes and keratinocytes are clearly understood (Mizukoshi, Nakamura and Oba 2015).

2.2 Melanin

Melanin is responsible for pigments in skin, hair, and eyes (Solano 2014). Skin colour is determined by the combination of carotenoids, oxy-deoxy-haemoglobin and different types of melanin (Brenner and Hearing 2008). Melanin is divided in two groups, eumelanin (eu = good) and pheomelanin (pheo = cloudy) (Ito *et al.* 2011; Roulin *et al.* 2011). Most melanin is dark, from black to brown (eumelanin), while other melanins (pheomelanin) are reddish or yellowish. The quantity and ratio of eumelanin to pheomelanin determines the colour of hair, skin, and eyes (Ito *et al.* 2018; Herrling, Jung and Fuchs 2008).

The intensity of pigment is dependent on the quantity of melanosomes (Brenner and Hearing 2008), melanin synthesis and transportation within keratinocytes (Patel 2015). Melanin is the first defence against UV damage, hence, the effects of melanin on UV radiation in skin requires exploration (Jablonski and Chaplin 2000).

Melanin protects the skin against the high levels of reactive oxygen that damage cells (White and Zon 2008). Melanosomes in light skin are small and mature early (stages I and II) as displayed in Figure 2.2. In dark skin, melanosomes are large, maturing at stage V to IV (Bastonini, Kovacs, Picardo 2016). Pigmentation differences arise from quantity variation, size and distribution of melanosomes (Lin and Fisher 2007).

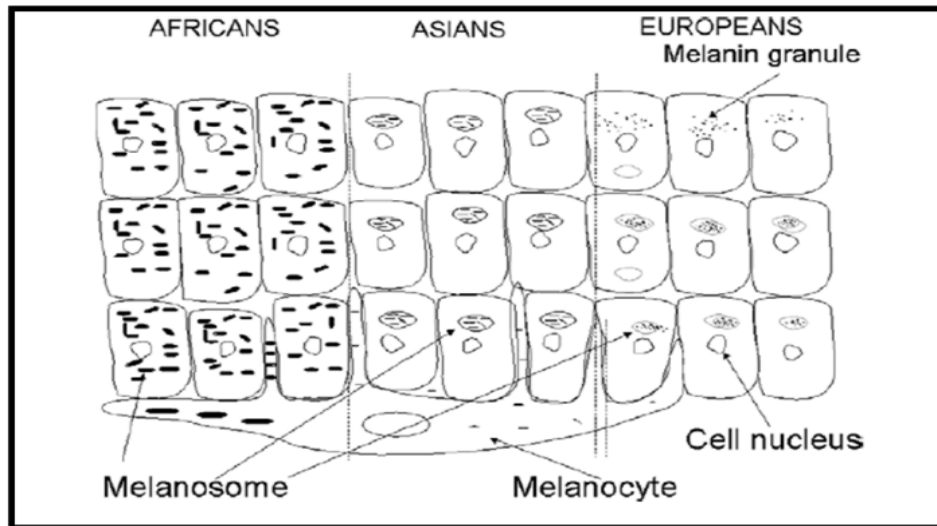


Figure 2.2: Difference in melanosome and melanocyte distribution among Africans, Asians and Europeans
 Source: Adapted from Bastonini, Kovacs, Picardo (2016)

2.2.1 Melanogenesis

Melanogenesis or melanin production (D’Ischia *et al.* 2015) is regulated by signals from keratinocytes (Schallreuter *et al.* 2008). These signals are controlled by the amino acids L-tyrosine and the enzyme tyrosinase in melanosomes (Solano 2014; Park *et al.* 2009). Raised melanogenesis activities result in higher pigment levels (Padma, Satyamoorthy and Bhat 2015), thus increasing susceptibility to pigmentary disorders. Therefore, treatment options must include melanogenic inhibitors and antioxidants that prevent or treat PIH (Huang *et al.* 2012).

2.3 PIGMENTARY SKIN DISORDERS

Skin discoloration triggered by pigmentary disorders are prominent in dark skin (Woolery-Lloyd and Kammer 2011). Pigmentary disorders rank among the five most common complaints among Blacks, Arabs and South Asians (Konda, Geria and Halder 2012). These disorders occur in response to UV exposure, genetic background, hormones and inflammation due to physical injury (Leyden *et al.* 2011).

Abnormal melanin production is the key cause of these disorders (Huang *et al.* 2012; Sumit *et al.* 2012). Pigmentary conditions include melasma, PIH, and lentigo (Cayce, McMichael and Feldman 2004; Woolery-Lloyd and Kammer 2011), all of which can lead to psychological distress. The quality of life in those affected by pigmentary disorders is altered (Nouveau *et al.* 2016).

Pigmentation is divided into hypopigmentation and hyperpigmentation (Nicolaidou and Katsambas 2014). Post-inflammatory hypopigmentation is an autoimmune condition causing chalky-white patches of skin. The severity of lost pigment relates to the extent and degree of inflammation (Vachiramon and Thadanipon 2011). Hypopigmentation affects all ages and progresses rapidly (Hill and Batchelor 2017). A common type of hypopigmentation is vitiligo, characterised by the absence of melanocytes or disruption of their function (Deeva *et al.* 2017).

Hyperpigmentation can be congenital, either cutaneous or systemic (Cestari, Dantas and Boza 2014). Hyperpigmentation is characterised by various skin disorders (Speeckaert *et al.* 2014) that affect a large portion of the population (Augustyniak, Erkiert-Polguj and Rotsztein 2015). Hyperpigmentation may appear localised or diffused, with severity and frequency increased in darker individuals (Desai and Alexis 2014; Nouveau *et al.* 2016). Hourblin *et al.* (2014), suggests that hyperpigmentation appears early and may increase with age.

The rate of pigmentation development is dependent on the size, cellular distribution and type of melanosomes in the epidermis rather than just the number of melanocytes (Scherer and Kumar 2010). Although PIH is common among dark skinned individuals, it is prevalent in acne skin, eczema and contact dermatitis (Davis and Callender 2010). The two most common pigmentary disorders are melasma and PIH (Nieuweboer-Krobotova 2013).

2.3.1 Melasma

Melasma is common in dark skin (Rodrigues and Pandya 2015). It manifests as pigmented macules and patches on the face (Sarkar *et al.* 2016; Sheth and Pandya 2011), causing much emotional distress (Handel, Miot and Miot 2014). The aetiology of melasma is a combination of hormonal influences, UV exposure, genetics, pregnancy, and psychological stress (Scheinfeld 2007).

Certain cosmetics and medication may aggravate the condition (D'Elia *et al.* 2017) because they alter melanin production. Melasma treatment is difficult due to its recurrence (Sehgal *et al.* 2011). Therefore, treatment should be aimed at preventing and reducing the appearance of melasma with minimal side effects (Gupta *et al.* 2006).

The first line of treatment should be sun protection (Scheinfeld 2007), with other treatments including topical preparations, chemical peels and lasers (Rendon *et al.* 2006). Hydroquinone and azelaic acid may be prescribed as tyrosinase inhibitors acting directly on melanogenesis, however the safety of these products are not certain (Situm *et al.* 2011). No single therapy has reported success, so combinations of treatments are more common (Sheth and Pandya 2011).

2.3.2 Post-Inflammatory hyperpigmentation

Post-inflammatory hyperpigmentation is the “darkening of skin following inflammatory eruption or cutaneous injury” (Vashi and Kundu 2013). Post-inflammatory hyperpigmentation is an acquired hypermelanosis, appearing as a brown-to-black macules (Kubba *et al.* 2009) and is common among dark skinned individuals (Nestor *et al.* 2014; Eimpunth, Wanitphadeedecha and Manuskiatti 2013). The condition is characterised by skin darkening following inflammation and skin injury (Cestari, Dantas and Boza 2014; Youn 2016) as a result of the skin’s inflammatory processes. Keratinocytes, Langerhans cells and lymphocytes alter the function of the cells, resulting in PIH (Callender *et al.* 2011; Deckers, Hammad and Hoste 2018). Although skin trauma, skin irritants and eczema are influencers of PIH, acne is the leading cause (Nouveau *et al.* 2016).

2.3.2.1 Pathophysiology and aetiology of PIH

Hyperpigmentation results from higher rates of melanin production (Huang *et al.* 2012). Post-inflammatory hyperpigmentation occurs after several dermatologic processes with melanin, melanocytes and keratinocytes (Chaowattanapanit *et al.* 2017). Following inflammation, melanocytes increase melanin production (Callender *et al.* 2011) which causes an increased transfer of pigment to surrounding keratinocytes (Lacz *et al.* 2004). This process leads to PIH (Halder and Nootheti 2003). The causes of PIH are skin trauma, friction, application of skin irritants, eczema, psoriasis, drug reactions, skin infections and sunburn. Studies show correlations between the inflammatory responses from these causes and melanocyte stimulation (Lee, Hossaine and Park 2016), leading to the production of abnormal melanin quantities.

Tyrosinase is responsible for melanin production and mediates melanin production through the intermediate, L-dopa (Ingber 2009). Once tyrosinase and structural proteins are delivered to the inflamed site, melanin synthesis begins (Manga *et al.* 2013). Numerous reports indicate acne and acne scarring as the main cause of PIH (Kaufman, Aman and Alexis 2018; Isedeh *et al.* 2016; Adalatkah and Bazargani 2013; Zawar, Agarwal and Vasudevan 2015). Dark skinned individuals are reported to have a more intense incidence of PIH (Patel 2015). [Figure 2.3 displays PIH development in acne].

2.3.2.2 The PIH process

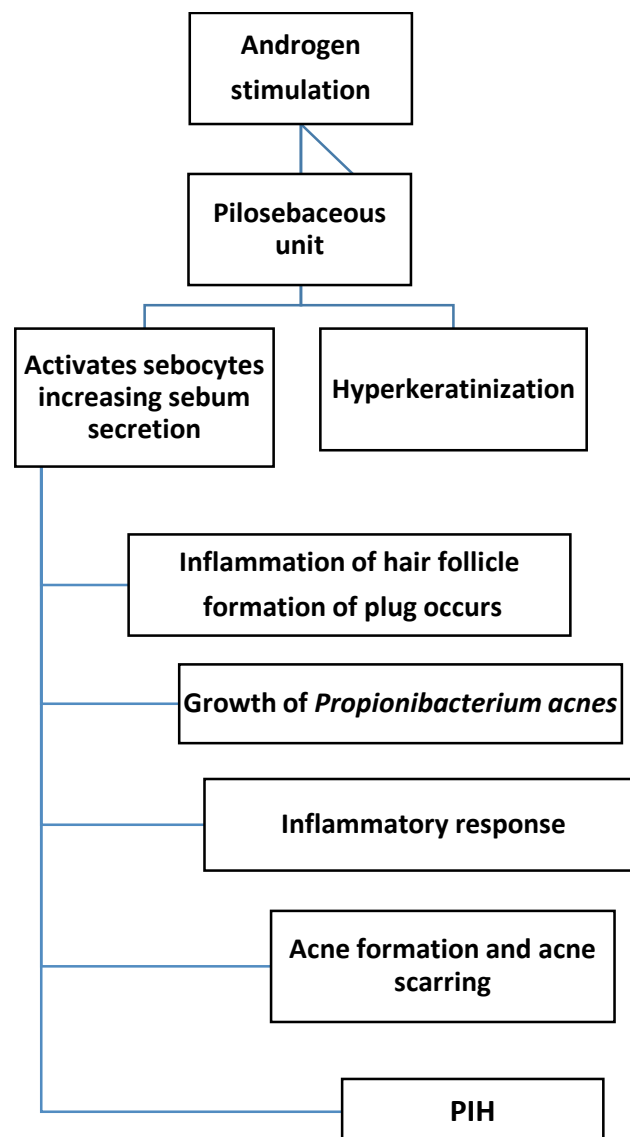


Figure 2.3: Process of PIH formation in acne
 Source: Adapted from Pink, Anzengruber and Navarini (2017)

2.3.2.3 Acne in PIH development

Acne vulgaris (AV) is a common pigmentary disorder of the pilosebaceous follicles (Zaenglein *et al.* 2016) that commonly affect the face, chest, shoulders and back (Pink, Anzengruber and Navarini 2017). Non-inflammatory and inflammatory acne lesions (Purdy and de Berker 2011) consist of comedones, papules, pustules, and nodules (Yildizgoren and Togral 2014). *Acne vulgaris* is a common skin disease and is the main diagnosis in dermatology (Chen *et al.* 2011), affecting 85% of people between ages of 12-24 years (Luqman *et al.* 2019). Acne scarring occurs in 20% of teenagers with *acne vulgaris* (Common, Barker and Van Steensel 2019). Inflammatory mediators, the keratinisation process, sebum production and follicular colonisation by *Propionibacterium acnes* (*P. acnes*) are responsible for acne development (Williams, Dellavalle and Garner 2012). However, Jonczyk-Matysiak *et al.* (2017), believes that acne occurrence is not limited to these factors and may be influenced by a host of behavioural and genetic elements such as age, diet, race and daily practices.

According to Greydanus (2015), acne is an inflammatory condition that begins with follicular keratinocytes becoming adhesive. Thus, a keratin plug is formed that blocks the follicle with sebum (Abad-Casintahan *et al.* 2016). Furthermore, Fabbrocini *et al.* (2010) consider that the androgen hormone is largely responsible for acne development because testosterone controls the size of the sebaceous gland and sebum secretion. *P. acnes* activates keratinocytes and sebocytes (Kumar *et al.* 2016).

Androgens show an interactive role in the initiation of acne development, influencing the formation of acne lesions (Kurokawa *et al.* 2009). These acne lesions are difficult to remove and develop into acne scars. Acne scars are the persistent and they may remain permanently. Recent reports indicate acne scarring to cause both cosmetic and social insecurities such as low self-esteem, which negatively impact the quality of life (Moon *et al.* 2019; Luqman *et al.* 2019). A family history of acne predisposes to early acne onset and severe progression in future generations (Degitz and Ochsendorf 2017).

2.4 Hyperkeratinisation

Hyperkeratinisation occurs when cells of the follicle become interconnected and do not shed normally onto the skin's surface, resulting in lesions characteristic of acne (Thiboutot 2000). This process (Figure 2.4) is crucial in the development of acne and inflammation of the follicle (Kurokawa *et al.* 2009). This progression occurs due to irritation of the epithelial cells (Deo and Deshmukh 2018). While sebum and hormone production is an important prerequisite for acne development, hyperkeratinisation must take place for acne to appear (Persson *et al.* 2018).

Follicular hyperkeratosis is regarded as a possible initiator of the acne sequence (Tilles 2014). As the hair follicle becomes infected, a keratin plug is formed, thus creating a lesion. Therefore, the pathogenesis of acne is dominated by the interchange between excessive sebum production, hypercolonisation of *P. acnes*, hyperkeratosis of the hair follicle, and inflammation (Chen *et al.* 2011). Androgens are significant in acne formation as they promote keratinocyte and sebaceous gland proliferation (Das and Reynolds 2014). This process is most common during adolescence and during early adulthood (Yildizgoren and Togrul 2014).

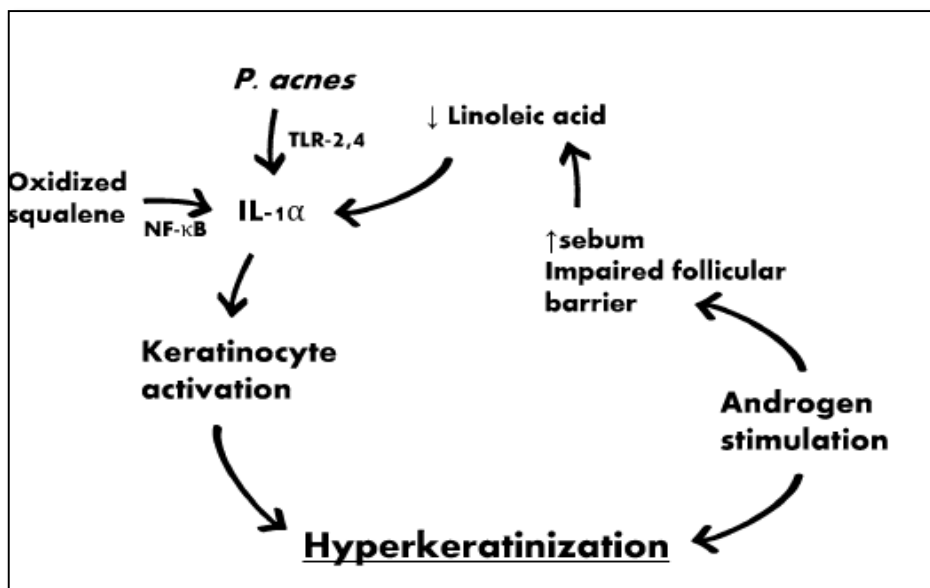


Figure 2.4: The hyperkeratinisation process
Source: Adapted from Das and Reynolds (2014)

2.5 Treatment options for PIH

Treating hyperpigmentation is a challenge (Clark and Sivamani 2016). Topical treatment combined with sun protection is the first treatment for PIH (Eimpunth, Wanitphadeedecha and Manuskiatti 2013). The management of PIH should be aimed at identifying the underlying condition (Davis and Callender 2010). While treatment may benefit some, it may create or worsen PIH in others (Grippaudo and Di Russo 2016). Treatment should aim to disrupt the distribution of melanosomes and inhibit the tyrosinase enzyme (Choi *et al.* 2016). The use of borax, sulfur, potassium and sodium hydroxide have been explored as lightening PIH (Clark and Sivamani 2016), but are not permanent solutions.

Currently, treatments include HQ, salicylic peels, retinoids, and laser therapy, alone or in combination, however these demonstrate low success rates (Konda, Geria and Halder 2012). Although HQ is considered an effective treatment for PIH, it is linked to increased allergic reactions. The microbiological purity of options such as HQ is maintained by preservatives (Herman *et al.* 2013) and even though only small concentrations of preservatives are used, these are the root cause of pigmentary reactions (Bunyavaree, Kasemsarn and Boonchai 2016). Such reactions prompt consumers to seek safer treatment and product options (Woolery-Lloyd and Kammer 2011; Swanson, Leo and Finlay 2014).

The need for natural therapies for hyperpigmentation is evident and necessary in for the safe treatment of PIH (Clark and Sivamani 2016). Therefore, the use of natural compounds within the cosmetic industry as a preservative and active ingredient warrants exploration. Treatment options available for PIH may be classified into lasers, pharmaceuticals and natural remedies.

2.5.1 Lasers

The high intensities of laser have proved effective in clearing erythema (Wang and Chen 2012), PIH has and shown partial PIH clearance or deterioration with laser (Sebaratnam *et al.* 2014). While PIH may disappear with laser treatment, it tends to reoccur shortly thereafter (Mlosek *et al.* 2012). However, in general, the risk of PIH progression and scarring from lasers is high due to severe thermal damage (Leok 2010; Chaowattanapanit *et al.* 2017).

In particular, laser treatment at high intensities on darker skin may actually result in PIH (Alam and Warycha 2011). Thus, the risk of scarring in ethnic skin is greater (Alexis 2013). Consequently, many patients are reluctant to receive laser treatment (Negishi *et al.* 2013) as PIH is a common complication of laser and other light sources (Silpa-Archa *et al.* 2017). Darker skin absorbs more of the light energy due to the higher levels of melanin in the skin.

2.5.2 Hydroquinone

Hydroquinone is a whitening agent (Tse 2010), known as 1,4 dihydroxybenzene (Draelos 2007), and is considered the best pharmaceutical treatment for PIH. Hydroquinone is used to treat melasma, freckles and PIH (Hu *et al.* 2009). Creams containing HQ are commonly used for dark skinned individuals suffering from hyperpigmented skin (Toombs 2007). These preparations are unregulated and may worsen pigmentation when used without correct sun protection (Walters and Roberts 2008).

Although HQ may be effective in treating PIH, its safety and toxicity remains controversial (Gold and Biron 2011; Hu *et al.* 2009). This has resulted in the exploration of hydroquinone-free skin lighteners and natural treatments (Tse 2010), that improve PIH without harmful effects and post treatment conditions, thus highlighting the need for safer, effective cosmetic preparations.

Glazer, Sofen and Gallo (2016) found that Fitzpatrick recognised HQ as a depigmenting agent in the 1960s. HQ was found to be strong inhibitor of melanin production. Hydroquinone inhibits melanin production due to its potent antioxidant ability in increasing oxidative stress (Ibrahim *et al.* 2015). Hydroquinone improves the enzymatic oxidation processes of tyrosine and phenol (Kanthraj 2010; Tatebayashi *et al.* 2014). As a result, HQ obstructs RNA and DNA synthesis, altering melanosome formation, thus damaging melanocytes (Tse 2010). Therefore, its primary mechanism of action is based on melanin inhibition (de Mendonca *et al.* 2014). These processes are significant in PIH formation. Hydroquinone acts by reducing the thickness of the stratum corneum that increases the penetration and efficacy of HQ (Guevara and Pandya 2003). Consequently, keratinocytes are shed and less pigmented keratinocytes are formed (Chandra, Levitt and Pensabene 2012), reducing PIH. Hydroquinone is oxidised by tyrosinase thereby becoming toxic to melanocytes Hu *et al.* (2009), as well as affecting the functioning of other cells (Malek *et al.* 2013).

While HQ has proven its effectiveness against PIH, it is unstable and reactant in cosmetic formulations (de Mendonca *et al.* 2014), therefore packaging must be non-transparent and airtight to avoid light and air exposure (Zhu and Gao 2008). Hydroquinone is highly reactive with oxygen; HQ presents as a cream colour, changing to dark yellow or brown as oxidation occurs. As the discoloration progresses, the effectiveness of the HQ decreases (Draelos 2007).

The safety of hydroquinone is debatable (Dreher *et al.* 2013). Irritation, hyper and hypopigmentation, and nail discoloration are evident with its use (Nordlund, Grimes and Ortonne 2006). Although HQ is considered effective at low concentrations of 4% or less, its safety has come into question (Tse 2010). Safety concerns have encouraged research into alternate, natural agents including retinoids, azelaic acid, and kojic acid (Mauricio, Karmon and Khaiat 2011). Thus, more studies on safe alternative skin-lightening agents are needed to establish treatment efficacies with improved safety (Mendoza, Singzon and Handog 2014).

2.6 Natural remedies for PIH

There is evidence of skin preparations being used in Egypt and India dating back 1550 B.C (Patkar 2008), since early human life (Garbossa and Campos 2016). Embraced by all cultures, humans have used cosmetics for 6000 years (Draelos 2015). Scented preparations were used to clean, soften skin and mask body odour (Chaudhri and Jain 2009). Hence, cosmetic products may originally have been linked to hygiene as their primary purpose (Garbossa and Campos 2016). Cosmetics were also used to enhance complexion, skin, hair, and nails (Kumar and Paulose 2014).

Greater awareness has emerged for its curative and medicinal use, as cosmetics are lucrative, innovative and beneficial (Kumar, Massie and Dumonceaux 2006). The cosmetic market has constantly developed (de Melo *et al.* 2013; Kerscher and Buntrock 2011), with continuous innovations on how to maintain a good skin appearance (Chen, Chen and Lin 2011). These cosmetic advancements contribute to global economic growth (Ramli 2015). Within these expansions, chemicals replaced natural ingredients, some of which can trigger allergic reactions (Kumar, Massie and Dumonceaux 2006), initiating various pigmentary conditions. This has further prompted research into the natural products (Dimitrova, Kaneva and Gallucci 2009).

Facial appearance is important in the judgement and decisions of others (Little *et al.* 2012), hence cosmetics are used to improve appearance (Zeigler-Hill and Noser 2013; Kumar and Paulose 2014; Michelle and Hye-Shin 2009). Their significance in improving aesthetic appearance has grown (Ghodsee 2007) as cosmetics continue to dominate the health and beauty industry (Lopaciuk and Loboda 2013). Although the role of cosmetics is evident, literature surrounding the natural cosmetic market and its effects on pigmentary disorders remains scarce (Matic and Puh 2016).

Africa reports the highest prevalence of skin lightener usage (Davids *et al.* 2016), revealing black females among the highest users (Dlova *et al.* 2014). Due to this demand, Dlova, Hendricks and Martin (2012) report that South African women require skin lightening creams that improve complexion without harmful effects. Daily used foundations, sunscreens and perfumes may cause allergic reactions (Kumar and Paulose 2014).

Skin-lightener side effects are inevitable and might be permanently disfiguring (Petit *et al.* 2006). Therefore, consumers now desire natural products with active ingredients which may reduce such effects. A portion of South Africans still use medicinal plants to treat skin disorders (de Wet, Nciki and van Vuuren 2013). These plants demonstrate decreased melanogenesis, thus causing skin lightening. However, the bioactivity of these compounds/botanic extracts are yet to be explored (Burger *et al.* 2016).

Preservatives in products maintain microbiological purity during manufacture, packing and storage (Lv *et al.* 2015). They are purposed to inhibit microorganism activity while prolonging the shelf life of the product (Herman *et al.* (2013). It is believed that preservatives contribute to allergies, however, often in a dose dependent manner (Lundov *et al.* 2011) Preservatives and fragrances are responsible for 80% of cosmetic allergies (Zaragoza-Ninet *et al.* .2016). Chemical based products triggered health concerns (Reddy *et al.* 2011) which has increased demand for preservative free and green products (Herman *et al.* 2013).

The World Health Organization defines green products as “finished labelled medicinal product that contain an active ingredient, or underground parts of the plant or other plant material or combinations” (Parveen *et al.* 2015). Also known as natural products, they are manufactured using safe cosmetic ingredients and modern technology (Sumit *et al.* 2012; Narayanaswamy and Ismail 2015).

Natural products benefit the skin (Kaczmarczyk *et al.* 2015) and possess natural defence properties suitable for allergy prone skin (Patel, Padhtare and Saudagar 2015; Wright *et al.* 2007; Farzaneh and Carvalho 2015). They are easily absorbed into the skin (Mukherjee *et al.* 2011), allowing for improved penetration of minerals and nutrients (Joshi and Pawar 2015). For these reasons, the exploration into these ingredients are essential in understanding their uses within the cosmetic industry.

2.6.1 Essential oils

Essential oils (EOs) may be defined as: “Odorant products, generally of a complex composition, obtained from a botanically defined plant raw material, either by steam of water or by dry distillation without heating” (El Asbahani *et al.* 2015). Essential oils are natural, intricate mixtures with potent odours (Bakkali *et al.* 2008) that disguise unpleasant odours (Hyldgaard, Mygind and Meyer 2012). The quality, efficacy and correct identification of the plant is crucial in maximising results (Bharkatiya *et al.* 2008). Their uses within various industries are broad and will be discussed further.

Clinical aromatherapy is the fastest growing complementary therapy globally (Steflitsch and Steflitsch 2008). These oils are extracted from roots, herbs, fruits and bark to promote holistic wellbeing (Bharkatiya *et al.* 2008). The composition and stability of EOs allows for blending with carrier components (Misharina and Samusenko 2008). Phytochemicals in EOs decrease the number of harmful microorganisms found in chemical-based preparations (Steflitsch and Steflitsch 2008), thus, they are used in medical preparations, dietary supplements, aromatherapy, food and cosmetology (Fornari *et al.* 2012). Complex chemical components (terpenes, terpenoids, phenylpropenes and phenolics) make up the oils (Thakur, Negi and Kush 2013).

The medicinal benefits of EOs have recently been highlighted (Narayanaswamy and Ismail 2015). Their beneficial effects in facial treatments has stimulated consumer awareness (Do *et al.* 2015; Thakur, Negi and Kush 2013). Thus, the transition by consumers from facial treatments with products containing chemical preservatives to plant based facial treatment products (Herman *et al.* 2013; César *et al.* 2017). Essential oils eradicate free radicals and improve skin conditions (Cefali *et al.* 2016), thus, giving rise to holistic approaches to treatment options (Fornari *et al.* 2012).

All plant organs (flowers, buds, stems, leaves, fruits, seeds and roots) contain EOs in their cells (Pandey, Singh and Tripathi 2014; Lawrencet 2001). Although they are present in minimal quantities, chemical and structural differences exist (Oprean *et al.* 2001; Pandey, Singh and Tripathi 2014). The oil composition varies with the plant developmental stage and growth environment (Martinelli *et al.* 2017). Essential oils are antimicrobial, antiviral, antioxidant and anti-inflammatory (Raut and Karuppayil 2014). These properties allow for uses in various industries (El Asbahani *et al.* 2015), emerging as components to treat diseases and illnesses (Solorzano-Santos and Miranda-Novales 2012).

The cosmetic and pharmaceutical industries use EOs as natural preservatives (Dreger and Wielgus 2013). They serve as replacements for synthetic preservatives (Andrade *et al.* 2014), thus reducing side effects. EOs are used in skin creams, shampoos, soaps and perfumes (Raut and Karuppayil 2014; Łopaciuk and Łoboda 2013; Faidi *et al.* 2014).

There are various extraction methods of EOs. They are extracted from plants by steam or hydrodistillation (El Asbahani *et al.* 2015; Tongnuanchan and Benjakul 2014). Steam distillation is the preferred method for extraction (Raut and Karuppayil 2014), with 93% of oils being extracted this way. Plants are positioned in boiling water, breaking down the plant, releasing EOs (Tongnuanchan and Benjakul 2014; Martinelli *et al.* 2017). This distillation method is the simplest and most economical method.

Elevated temperatures and prolonged extraction time cause chemical modifications to the oil affecting the quality of the product (El Asbahani *et al.* 2015). Solvent extraction is widely used to extract active components from plants (Hassim *et al.* 2014). It is a gentle method that creates less movement of the EO compared to other methods. Oils extracted using this method, are more fragrant (Raut and Karuppayil 2014). There are many EOs used in the dermatologic industry, however for the purpose of the study, lemon and sandalwood oil will be examined in detail.

2.6.2 Lemon essential oil (*Citrus limon*)

Lemon (*Limonene*) is the most common citrus tree crop (Golmakani and Moayyedi 2015; Kejllova *et al.* 2010), belonging to the Rutaceae family (Do *et al.* 2015). Lemon essential oil originates from south eastern China and is extracted via cold expression (Yazgan, Ozogul and Kuley 2019). Lemon oil has astringent properties that stabilise overactive sebum production, thus treating skin problems (Battaglia 2016). Furthermore, it possesses antibacterial, antifungal and antiviral properties with skin protectants (Valgimigli *et al.* 2012).

Lemon essential oils (*Citrus limon*) improve topical absorption and diffusion conditions through the epidermis (Valgimigli *et al.* 2012; Kanlayavattanakul and Lourith 2011). Limonene is a monoterpene hydrocarbon possessing cleaning and antioxidant properties. These properties are suitable for treating skin conditions. Lemon oil contains citric acid, ascorbic acid, minerals and flavonoids beneficial in the treatment of pigmentary conditions (Hojjati and Barzegar 2017). In PIH, lemon oil may result in a lightening effect (Hsouna *et al.* 2017). The citric and ascorbic acid in lemon oil inhibits tyrosinase activity which prevents melanin production (Matsuura, Hiroyuki and Masayoshi 2006). Lemon desquamates cells (Maldonado, Aban and Navarro 2013), breaking down hyperkeratinisation build up in the formation of acne, hence improving the texture of skin (Baghel, Gidwani and Kaur 2017).

2.6.3 Sandalwood essential oil (*Santalum album*)

Sandalwood essential oil (SEO) originates from India and belongs to the Santalaceae family (Jones, Plummer and Barbour 2007). East Indian sandalwood (*Santalum album*) is highly fragrant and is extracted from the Santalum genus tree (Misra and Dey 2013). It is obtained via the distillation process (Kuriakose and Joe 2012) and is stable when blending with other oils. This oil is frequently used for relaxation or sedation (Choi and Park 2016).

Due to its anti-inflammatory and anti-bacterial properties, SEO is used to treat skin diseases (Dozmorov *et al.* 2014). Furthermore, SEO demonstrates elevated effects on keratinocytes, a core component of acne and pigmentation formation (Itoi-Ochi *et al.* 2016). Sandalwood oil acts as an inhibitor of tyrosinase, a key enzyme in melanin formation. Thus, SEO may inhibit pigmentation associated with exposure to UV light (Diaz-Chavez *et al.* 2013). This oil destroys multiplying keratinocytes, suggesting reduced progression of skin disorders (Haque and Coury 2018). Sandalwood essential oil has been found to reduce levels of *P. acnes*, crucial in the formation of acne (Moy and Levenson 2017).

2.6.4 Role of lemon and sandalwood oils in pigmentation

Lemon and sandalwood essential oils demonstrate several beneficial effects on the skin, however, literature surrounding its effects on PIH is still emerging. Sandalwood is known for its moisturising, balancing and cooling effects, while decreasing blemishes (Gite *et al.* 2013), thus reducing sensitivity and irritation from acne and PIH (Dozmorov *et al.* 2014).

Lemon essential oil has been recognised for both its whitening and depigmenting properties (Kole *et al.* 2005), and sandalwood essential oil exfoliates dead skin cells, improves penetration and lightens skin (Thakur, Negi and Kush 2013). Thus, in combination they could compact the processes of PIH as displayed in Figure 2.5. They are safe for use within herbal cosmetics, preservative free and beneficial (Joshi and Pawar 2015).

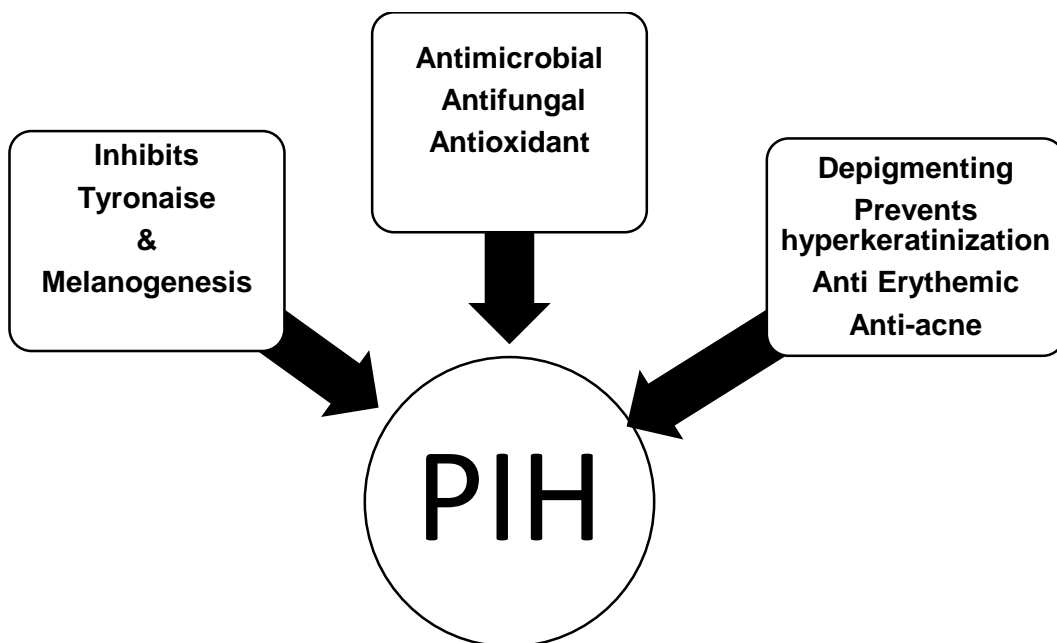


Figure 2.5: Summary of the effects of lemon and sandalwood oil essential oil on PIH

Source: Adapted from Narayanaswamy and Ismail (2015); Kole *et al.* (2005)

Due to the mechanism of actions of lemon and sandalwood oils (Figure 2.4), this study focused on determining if these oils would have an influence on the parameters of the skin, in relation to PIH. Therefore, this study aimed to investigate these influences.

CHAPTER 3: MATERIALS AND METHODS

3.1 Ethical considerations

The study was approved by the Institutional Research and Ethics committee of the Durban University of Technology (DUT) (IREC 62/16: Appendix 1). Gate keeper permission was received from the Director of Research and Postgraduate Support Durban DUT (Appendix 2). Participation was voluntary, and no remuneration was given to participants for their participation. All participants were advised of the anonymity and confidentiality of the data that was collected. Data was only accessible to the researcher, supervisors and statistician.

The details of the study were explained to all recruited participants who agreed to participate (Appendix 3, Appendix 4). Participants confirmed their participation by their signed informed consent (Appendix 5, Appendix 6). Participants were informed that they could withdraw from the study at any point if they wished. All data collected will be stored in a secure cabinet for a maximum period of five years at the Department of Chiropractic and Somatology, Durban University of Technology, and thereafter shredded.

3.2 Study design and setting

This was a prospective, quantitative and double-blinded study with an experimental design. Participants were randomly assigned to experimental and control groups by the supervisor. The study was conducted at the Somatology clinic, Durban University of Technology. A pre-test, post-test method was used. Prior to implementation of the study, the questionnaire was piloted to determine the relevance of questions and identify any redundancies. Participants were included or excluded from the study based on the following criteria.

3.2.1 Inclusion criteria

Participants selected for the study were included based on the following inclusion criteria:

- Participants must be African females
- Participants must be between 18-35 years of age
- Participants that were clinically diagnosed with post inflammatory facial pigmentation by a dermatologist
- Participants that do not react during the 24-hour allergy test

3.2.2 Exclusion criteria

Participants were excluded from the study based on the following exclusion criteria:

- Participants that were part of the pilot study
- Participants that were not African females
- Pregnant or lactating women
- Participants that were on oral contraception
- Participants that were on any oral or topical treatments for pigmentation or skin conditions
- Participants occupations that involve outdoor environments
- All male participants
- Participants that display early signs of menopause

Exclusion of pregnant and lactating woman and woman on oral contraceptives from the study was primarily because these women are more susceptible to the development of pigmentation. According to Ingber (2009), almost all woman, particularly those with darker skin, are predisposed to some degree of pigmentation during pregnancy and when using oral contraceptives. To eliminate this type of pigmentation, these women were excluded from the study. If a participant falls pregnant during the duration of the study, she will be removed from the study.

However, the composition used in the study was not harmful during pregnancy as the oils used in the study are not considered harmful during pregnancy. Battaglia (1997) mentions that essential oils that are toxic during pregnancy are aniseed, basil, clary sage, cypress, sweet and bitter fennel, jasmine, juniper, sweet marjoram, myrrh, nutmeg, peppermint, rose and rosemary.

3.3 Study Sampling and recruitment

The study population included African females aged between 18-35 years who met the inclusion criteria. Purposive sampling was used to identify and recruit participants. The sample size were determined in consultation with a biostatistician as 45 participants ($n = 45$), and the total number recruited was 62, of which 48 completed the protocol.

Recruitment was supported by the placement of advertisements (Appendix 7 [English]; Appendix 8 [IsiZulu]) in both the Ritson and Steve Biko campuses of DUT as well as Durban and surrounding areas. Prospective participants were verbally informed of the study by the researcher and invited to meet for a consultation. During this consult the prospective participants were given the letter of information (Appendix 3 or Appendix 4) and participation confirmed by a signed consent form (Appendix 5 or Appendix 6). Participation was voluntary and no coercion was used to recruit participants.

All interested participants were required to complete a questionnaire (Appendix 9[English]; Appendix 10 [IsiZulu]) and agree to have their affected facial regions photographed. Photographs were used to confirm a clinical diagnosis which was done in consultation with a dermatologist (Appendix 11).

All photographs were taken with a 13 megapixel camera against a specific background (dark coloured towel or sheet) as specified by the consultant dermatologist. Only participants whose facial skin was clinically diagnosed by the consultant dermatologist with post inflammatory facial pigmentation were allowed to continue in the study. Once their participation was confirmed, the participants were followed and re-consulted at 8, 16 and 24 weeks respectively.

3.4 DATA COLLECTION

3.4.1 Allergy testing

Participants who received confirmation of a clinical diagnosis from the consultant dermatologist were then given a 24-hour allergy test. The test was conducted by the researcher and was used to determine the presence or absence of any allergies that participants may have to the selected blends of cream or the sunblock component of the cream (SPF 15). The allergy test was conducted by the researcher on the inner elbow of all participants. Prior to the allergy test, the inner below was cleaned with hibitane and cotton wool, followed by the application of each blend of cream (lemon with aqueous cream or sandalwood with aqueous cream) and the sunblock. The participants were asked to return after \pm 24 hours for an allergy assessment. None of the participants reacted negatively during the allergy testing.

3.4.2 Allocation of experimental products and essential oil blends

The experimental product was a fragrance and preservative free aqueous cream-based cream. A 100ml tub of cream was given to the participants, either plain (control) or combined with 50 drops of lemon oil or sandalwood oil (experimental) which were 100% aromatherapy-based oils.

Following clinical diagnosis and allergy testing the participants were randomly allocated into the following groups:

- **Group 1:** Lemon essential oil blended into aqueous cream (intervention/experimental group)
- **Group 2:** Sandalwood essential oil blended into aqueous cream (intervention/experimental group)
- **Group 3:** Aqueous cream (placebo/control)

All participants were given an Environ RAD[®] SPF 15 sunblock together with the selected cream. The sunblock with SPF15 was selected as the sun protection factor due to its suitable coverage and protection, and to reduce potential allergic reactions (Davis and Callender (2010).

Basic instructions on application of the prepared cream blends was given to the participants to maintain consistency (Appendix 12). The facial skin of all recruited participants were also analysed by the Skin Analyser[®] (LD6021). The analyser machine, which was provided by Upfront Distribution (Durban, South Africa), measures various parameters of the skin such as facial spots, pore sizes, skin roughness, facial wrinkles, UV acne, UV facial spot and UV moisture levels.

A consultation schedule (Appendix 13) was given to all participants in order to maintain adequate follow-ups with the researcher. Follow up consultations included a recording of any visible changes to the participants skin by capturing images using a camera and Skin Analyser[®] (LD6021). Follow up schedules were discussed with and agreed upon by both the participant and the researcher.

3.4.3 Assessment of skin parameters

Post inflammatory hyperpigmentation was assessed at baseline (0 weeks) and thereafter at 8, 16 and 24 weeks based on the measurement of the seven skin parameters as described in Table 3.1. Assessments from the Skin Analyser[®] was used as a point of reference.

Table 3.1: Skin parameters and indicators analysed by the Skin Analyser[®]

Parameters	Indicator
Facial spot	Indicating spot distribution on the surface of the skin. Also showing acne-scarring present on the outer dermis of the skin caused by post acne or inflammatory responses of the skin. This parameter provides a clear indication if there has been improvement of PIH
Pore size	Pore size changes are a good indication if there is improvement or not. Enlarged pores are prominent in acne and PIH skin. Smaller pore sizes presents a smoother appearance
Skin Roughness	Unsmooth areas on the epidermis
Facial Wrinkles	Epidermal expression lines
UV Acne	With acne being the most common cause of PIH, this machine measures the degree of active acne that may be present within the epidermis. Indicative that the skin may be prone to PIH.
UV facial spot	This parameter indicates pigmentation spots in the dermal layer. Measuring the extent of scarring present within the epidermis caused by the sun pre and post treatment. Indicating outer dermis scarring caused by post acne or inflammatory responses of the skin
UV Moisture level	Moisture levels within the epidermis are measured as PIH skin may present with poor moisture levels

3.5 Data analysis

Demographic data obtained from the questionnaire and clinical data obtained from the Skin Analyser[®] machine were used. This data was collected, coded and captured onto a spreadsheet using statistical analysis SPSS (Version 25.0). A p-value < 0.05 was considered a statistically significant result. Data were tested for normality and continuous data was summarised in terms of the mean, standard deviation, minimum and maximum. One-way analysis of variance (ANOVA) and sample t-tests were completed on skin parameters. Findings from the study were triangulated. Data from the questionnaire and Skin Analyser[®] (LD6021) were analysed. The study was analysed using descriptive data obtained from the questionnaire, focusing on lifestyle and skincare data. Comparisons between the parameters and descriptive were presented. The open ended questions from the questionnaire were analysed for the triangulation of data. Changes in the parameters over time were presented graphically and repeated measures ANOVA was used to detect whether there was a significant change over time and if there were treatment differences.

CHAPTER 4: RESULTS

4.1 Demographics and lifestyle characteristics

Sixty-two (n = 62) black African females were recruited for the study, of which 61 were students. Of the 62 recruited, 87.1% (n = 54) were aged between 18-22 years, while 12.9% (n = 8) were aged 23-27 years. With regard to lifestyle characteristics, 75% (n = 47) reported a healthy diet consumption, while only 38% (n = 23) reported the recommended daily water intake. Only 6.5% (n = 4) reported smoking and alcohol consumption. Based on these low numbers data was excluded from further analyses.

Despite the initial recruitment of 62 participants, only 48 completed the study including follow-up consultations. Only 33.9% (n = 19) of the total sample reported waxing as an option of hair removal while 19.6% (n = 11) reported threading as a preference. Furthermore, 42.9% (n = 24) reported the regular use of deep cleanse facials. Notably, 61.7% (n = 29) indicated the use of daily homecare treatments such as cleansers and moisturisers. In contrast, 17.1% (n = 7) indicated that they used some form of pigmentation treatment. In addition, 54.3% (n = 25) reported a family history of pigmentation.

More than half (52%) (n = 25) of the respondents reported acne as a concern, in contrast to pigmentation as a concern. Low self-esteem was highlighted as a consequence in 9.84% (n = 4) of the study population. Less than half (37.70%) (n = 8) of the respondents indicated that pigmentation onset occurred during their adolescence years, while 47.54% (n = 22) reported a later onset. Acne scarring was the leading pigmentation contributor (88.6%) (n = 42) within this population. Although the incidence of pigmentation occurred at various stages, self-reports suggested that pigmentation had gradually improved over time (78.7%) (n = 37).

4.2 Bivariate analysis between skin parameters, skincare regimen and family history of PIH

Bivariate analyses were completed between skin parameters and basic homecare skincare regimen (cleanser, toner and moisturiser), prior use of pigmentation treatments, and family history of pigmentation. Pre-parameter percentages were compared to post-parameter percentages to determine differences. Results that indicated a negative result showed that the post-measurement was greater than the pre-measurement, thus reflecting a decline in parameter improvement.

There were no significant differences observed between those on a daily regime compared to those who were not (Table 4.1). However, a statistically significant difference was noted with regard to change in UV acne ($p = 0.033$) among those who used prior pigmentation prescriptions compared to those not on prescriptions. More than half (54.3%) of the respondents indicated that a family history of pigmentation influenced the incidence of their pigmentation. Despite the lack of statistical significance, there was a noticeable difference in UV moisture levels of both oils with those that had a family history of pigmentation.

Table 4.1: Participant skin care management and family history (pigmentation)

Skin parameter	on homecare (mean±SD)	p-value	no homecare (mean±SD)	p-value
Facial spot	8.44 ±22.75	0.865	9.55 ±19.51	0.860
Pore size	8.75 ±14.36	0.642	6.83 ±13.25	0.648
Skin roughness	-.27 ±15.93	0.522	2.05 ±8.79	0.573
Facial wrinkles	2.65 ±15.14	0.159	9.44 ±16.06	0.151
UV acne	-2.06 ±20.28	0.760	-0.61 ±12.23	0.785
UV facial spot	9.58 ±23.83	0.356	4.44 ±13.96	0.411
UV moisture level	4.72 ±14.82	0.692	3.27 ±10.05	0.717
Skin parameter	prior PIH treatment(mean±SD)	p-value	no prior PIH treatment (mean±SD)	p-value
Pigmentation treatment used previously				
Facial spot	0.00 ±16.29	0.399	7.76 ±22.80	0.309
Pore size	6.85 ±11.37	0.987	6.76 ±13.84	0.985
Skin roughness	-1.7 ±5.55	0.849	-0.61 ±14.75	0.742
Facial Wrinkles	8.28 ±18.29	0.544	4.14 ±15.91	0.593
UV acne	9.00 ±11.10	0.098	-0.344 ±18.61	0.033*
UV facial spot	7.85 ±14.39	0.899	6.70 ±22.73	0.866
UV moisture level	4.85 ±12.86	0.773	3.23 ±13.54	0.770
Skin parameter	family history of PIH (mean±SD)	p-value	no family history (mean±SD)	p-value
Family history of pigmentation				
Facial spot	6.16 ±22.79	0.733	8.23 ±17.26	0.727
Pore size	6.48 ±13.26	0.861	7.14 ±12.06	0.860
Skin roughness	1.80 ±10.84	0.737	0.619 ±12.86	0.741
Facial wrinkles	5.52 ±11.63	0.870	4.76 ±19.33	0.876
UV acne	-2.56 ±19.39	0.640	-0.09 ±15.31	0.633
UV facial spot	8.08 ±20.54	0.766	6.23 ±21.13	0.767
UV moisture level	6.92 ±16.56	0.086	0.285 ±5.32	0.069

**p* < 0.05 was considered statistically significant

4.3 Photographic evidence

Physical changes of the skin were observed between treatment groups as shown in Figures 4.1-4.3 (a-f). An overall improvement was observed in skin pore sizes, texture as well as an overall reduction in PIH facial features amongst those who used the lemon oil (Figure 4.1) and sandalwood oil treatment (Figure 4.2).

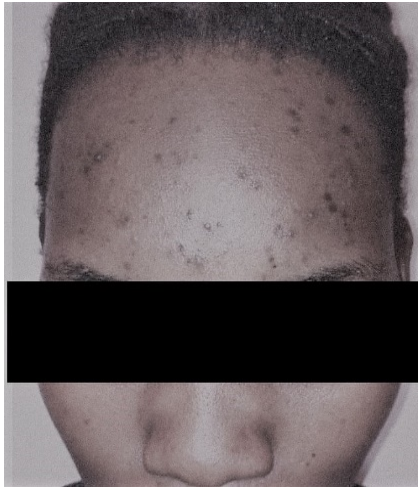
In addition, improvements in skin pore sizes and texture was also observed amongst those who were in the control group (Figure 4.3). This could be attributed to the presence of SPF. Our data highlights a visible reduction in the appearance of skin pigmentation and acne in both experimental groups.

4.3.1 Lemon treatment group

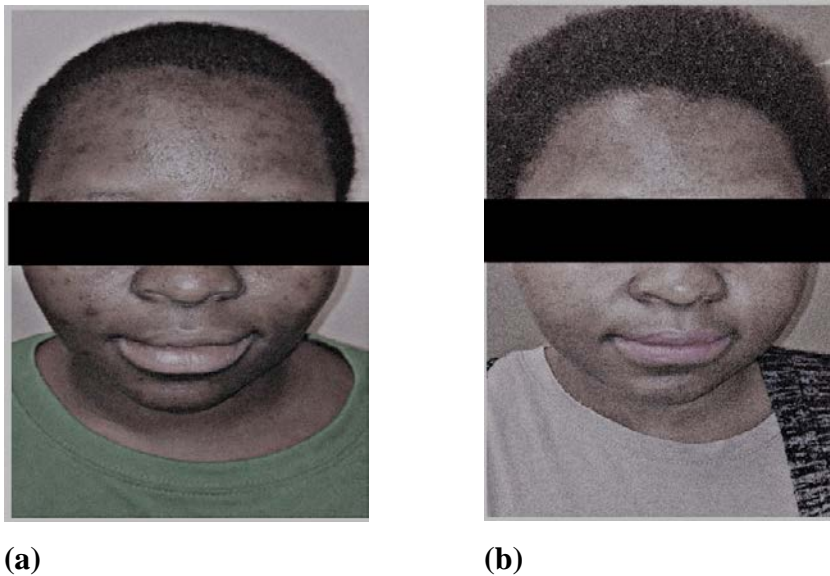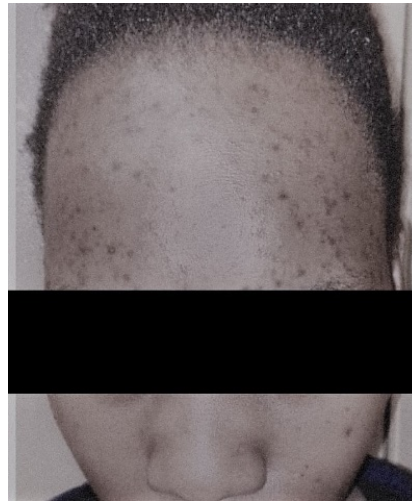


Figure 4.1: (a) Image illustrating the facial appearance at baseline (0 weeks), (b) Image illustrating post treatment improvements with the visual characteristics of the skin in the lemon treatment group.

4.3.2 Control group



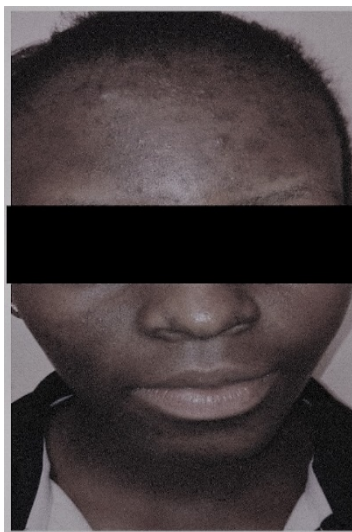(c)



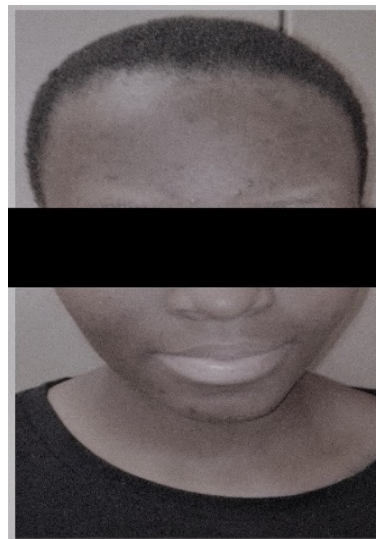
(d)

Figure 4.2: (c) Image illustrating the facial appearance at baseline (0 weeks), (d) Image illustrating post treatment improvements with the visual characteristics of the skin in the control (aqueous cream and SPF)

4.3.3 Sandalwood treatment group



(e)



(f)

Figure 4.3: (e) Image illustrating the facial appearance at baseline (0 weeks), (f) Image illustrating post treatment improvements with the visual characteristics of the skin in the sandalwood treatment group

4.4 Descriptive analyses of the skin parameters

Sample t-tests were used to provide before and after comparisons for the lemon and sandalwood study groups. These comparisons were made to the control group from 0 weeks (baseline) to 24 weeks (post treatment). The mean and standard deviation (mean \pm SD) for lemon (Table 4.2) and sandalwood oil (Table 4.3) are displayed below. Significant improvements was observed for facial spots amongst those who used the lemon treatment ($p = 0.047$) and sandalwood oil ($p = 0.050$). Similarly pore sizes were also significantly reduced in lemon oil ($p = 0.021$) and sandalwood oil ($p = 0.009$) in contrast to the control (Table 4.2 & Table 4.3). Statistically significant results were noted on the UV spots ($p = 0.050$). Facial wrinkles also demonstrated a significant difference ($p = 0.005$), indicating a reduced appearance of wrinkles in those using lemon oil.

Table 4.2: Evaluation of skin parameters at baseline (0 weeks) and post treatment (24 weeks) amongst those using the lemon treatment (n = 15)

Parameter	Baseline mean \pm -SD (0 weeks)	Control (aqueous cream and SPF) mean \pm SD (0 weeks)	Control (aqueous cream and SPF) mean \pm SD (24 weeks)	Lemon essential oil mean \pm -SD (24 weeks)	<i>p</i> - value
Facial spot	68.67 \pm 21.24	64.60 \pm 20.85	58.67 \pm 22.68	59.06 \pm 20.61	0.047*
Pore size	70.94 \pm 17.12	73.60 \pm 15.88	68.80 \pm 18.17	62.56 \pm 19.87	0.021*
Skin roughness	87.17 \pm 19.44	84.47 \pm 25.70	87.20 \pm 15.85	87.94 \pm 17.04	0.772
Facial wrinkles	80.44 \pm 17.78	72.27 \pm 20.05	66.87 \pm 20.61	70.33 \pm 21.69	0.005*
UV acne	16.44 \pm 14.91	16.87 \pm 14.98	23.53 \pm 23.67	17.50 \pm 20.92	0.783
UV facial spot	81.72 \pm 23.20	88.73 \pm 15.32	83.33 \pm 18.48	76.28 \pm 25.45	0.345
UV moisture lev	93.61 \pm 7.95	95.53 \pm 0.743	91.93 \pm 10.07	93.22 \pm 7.04	0.816

* $p < 0.05$ was considered statistically significant

Table 4.3: Evaluation of skin parameters at baseline (0 weeks) and post treatment (24 weeks) amongst those using the sandalwood treatment (n = 15)

Parameter	Baseline mean \pm SD (0 weeks)	Control mean \pm SD (aqueous cream and SPF) (0 weeks)	Control mean \pm SD (aqueous cream and SPF) (24 weeks)	Sandalwood essential oil mean \pm SD (24 weeks)	p- value
Facial spot	63.67 \pm 25.92	64.60 \pm 20.85	58.67 \pm 22.68	53.53 \pm 22.37	0.050*
Pore size	83.80 \pm 12.92	73.60 \pm 15.88	68.80 \pm 18.17	73.07 \pm 13.68	0.009*
Skin roughness	90.93 \pm 13.19	84.47 \pm 25.70	87.20 \pm 15.85	85.33 \pm 11.88	0.166
Facial wrinkles	71.27 \pm 21.59	72.27 \pm 20.05	66.87 \pm 20.61	72.53 \pm 22.49	0.773
UV acne	18.27 \pm 17.61	16.87 \pm 14.98	23.53 \pm 23.67	15.40 \pm 8.95	0.561
UV facial spot	90.80 \pm 10.83	88.73 \pm 15.32	83.33 \pm 18.48	78.87 \pm 22.22	0.050*
UV moisture lev	94.07 \pm 6.79	95.53 \pm 0.743	91.93 \pm 10.07	85.07 \pm 18.53	0.088

* $p < 0.05$ was considered statistically significant

4.5 Effect of lemon and sandalwood essential oil on skin parameters

Skin parameters were evaluated at baseline (0 weeks) and thereafter at 8, 16 and 24 weeks (post-treatment). Differences between the baseline and post-treatment were analysed to determine any significance. Analysis demonstrated the effect of lemon and sandalwood oil on the various skin parameters as shown in Table 4.4. Despite the lack of statistical significant an improvement ($p = 0.11$) was noted in the pore size amongst those with lemon oil. Similarly, a noticeable improvement was noted in facial spots among those treated with lemon oil. In contrast a significant difference ($p = 0.015$) was observed in pore size amongst those on sandalwood treatment. Improvements in the appearance of facial spots among those treated with sandalwood oil were also observed in those treated with the sandalwood treatment.

Table 4.4: Effects of lemon and sandalwood essential oil on skin parameters

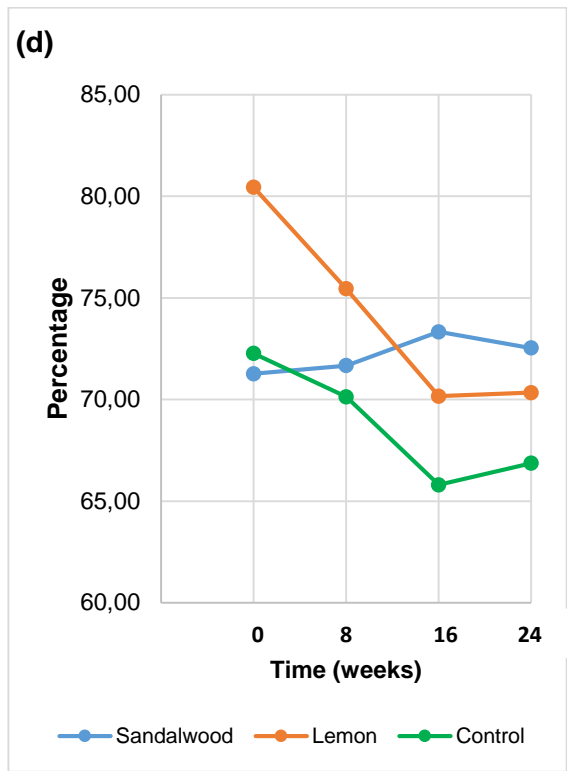
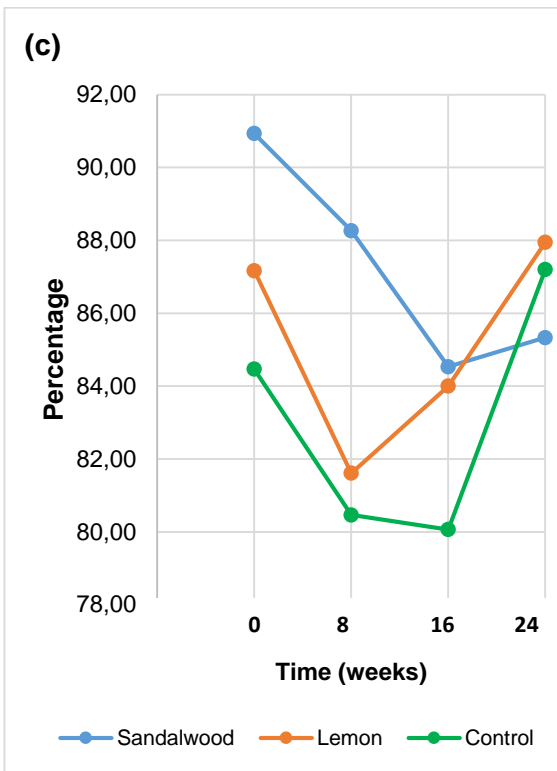
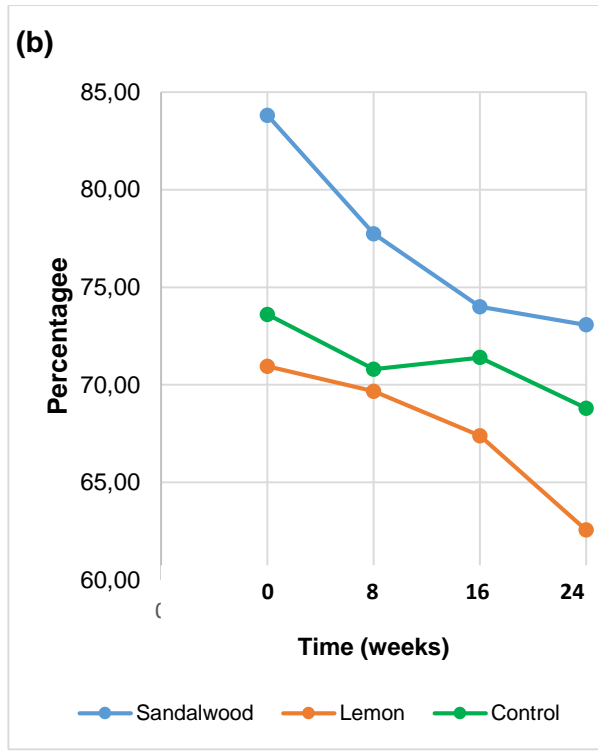
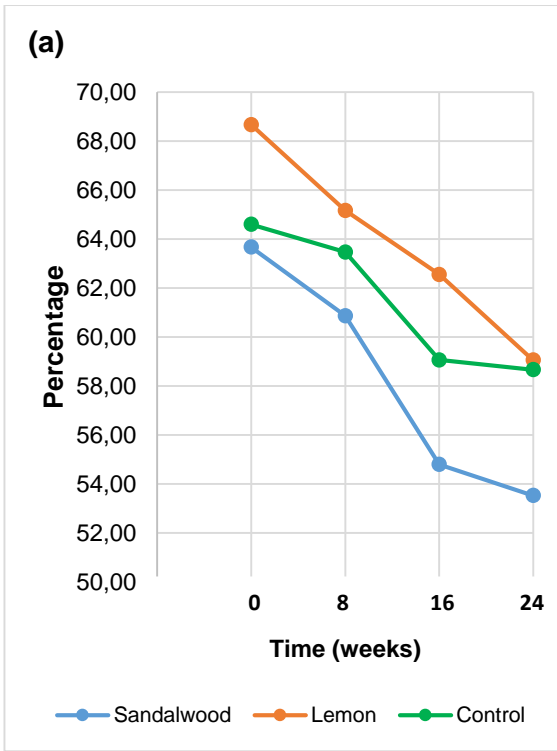
Parameter	BASELINE	POST-TREATMENT			<i>p</i> -value
	Mean% ±SD (0 weeks)	Mean% ±SD (8 weeks)	(16 weeks)	(24 weeks)	
Lemon essential oil					
Facial spot	68.67 ±21.24	65.17 ±19.04	62.56± 19.40	59.06 ± 20.61	0.76
Pore size	70.94 ±17.12	69.67 ±13.97	67.39 ±15.62	62.56 ± 19.89	0.11
Skin roughness	87.17 ±19.44	81.61 ±14.15	84.00 ±11.39	87.94 ± 17.04	0.735
Facial wrinkles	80.11 ±17.78	75.44 ±14.83	70.17 ±18.22	70.33 ± 21.69	0.249
UV acne	16.44 ±14.91	16.94 ±13.81	16.61 ±16.42	17.50 ± 20.92	0.979
UV facial spot	81.72 ±23.20	80.72 ±20.43	79.78 ±18.63	76.28 ± 25.45	0.906
UV moisture level	93.61 ±7.95	90.78 ±6.35	90.11 ± 7.85	93.22 ± 7.04	0.605
Sandalwood essential oil					
Facial spot	63.67 ±25.92	60.87±21.32	54.80±19.80	53.53 ± 22.37	0.068
Pore size	83.80 ±12.92	77.73±11.48	74.00±9.87	73.07 ±13.68	0.015*
Skin roughness	90.93 ±13.19	88.27±8.63	84.53±5.76	85.33 ±11.88	0.131
Facial wrinkles	71.27 ±21.59	71.67±18.99	73.33±20.73	72.53 ± 22.49	0.925
UV acne	18.27 ±17.61	20.33±13.52	17.93±8.47	15.40 ± 8.59	0.593
UV facial spot	90.80 ±10.83	84.20±10.45	79.73±16.64	78.87 ± 22.22	0.25
UV moisture level	94.07 ±6.79	88.67±10.33	86.40±12.76	85.07 ± 18.53	0.91

**p* <0.05 was considered statistically significant when compared to the control group

4.6 Changes in skin parameters over time among all groups

Variations in skin parameters among those treated with lemon oil, sandalwood oil and the control groups at different consultations, are shown in Figure 4.3 (a-g). There was a statistical improvement ($p = 0.007$) in facial spots with those on the sandalwood treatment in contrast to those treated with lemon oil. Similarly, the pore size skin parameter demonstrated statistical significance ($p = 0.001$) in those treated with sandalwood oil in comparison to those on lemon oil.

Sandalwood oil showed a statistically significant difference ($p = 0.001$) in reducing skin roughness in comparison to those treated with lemon oil. Although the lemon treatment oil showed improvement, skin roughness increased over time. In contrast, the occurrence of facial wrinkles was significantly reduced ($p = 0.031$) among those on the lemon treatment compared to sandalwood oil. Significant quadratic changes were observed for all UV factors among those treated with sandalwood oil. Improvements were further noted in UV acne incidence ($p = 0.022$), while UV spots showed a significant difference ($p = 0.133$). UV moisture levels within the skin also displayed improvements ($p = 0.209$).



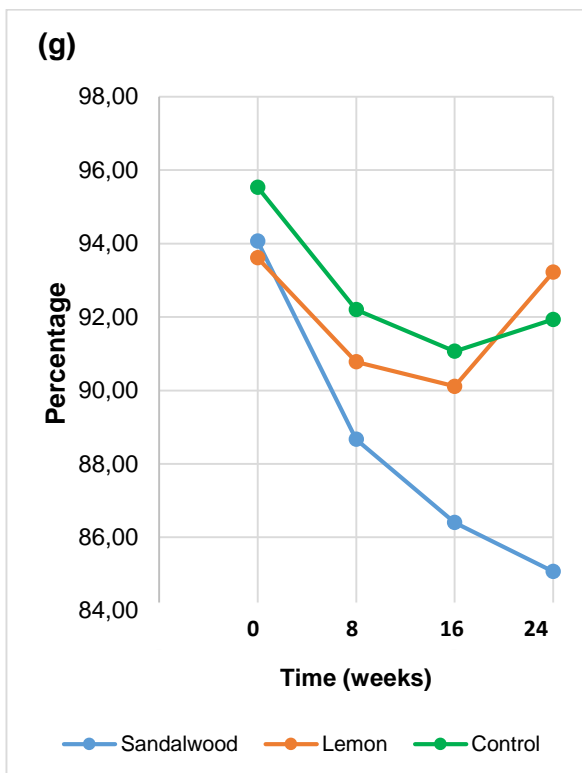
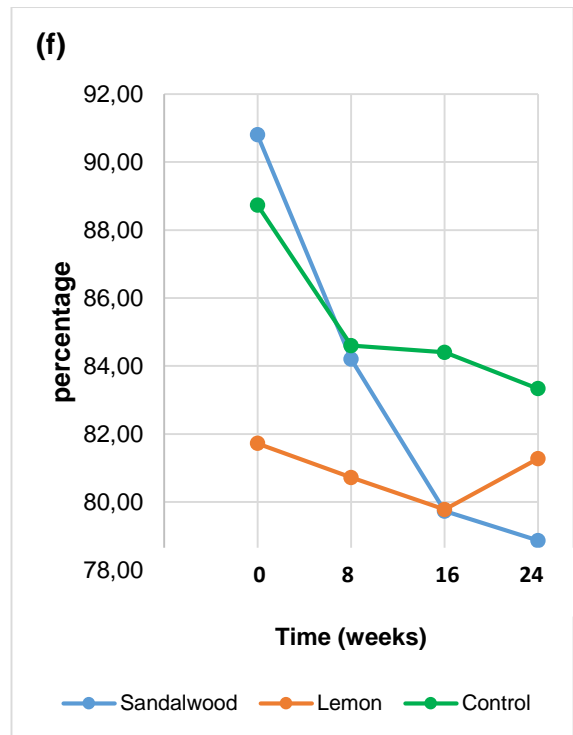
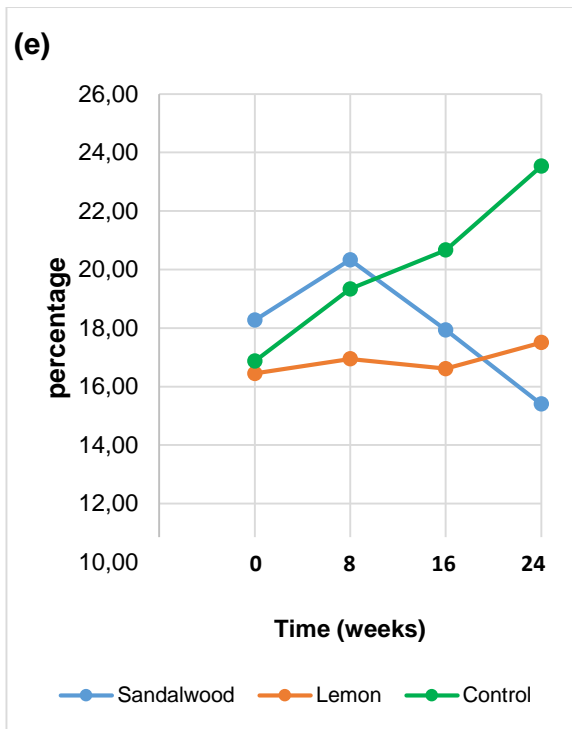


Figure 4.4: Graphs illustrating the changes in the percentages of the skin parameters over time in the treatment and control groups, (a) facial spot, (b) pore size, (c) skin roughness, (d) facial wrinkles, (e) UV acne, (f) UV spot, (g) UV moisture

CHAPTER 5: DISCUSSION

5.1 Demographic and lifestyle characteristics

This study evaluated the effectiveness of lemon and sandalwood essential oils in the treatment of post-inflammatory pigmentation, in an attempt to determine their impact on PIH progression. Our study highlights the incidence of PIH among our study population who were black female students aged 18-22 years. This may be attributed to our study location within a university. Reports suggest that the majority of students enrolled at a university are between 18-22 years of age (Mallman and Lee 2017; Sitek, Żądzińska and Rosset 2012). The prevalence of common factors that influence the onset of PIH such as age, race and increased hormonal factors are high within this cohort, endorsing their susceptibility to PIH development.

In our population, the prevalence of acne was 83%. A key contributor to PIH development was acne. Acne affects over 90% of adolescents and can persist into adulthood (Fabbrocini *et al.* 2010). A recent report suggested that both psychological and social outcomes affects almost 85% of people with acne aged between 12-24 years (Luqman *et al.* 2019).

A large proportion of our population presented with acne, which was similar to that reported by Sitek, Żądzińska and Rosset (2012). Sitek's group emphasised that career choice decisions combined with financial and family problems are common emotional contributors to PIH development and progression within this age group. This age group is also more vulnerable to being young parents and increased contraceptive use (Kubiak and Rotsztein 2012). The use of contraceptives is associated with increased melanin production, which consequently results in PIH development (Eliason *et al.* 2014).

Increased melanin production is a contributing factor for various pigmentary disorders, including PIH (Mahdalena, Jusuf and Putra 2018; Natale *et al.* 2016). Of note, hormones involved in pregnancy progression exert similar effects on non-pregnant females (Kubiak and Rotsztein 2012), hence, we excluded pregnant woman and woman on contraception from this study. Although pregnant women were excluded from the study, 20% of participants were already young mothers and therefore presented with existing pigmentation.

Pigmentation is common among females (Pang *et al.* 2014), suggesting that hormonal changes may be involved (Hernando *et al.* 2016). Moreover, during this age period, contraceptives are often used by females, which may predispose them to PIH (Eliason *et al.* 2014). Earlier reports suggest that emotional, physical and hormonal changes are also prevalent during this transitional period between adolescence to adulthood (Dahl and Forbes, 2010), which may predispose them to PIH development.

Our data also highlights waxing as the preferred hair removal method, in contrast to threading. Waxing compared to other hair removal methods, is a more cost effective and quick and is a more easily accessible option. However, waxing predisposes many women to inflammation, blockage of pores, and burns, which can subsequently lead to PIH (DeMaria *et al.* 2014). Inflammatory outbreaks consequently increase bacterial growth resulting in comedone formation (Vaishnani 2015; Fabbrocini *et al.* 2010). Skin irritation arising from waxing frequently accompany PIH, particularly in Fitzpatrick skin types V and IV, as a result of increased epidermal melanocytes (Ho *et al.* 2011; Goldberg 2006). Based on this premise, waxing may be directly associated with PIH development (Williams and Almasi 2005).

However, limited studies are available to confirm these associations as much evidence is linked to anecdotal reports arising from local spas and clinics. It is thus possible that the increased incidence of pigmentation in our study may be associated with the higher usage of waxing as a hair removal option. Wax prepping factors such as skin preparation, wax temperature and the method of wax removal, must be considered when avoiding the development of such inflammatory responses (Dendle *et al.* 2007).

Furthermore, preventing excessive sun exposure and sweating following waxing is essential in order to reduce and prevent unnecessary skin reactions. An earlier report confirms that reduced skin inflammation is linked to consistent usage of sun protectors and decreased or minimal sun exposure (Marza 2014). Laser and intense pulsed light systems are also treatment modalities for removal of unwanted hair (Thaysen-Petersen *et al.* 2014). However, several reports suggest that laser treatments often result in the initiation and progression of pigmentation, thereby limiting its use.

Melanin attracts the heat energy from lasers; this energy is then absorbed by the melanin into the hair follicle thus creating further pigmentation (Chandrashekar, Shenoy and Madura 2019; Thaysen-Petersen *et al.* 2017; Leok 2010; Chaowattanapanit *et al.* 2017). However, the newer long-pulsed laser treatments have been declared as safe and effective modalities for use in dark-skinned people with PIH (Bibilash *et al.* 2017; Ismail 2012). This data is consistent with recent findings by Passeron *et al.* (2019), who reported reduced PIH occurrence among those who opted for long-pulsed laser treatments.

Despite the potential value of laser treatments in improving PIH, its access is limited due to high costs, frequent follow up consultations and the potential risk of inducing or worsening PIH (Landau *et al.* 2011). In our study, this type of treatment remains inaccessible due to the increased costs associated consultations and follow ups.

Our data highlights a 55% occurrence of pigmentation among the family members of most participants, but we were unable to diagnose visible familial pigmentation in our cohort as we exclusively observed PIH incidences triggered by skin trauma (Patel 2015). However, studies have shown that hereditary or genetically transferred pigmentation may be confined to the periorbital regions, with familial progressive hyperpigmentation being prominent in infants (Piqueres-Zubiaurre *et al.* 2017; Sarkar *et al.* 2016).

The main activation pathways for PIH are skin trauma are friction, eczema, psoriasis, drug reactions, skin infections and sunburn (Patel 2015). However, reports suggest a higher PIH prevalence among those previously diagnosed with familial pigmentation due to the inheritance of higher levels of melanocytes (Bino, Duval and Bernerd 2018). These individuals may also have a higher incidence of other pigmentary disorders in addition to PIH (Baxter and Pavan 2013). Our study was however limited in that questions related to pigmentation could have been misinterpreted during data collection.

Homecare regimes were highlighted as daily skincare routines by most participants, however, the product details were unreported for further evaluation. While homecare regimes and over-the-counter preparations were routinely accessed/used by most participants, there was still 38% of the participants who reported no skincare regimes.

The effectiveness of homecare regimens are, however, dependent on the quality of ingredients within the preparations purchased. Surber and Kottner (2017) emphasised the importance of correct homecare regimens in contributing to a healthy skin appearance and reducing PIH. It is possible that the homebased skincare preparations used by our participants contained prohibited ingredients, such as HQ, which may predispose them to skin disorders (de Mendonca *et al.* 2014).

The popularity of products containing such ingredients are increasing, especially in dark skinned woman (Dlova *et al.* 2014). It is possible that many are desperate to reduce uneven skin tone and darkening caused by PIH, regardless of their limited knowledge of the product ingredients. Our data concurs with current global trends, whereby dark-skinned women are preferring lighter skin complexions (Marway 2018, Shroff, Diedrichs and Craddock, 2018). The use of skin fairness products containing toxic ingredients is increasing at an alarming rate as a result of societal expectations, despite it being associated with adverse health side effects.

Anecdotally, homecare products are known to contain lower percentages of active ingredients compared to commercial products. While it may have beneficial effects on overall skin appearance, the knowledge of the precise ingredients in these products are necessary when treating PIH (Clark and Sivamani 2016). Unprescribed products are reported to increase the progression of most PIH disorders (Grippaudo and Di Russo 2016).

Furthermore, adherence to homecare remedies can be challenging for the age group of our study, due to limited financial income. Dhadhal (2015) suggested that product price and discount availability were key factors when considering the purchase of cosmetic products and not specific ingredients.

Some participants reported an improvement in their PIH appearance over the years, possibly indicative of improved treatment adherence. However, Kamagaju *et al.* (2016) suggested that homecare preparations could potentially contain banned substances such as HQ and mercury, which are harmful to the structure and physiology of the skin. Moreover, prolonged exposure to HQ and mercury increases the risk of contact dermatitis, nail discoloration and excessive skin darkening (Bandyopadhyay 2009).

The possibility that certain constituents within these products inhibit melanin production is high, since skin color is usually the most observable feature that is anecdotally referred to rather than skin structure. Much concern arises since these preparations may also increase the risk of skin burns, epithelial thinning and skin darkening (de Mendonca *et al.* 2014; Hendon *et al.* 2014; Jennifer *et al.* 2012).

5.2 Acne and sunburn as common PIH contributors

5.2.1 Acne

Our study demonstrated a reduction in the appearance and features of UV acne among those that were on prior treatment in contrast to those that were not. Cutaneous injuries and inflammation such as acne often lead to PIH (Callender *et al.* 2011). Acne is characterised by large sebaceous glands and increased sebum production. Acne was found mainly around the face and on the upper trunk regions in our cohort. Our data concurs with Tanghetti *et al.* (2014) who found similar characteristics in their cohort.

Post-acne pigmentation and pigmented scars are usually outcomes of acne scarring (Al Qarqaz and Al-Yousef 2018). In our cohort, varying stages of acne and observable scarring was noted. Scarring, particularly on the facial regions is associated with reduced self-confidence which subsequently affects the quality of life. This consequently affects the morale of the affected individual resulting in low self-esteem and poor self-confidence (Thompson 2015).

While acne scarring can be removed, it requires much patience, appropriate treatment and sufficient time for the process to be successful. Our data corroborates several others who demonstrated associations between acne, PIH and low self-esteem (Thompson 2015; Jiang *et al.* 2018:35). These reports identify PIH sufferers as experiencing decreased self-confidence, self-esteem, and increased self-consciousness due to the noticeability of their condition. The ability to control the incidence of acne will subsequently reduce PIH development and its widespread physiological and social consequences (Abad-Casintahan *et al.* 2016).

Treatment control measures should target melanin production, which will subsequently prevent the onset of acne. Our study cohort included young females whose acne could be attributed to hormonal imbalances following puberty and their transition into adulthood.

PIH is reported to be a direct effect of acne (Degitz and Ochsendorf 2017). Moreover, acne development involves increased sebum production, hyperkeratinisation of the sebaceous ducts, colonisation by *P. acnes*, thus resulting in inflammation and PIH. Our data highlighted the presence of mild to severe active acne present on the facial and neck regions of some participants. These observations corroborates various others (Nouveau *et al.* 2016 and Degitz and Ochsendorf, 2017).

While acne affects approximately 85% of adolescents, as a result of puberty, changes in hormonal secretions, skin pH levels, anxiety and diet may also be contributing factors (Qidwai *et al.* 2017; Magin *et al.* 2006). Thus, the onset of acne may not be confined to physiological processes (Degitz and Ochsendorf 2017). While puberty and hormonal changes were potentially instrumental in the initiation of PIH in our cohort, climate may also be involved as data was collected at various times of the day and throughout the year in all seasons.

5.2.2 Sunburn

Our study revealed sunburn as a possible contributor to PIH. Participants reported severe progression of their PIH when exposed to the sun. Exposure to the sun increases the production of vitamin D, which also depends on melanin for its production (Felton *et al.* 2016). Melanin synthesis occurs through the absorption and distribution of both UVA and UVB rays into the skin (Swalwell *et al.* 2012).

Hence, increased melanin levels in dark skinned people predisposes them to absorb more UV rays (Bonilla *et al.* 2014). The effects of the blue light (modern technology) on skin pigmentation has recently emerged, however there is no literature supporting these effects.

The South African summer temperatures create unfavourable conditions for PIH patients (Wright *et al.* 2017). Ultraviolet radiation triggers uneven pigmentation in the skin (Young *et al.* 2009). Thus, it is possible that our participants who were mostly dark skinned may have been exposed to increased UV rays, which resulted in increased skin pigmentation. Sun protection is therefore highly recommended in the treatment of PIH, since it prevents its progression by protecting the skin against these harmful rays (Scheinfeld 2007).

While the use of sun protection especially in the South African climate is well publicised, its awareness may be limited within the broader community. This lack of awareness may be a contributing factor in our cohort since many participants indicated an aggravation of their PIH during summer. However, it is also possible that those who may have used homecare remedies which potentially contained banned substances, increased their susceptibility to sunburn due to UV sensitivity.

Our data is in accordance with several others (Nordlund 2007; Moshhammer, Simic and Haluza 2017) whose research showed that prohibited substances promote sunburn by thinning the outer layers of the skin, increasing sun exposure, thus promoting skin darkening. Others have also demonstrated that PIH is worsened among those not using sunblock, especially when exposed to the sun during summer months (Ruvolo *et al* 2018), which is also consistent with our results.

Our study found a high incidence of sunburn in the cohort of black African students. Dark skinned individuals are probably more susceptible to sunburn and PIH development. Several others report similar findings, suggesting that excess sun exposure results in severe sunburn and skin pigmentary disorders (Rodrigues and Pandya 2015, Nestor *et al.* 2014; Eimpunth, Wanitphadeedecha and Manuskiatti 2013). Incorporating SPF creams into daily regimens is essential in decreasing the progression of PIH. In our study, we provided RAD[®] (SPF 15), by Environ to all participants.

This brand of sunscreen contains antioxidants which protects the skin against harmful environmental factors (Environ Skincare 2013). In addition, the noticeable therapeutic effects of RAD[®] in our control group may be linked to the antioxidant effects of the SPF, which provided UVA/B protection to all participants. Both UV A and UV B rays are key factors in PIH development and its progression (Wright *et al.* 2017). Sun protection against these rays mainly involves topically applied antioxidants, which prevents the penetration of harmful rays (Ebanks, Wickett and Boissy 2009). In addition, the antioxidants minimise the oxidative process of melanin production by inhibiting UV ray absorption (Sondenheimer and Krutmann 2018).

5.3 The influence of Lemon and sandalwood oil on skin parameters

Overall, visible improvements were demonstrated in the skin for both oils utilised in our study. We observed significant physiological changes in the pore sizes for both oils, as well as improved pore conditions with fewer enlarged and blocked pores. Thus, both groups showed a reduction in the prevalence of comedones and acne. Our data thus suggests that both oils may have a potential role in decreasing the development of acne and PIH. Several studies support the astringent and lightening properties that lemon oil exerts on the skin, however, none of them elaborate their physiological mechanisms on pore size (Battaglia 2016; Valgimigli *et al.* 2012; Perdones *et al.* 2012). Lemon has also been identified as an effective penetration enhancer for topical preparations, thereby enabling maximum penetrative effects of the preparation (Dosoky and Setzer 2018).

Lemon oil naturally possesses anti-browning properties, thereby inhibiting tyrosinase in the early stages of melanin formation (Lante and Tinello 2014). Sandalwood oil is also reported to inhibit the biosynthetic pathway of tyrosinase required for melanin production by improving anti-inflammatory properties and suppressing the pathway of phenols to melanin (Moy and Levenson 2017). Sandalwood oils are antimicrobial and antiproliferative, thus promoting acne prevention and reduced PIH progression. Therefore, both lemon and sandalwood oil demonstrate properties that reduces PIH by acting as tyrosinase inhibitors in the primary stage of melanin formation.

The penetrative properties in lemon oil enables effective saturation of active products into the skin, while the cleansing features supports unclogging of blocked pores thereby improving product penetration (Kunicka-Styczynska, Sikora and Kalemba 2011). In addition, the acidity in lemon desquamates cells (Maldonado, Aban and Navarro 2013), suggestive of its inhibitory effect on hyperkeratinisation and prevention of acne formation (Baghel, Gidwani and Kaur 2017).

Our data demonstrated an overall improved skin texture for those treated with lemon oil, thereby supporting its use for the treatment and management of acne and PIH, concurring with various others (Valgimigli *et al.* 2012; Kanlayavattanakul and Lourith 2011, Dupuy *et al.* 2011).

Thus, pore size improvements in our study may be associated with the increased absorption effects of lemon oil and increased penetration. It is possible that the reduced pore size was also indicative of the restricted environment for bacterial growth and comedone formation. The improved pore size observed in our study limits the development of acne (blocked pores), therefore reducing PIH development.

Additional data testing demonstrated noticeable improvements in the physiology and appearance of the skin over time. While some parameters displayed consistent improvements, others revealed improvements followed by PIH worsening before improving again. These PIH progression patterns were similar to those reported by Anbar *et al.* (2016).

Our data highlighted that both lemon oil and sandalwood oil demonstrated an overall improved skin texture and appearance over time. While lemon oil positively improved the appearance of wrinkles, sandalwood significantly improved the sizes of facial spots and pore sizes. The presentation of skin roughness was also notably reduced for sandalwood oil in contrast to lemon oil. There was an overall improvement for all UV factors. Our results concur with others (Itoi-Ochi *et al.* 2016; Sharma *et al.* 2018; Thakur, Negi and Kush 2013), who support the characteristics and actions of lemon and sandalwood in improving the overall skin appearance.

Although many reports indicate numerous cosmetic benefits, there is a paucity of literature regarding the direct effects of sandalwood essential oil and its effects on PIH. However, sandalwood oil is known for treating skin diseases and acne (Dozmorov *et al.* 2014) due to its anti-inflammatory properties (Itoi-Ochi *et al.* 2016) which reduce acne inflammation and calm the skin. These properties result in less redness, inflammation and breakouts.

Therefore, due to the beneficial properties of sandalwood, it may be assumed that sandalwood may reduce the appearance of PIH and possibly inhibiting its progression. Sharma *et al.* (2018), confirmed that by targeting the mechanisms of acne, the development and progression of PIH is managed. Both lemon and sandalwood essential oils have been explored and found to exfoliate dead skin cells, lighten skin and reduce skin irritation (Thakur, Negi and Kush 2013), thus improving skin health. Due to these independent properties of both oils, the combination of lemon and sandalwood essential oil may be beneficial in combating PIH and its effects.

CHAPTER 6: CONCLUSIONS AND RECOMMENDATIONS

6.1 Conclusions

This study investigated the use of lemon and sandalwood essential oils in the management of PIH. Our data highlights the effectiveness of both oils over a 24 week period. Furthermore, we compared the findings of the two oils to determine which oil demonstrated superior results. Our findings demonstrated unique characteristics of each oil that targeted the various elements of PIH.

Our data demonstrates that the two oils worked differently in progression of PIH. The high levels of vitamin C found in lemon oil may have contributed to the reduction of the tyrosinase enzyme responsible for melanin production and synthesis. The bleaching effect of these oils reduced tyrosinase levels, thereby preventing further darkening of the skin. These oils prevented the hyperkeratinisation process thus allowing penetration of the treatment into the epidermis. Both oils also potentially prevented hyperkeratinisation which subsequently improved skin conditions. The saturation of treatment product resulted in a smoother and clearer skin.

Both treatments, decreased the incidence of acne and the formation of PIH. Similarly, Sandalwood oil also worked very well to improve the various skin parameters. The sizes of acne spots were significantly reduced, due to the anti-inflammatory properties found in sandalwood oil, aiding in the reduced presentation of PIH. Penetration levels were considerably improved as well as the condition of the pores. This resulted in pores becoming unblocked and decreasing in size indicating improved penetration and a smoother skin appearance.

Sandalwood oil also had a positive benefit to all UV skin parameters. These included UV acne, UV spot and UV moisture levels in the skin. The soothing and anti-inflammatory properties of sandalwood prevented further irritation and breakouts while simultaneously improving penetration conditions. This enabled treatment product to be well absorbed into the skin, improving overall skin appearance.

UV moisture levels increased demonstrating sandalwood oil as an emollient barrier, preventing transepidermal water loss in the skin, as a result showing significant improvements in the condition of skin roughness. Due to acne and acne scarring being the main cause of PIH, sandalwood validated its effectiveness by considerably reducing these features hence reducing the incidence of PIH.

It is also noted that the control group showed significant improvements in their overall skin appearance. These improvements can possibly be attributed to the sunblock used in the study. The RAD[®] by Environ contains antioxidants that have been proven to reduce the harsh effects of PIH. In addition, RAD[®] also contains vitamin A that encourages cell renewal and restoration, which is vital for post acne scarring. In conclusion, the combination of both oils incorporated into one treatment product may enhance results as the lemon desquamates and cleanses, thus allowing the sandalwood oil to penetrate and reduce inflammation.

6.2 Limitations

A limitation in our study was the high participant dropout rate. Participants were students, hence data received were homogenous. The researcher did not take into the account the menstrual cycle of participants. During this phase, the hormone activity increases, perhaps resulting in aggravated PIH symptoms. It may have been possible that many participants were on their menstrual cycle during consultations. Therefore, results for that consultation may not have been accurate and precise.

6.3 Recommendations

The following recommendations should be considered for future studies:

- The study sample size should be increased to improve validity of the study
- All Fitzpatrick scale skin types be included to determine efficacy of treatment.
- Diverse participants from various backgrounds should be included to determine the efficacy of these treatments on other ethnic groups and genders
- Newer equipment should be utilised to provide extensive data reports. During the duration of the study, more advanced and unconventional machinery emerged. It is recommended that the study use the Vichy[®] 3D or Luminosity[®] machines displaying broad results and features, allowing further insight into the study. These machines will also provide awareness on the transepidermal water loss prevented by the treatment products.

- Document a menstrual cycle schedule for all participants. This schedule would allow the researcher to identify recommended times for consultation. This will avoid hormone activities influencing with the findings and results.
- It is suggested that a combination product of lemon and sandalwood oil be developed and tested. Individually, these oils possess properties to combat PIH, it is therefore recommended that they should be combined for experimental investigation. The combination treatment should be tested on other pigmentary and skin conditions.

LIST OF REFERENCES

Abad-Casintahan, F., Chow, S. K. W., Goh, C. L., Kubba, R., Hayashi, N., Noppakun, N., See, J., Suh, D. H., Xiang, L. F. H. and Kang, S. 2016. Frequency and characteristics of acne-related post-inflammatory hyperpigmentation. *Journal of Dermatology* (online), 43(7): 826-828. Available: <http://web.a.ebscohost.com/ehost/pdfviewer/pdfviewer?vid=1&sid=f8d44f92-2735-426c-9c69-ec3497bf1b64%40sessionmgr4006> (Accessed 29 August 2019).

Adalatkah, H. and Bazargani, H. S. 2013. The association between melasma and postinflammatory hyperpigmentation in acne patients. *Iranian Red Crescent Medical Journal* (online), 15(5): 400-403. Available: <https://www.ncbi.nlm.nih.gov/pmc/articles/PMC3838649/?tool=pmcentrez&report=abstract> (Accessed 29 August 2019).

Al Qarqaz, F. and Al-Yousef, A. 2018. Skin microneedling for acne scars associated with pigmentation in patients with dark skin: *Journal of Cosmetic Dermatology* (online), 17(1): 390-395. Available: <http://web.a.ebscohost.com/ehost/pdfviewer/pdfviewer?> (Accessed 09 July 2019).

Alam, M. and Warycha M. 2011. Complications of lasers and light treatments. *Dermatologic Therapy* (online), 24(6): 571-580. Available: <https://onlinelibrary.wiley.com/doi/abs/10.1111/j.1529-8019.2012.01476.x> (Accessed 30 August 2019).

Alexis, A. F. 2013. Lasers and light-based therapies in ethnic skin: treatment options and recommendations for Fitzpatrick skin types V and VI. *British Journal of Dermatology* (online), 169(3): 91-97. Available: <https://onlinelibrary.wiley.com/doi/epdf/10.1111/bjd.12526> (Accessed 30 August 2019).

Anbar, T., Abdel-Rahman, A., Hegazy, R., El-Khayyat, M. and Ragaie, M. 2016. Simultaneous improvement and worsening of vitiligo lesions during the course NB-UVB phototherapy, vitiligo may not act as one unit. *Dermatologic Therapy* (online), 30(1): 1-6. Available: <http://web.b.ebscohost.com/ehost/pdfviewer/pdfviewer?vid=1&sid=7bb94ada-637e-4929-949d-66aef9a95d91%40sessionmgr101> (Accessed 23 October 2019).

Andrade, B. F. M. T., Barbosa, L. N., Probst, I. S. and Júnior, A. F. 2014. Antimicrobial activity of essential oils. *Journal of Essential Oil Research* (online), 26(1): 34-40. Available: <http://web.b.ebscohost.com/ehost/pdfviewer/pdfviewer?vid=1&sid=72c383b0-5ac7-4748-b3dc-7ce09f28a7a0%40sessionmgr102> (Accessed 04 September 2019).

Arda, O., Göksüğü N. and Tüzün, Y. 2014. Basic histological structure and functions of facial skin. *Clinics in Dermatology* (online), 32(1): 3-13. Available: <https://www.ncbi.nlm.nih.gov/pubmed/24314373> (Accessed 04 April 2017).

Augustyniak, A., Erkiert-Polguj, A. and Rotsztejn, H. 2015. Variable pulsed light treatment of melasma and post-inflammatory hyperpigmentation – a pilot study. *Journal of Cosmetic and Laser Therapy* (online), 17(1): 15-19. Available: <http://web.a.ebscohost.com/ehost/pdfviewer/pdfviewer?vid=1&sid=0f1fe322-d77b-4f9e-b206-f3b13da43808%40sdc-v-sessmgr03> (Accessed 29 August 2019).

Baghel, S., Gidwani, B. and Kaur, C. D. 2017. Novel drug delivery systems of herbal constituents used in acne. *Asian Journal of Research in Pharmaceutical Science* (online), 7(2): 1-12. Available: <https://search.proquest.com/docview/2286963923?pq-origsite=summon> (Accessed 09 October 2019).

Bakkali, F., Averbeck, S., Averbeck, D. and Idaomar, M. 2008. Biological effects of essential oils--a review. *Food and Chemical Toxicology* (online), 46(2): 446-475. Available: <http://www.ncbi.nlm.nih.gov/pubmed/17996351> (Accessed 5 November 2015).

Bandyopadhyay, D. 2009. Topical treatment of melasma. *Indian Journal of Dermatology* (online), 54(4): 303-309. Available: <https://www.ncbi.nlm.nih.gov/pmc/articles/PMC2807702/> (Accessed 22 October 2019).

Bangert, C., Brunner, P. M., and Stingl G. 2011. Immune functions of the skin. *Clinical Dermatology* (online), 29(4): 360-376. Available: <https://www.ncbi.nlm.nih.gov/pubmed/21679864> (Accessed 03 February 2018).

Barcaui, E, Carvalho, A.C.P., Pineiro-Maceira, J., Bacraui, C.B. and Moraes, H. 2015. Study of the skin anatomy with high-frequency (22 MHz) ultrasonography and histological correlation: *The Journal Radiologia Brasileira* (online), 48(5): 324-329. Available: <https://www.ncbi.nlm.nih.gov/pmc/articles/PMC4633078/> (Accessed 04 April 2017).

Baroni, A., Buommino, E., Gregorio, V., Ruocco, E., Ruocco, V. and Wolf, R. 2012. Structure and function of the epidermis related to barrier properties. *Clinics in Dermatology* (online), 30(1): 257–262. Available: http://ac.els-cdn.com/S0738081X11002112/1-s2.0-S0738081X11002112main.pdf?_tid=2554c1e2- (Accessed 24 October 2016).

Bastonini, E., Kovacs, D. and Picardo, M. 2016. Skin pigmentation and pigmentary disorders: focus on epidermal/dermal cross-talk. *Annals of Dermatology* (online), 28(3): 279-289. Available: <https://www.ncbi.nlm.nih.gov/pmc/articles/PMC4884703/> (Accessed 01 June 2017).

Baxter, L. L. and Pavan, W. J. 2013. The etiology and molecular genetics of human pigmentation disorders: Wiley interdisciplinary reviews. *Developmental Biology* (online), 2(3): 379-392. Available: http://wu4wl9yj2g.search.serialssolutions.com/?ctx_ver=Z39.88- (Accessed 20 September 2019).

Bharkatiya, M., Nema, R.K., Rathore. K.S. and Panchawat, S. 2008. Aromatherapy: short overview. *International Journal of Green Pharmacy* (online), 2(1): 13-16. Available: <https://search.proquest.com/docview/871215074?pq-origsite=summon> (Accessed 04 September 2019).

Bibilash, B. S., Chittoria, R. K., Thappa, D. M., Mohapatra, D. P., Friji, M. T., Dineshkumar, S. and Pandey, S. 2017. Are lasers superior to lights in the photoepilation of Fitzpatrick V and VI skin types? A comparison between Nd: YAG laser and intense pulsed light. *Journal of Cosmetic and Laser Therapy* (online), 19(5): 252-255. Available: <http://web.a.ebscohost.com/ehost/pdfviewer/pdfviewer?vid=1&sid=8e483ced-8a10-419d-86f4-35d7b09d385e%40sessionmgr4008> (Accessed 06 September 2019).

Bikle, D. D. 2011. Vitamin D metabolism and function in the skin. *Molecular and Cellular Endocrinology* (online), 347(1): 80-89. Available: <https://www.ncbi.nlm.nih.gov/pubmed/21664236> (Accessed 03 March 2017).

Bino, S. D., Duval, C. and Bernerd, F. 2018. Clinical and biological characterization of skin pigmentation diversity and its consequences on UV impact. *International Journal of Molecular Sciences* (online), 19(9): 1-44. Available: <https://media.proquest.com/media/hms/PFT/1/RscY7?cit%3Aauth=Sandra+Del+Bino> (Accessed 31 October 2019).

Bonilla, C., Ness, A. R., Wills, A. K., Lawlor, S. A., Lewis, S. J. and Smith, G. D. 2014. Skin pigmentation, sun exposure and vitamin D levels in children of the Avon longitudinal study of parents and children: *BMC Public Health* (online), 14(1): 1-10. Available: <https://media.proquest.com/media/pq/classic/doc/3347741851/fmt/pi/rep/> (Accessed 17 September 2019).

Bragulla, H. H. and Homberger, D. G. 2009. Structure and functions of keratin proteins in simple stratified, keratinized and cornified epithelia. *Journal of Anatomy* (online), 214(4): 516-559. Available: <https://www.ncbi.nlm.nih.gov/pmc/articles/PMC2736122/?tool=pmcentrez&report=abstract> (Accessed 11 October 2019).

Brenner, M. and Hearing, V. J. 2008. The protective role of Melanin against UV damage in human skin: *National Institutes of health* (online), 84(3): 539-549. Available: <https://www.ncbi.nlm.nih.gov/pmc/articles/PMC2671032/pdf/nihms103064.pdf> (Accessed 24 October 2016).

Brodell, L.A. and Rosenthal, K.S., 2008. skin structure and function: *Infectious Diseases in Clinical Practice* (online), 16(2): 113-117. Available: https://journals.lww.com/infectdis/Fulltext/2008/03000/Skin_Structure_and_FunctionThe_Body_s_Primary.8.aspx (Accessed 11 October 2017).

Brohem, C. A., Cardeal, L. B., Tiago, M., Soengas, M., Barros, S. M. and Maria-Engler, S. M. 2010. Artificial skin in perspective: concepts and applications: *Pigment Cell Melanoma Research* (online), 24(1): 35-50. Available: <https://www.ncbi.nlm.nih.gov/pubmed/21029393> (Accessed 12 November 2016).

Bunyavaree, M., Kasemsarn, P. and Boonchai, W. 2016. Cosmetic preservative labelling on the Thai market. *Contact Dermatitis* (online), 74(4): 217-221. Available: <http://web.b.ebscohost.com/ehost/pdfviewer/pdfviewer?vid=1&sid=c007f185-ed10-4fc4-b2f5-5f6a2ce3ff19%40pdc-v-sessmgr01> (Accessed 29 August 2019).

Burger, P., Landreau, A., Azoulay, S., Michel, T. and Fernandez, X. 2016. Skin whitening cosmetics: feedback and challenges in the development of natural skin lighteners. *Cosmetics* (online), 3(36): 1-24. Available: <https://doaj.org/article/5dcfd481ff2a47f693ffe16982a1d9f4> (Accessed 11 July 2019).

Callender, V. D., St. Surin-Lord, S., Davis, E. C. and Maclin, M. 2011. Postinflammatory hyperpigmentation: etiologic and therapeutic considerations. *American Journal of Clinical Dermatology* (online), 12(2): 87-99. Available: <https://search.proquest.com/docview/853508717?pq-origsite=summon> (Accessed 29 August 2019).

Cayce, K. A., McMichael, A. J. and Feldman, S. R. 2004. Hyperpigmentation: an overview of the common afflictions. *Dermatology Nursing* (online), 16(5): 401-416. Available: <https://media.proquest.com/media/pq/classic/doc/731124201/fmt/pi/rep/NONE?cit%> (Accessed 18 September 2019).

Cefali, L. C., Ataide, J. A., Moriel, P., Foglio, M. A. and Mazzola, P. G. 2016. Plant-based active photoprotectants for sunscreens. *International Journal of Cosmetic Science* (online), 38(4): 346-353. Available: <https://onlinelibrary.wiley.com/doi/full/10.1111/ics.12316> (Accessed 04 September 2017).

César, F. C. S., Neto, F. C., Porto, G. S. and Maia Campos, P. M. B. G. 2017. Patent analysis: a look at the innovative nature of plant-based cosmetics. *Quimica Nova* (online), 40(7): 840-847. Available: http://www.scielo.br/scielo.php?script=sci_arttext&pid=S0100-40422017000700840&lng=en&tlng=en (Accessed 04 September 2019).

Cestari, T. F., Dantas, L. P. and Boza, J. C. 2014. Acquired hyperpigmentations. *Anais Brasileiros de Dermatologia* (online), 89(1): 11-25. Available: <https://www.ncbi.nlm.nih.gov/pmc/articles/PMC3938350/> (Accessed 29 August 2019).

Chandra, M., Levitt, J. and Pensabene, C. A. 2012. Hydroquinone therapy for post-inflammatory hyperpigmentation secondary to acne: not just prescribable by dermatologists. *Acta Dermato-Venereologica* (online), 92(3): 232-235. Available: <http://web.a.ebscohost.com/ehost/results?vid=0&sid=e02b9d25-61c5-4a99-90a3> (Accessed 02 September 2019).

Chandrashekar, BS, Shenoy, C., Madura, C. 2019. Complications of laser and light-based devices therapy in patients with skin of colour. *Indian Journal of Dermatology, Venereology and Leprology* (online), 85(1): 24-31. Available: <http://www.ijdvl.com/article.asp?issn=0378-6323> (Accessed 09 July 2019).

Chaowattanapanit, S., Silpa-Archa, N., Kohli, I., Lim, H.W. and Hamzavi, I. 2017. Postinflammatory hyperpigmentation: a comprehensive overview – treatment options and prevention. *Journal of the American Academy of Dermatology* (online), 77(4): 607-621. Available: <https://www.sciencedirect.com/science/article/pii/S0190962217301299> (Accessed 29 August 2019).

Chaudhri, S. K. and Jain, N. K. 2009. History of cosmetics. *Asian Journal of Pharmaceutics* (online), 3(3): 164-167. Available: <https://pdfs.semanticscholar.org/6c76/09a33cd016d4038600c4d7560b13bf923c8c.pdf> (Accessed 03 September 2019).

Chen, W., Obermayer-Pietsch, B., Hong, J. B., Melnik, B. C., Yamasaki, O., Dessinioti, C., Ju, Q., Liakou, A., Al-Khuzael, S. A., Katsambas, A., Ring, J. and Zouboulis, C. C. 2011. Acne-associated syndromes: models for better understanding of acne pathogenesis. *Journal of the European Academy of Dermatology and Venereology* (online), 25(6): 637-646. Available: <https://onlinelibrary.wiley.com/doi/epdf/10.1111/j.1468-3083.2010.03937.x> (Accessed 14 October 2019).

Choi, S. Y. and Park, K. 2016. Effect of inhalation of aromatherapy oil on patients with perennial allergic rhinitis: a randomized controlled trial. *Evidence-Based Complementary and Alternative Medicine* (online), 2016: 1-7. Available: <https://pdf.sciencedirectassets.com/271163/1-s2.0-S0308814612X00116/1-s2.0-> (Accessed 05 September 2019).

Choi, S. Y., Yoo, K. H., Oh, C. T., Kwon, T. R., Choi, E. J., Seok, J. and Kim, B. J. 2016. High intensity focused ultrasound as a potential new modality for the treatment of pigmentary skin disorder. *Skin Research and Technology* (online), 22(2): 131-136. Available: <http://web.b.ebscohost.com/ehost/pdfviewer/pdfviewer?vid=1&sid=91f52df0-1b8a-4b2c-8790-d26a10382d4f%40pdc-v-sessmgr03> (Accessed 29 August 2019).

Chomiczewska, D., Trznadel-Budźko E., Kaczorowska, A. and Rotsztejn, H. 2009. The role of Langerhans cells in the skin immune system. *Polski Merkuriusz Lekarski* (online), 26(153): 173-177. Available: <https://www.ncbi.nlm.nih.gov/pubmed/19388527> (Accessed 12 May 2018).

Clark, A. K. and Sivamani, R. K. 2016. Phytochemicals in the treatment of hyperpigmentation. *Botanics: Targets and Therapy* (online), 6(1): 89-96. Available: <https://search.proquest.com/docview/2223940992?pq-origsite=summon> (Accessed 29 August 2019).

Common, J. E. A., Barker, J. N. and Van Steensel, M. A. M. 2019. What does acne genetics teach us about disease pathogenesis. *British Journal of Dermatology* (online), 181(4): 665-676. Available: <https://onlinelibrary.wiley.com/doi/epdf/10.1111/bjd.17721> (Accessed 14 October 2019).

Costin, G. E. and Hearing, V. J. 2007. Human skin pigmentation: melanocytes modulate skin color in response to stress. *Federation of American Societies for Experimental Biology* (online), 21(4): 976-994. Available: <https://www.ncbi.nlm.nih.gov/pubmed/17242160> (Accessed 11 May 2017).

D'Elia, M. P. B., Brandão, M. C., Ramos, B. R., Guimarães da Silva, M., Miot, L. D. B., Batista dos Santos, S. E. and Miot, H. A. 2017. African ancestry is associated with facial melasma in women: a cross-sectional study. *BMC Medical Genetics* (online), 18(17): 1-7. Available: <https://search.proquest.com/docview/1869965359?pq-origsite=summon> (Accessed 29 August 2019).

D'Ischia, M., Wakamatsu, K., Cicoira, F., Di Mauro, E., Garcia-Borron, J. C., Commo, S., Galvan, I., Ghanem, G., Kenzo, K., Meredith, P., Pezzella, A., Santato, C., Sarna, T., Simon, J. D., Zecca, L., Zucca, F. A., Napolitano, A. and Ito, S. 2015. Melanins and melanogenesis: from pigment cells to human health and technological applications. *Pigment Cell & Melanocyte Research*. (online), 28(5): 520-544. Available: <https://www.ncbi.nlm.nih.gov/pubmed/26176788> (Accessed 28 March 2017).

Dahl, R. E. and Forbes, E. E. 2010. Pubertal development and behavior: hormonal activation of social and motivational tendencies. *Brain and Cognition* (online), 72(1): 66-72. Available: <https://www.ncbi.nlm.nih.gov/pmc/articles/PMC3955709/pdf/nihms161798.pdf> (Accessed 05 September 2019).

Darlenski, R. and Fluhr, J. W. 2012. Influence of skin type, race, sex, and anatomic location on epidermal barrier function. *Clinics in Dermatology* (online), 30(1): 269-273. Available: <https://pdf.sciencedirectassets.com/271159/1-s2.0S0738081X11X00093/1-s2.0-S0738081X11002173/main.pdf?X-Amz> (Accessed 28 August 2019).

Das, S. and Reynolds, V. 2014. Recent advances in acne pathogenesis: implications for therapy. *American Journal of Clinical Dermatology* (online), 15(6): 479-488. Available: <https://media.proquest.com/media/pq/classic/doc/3538863071/fmt/pi/rep/NONE?cit> (Accessed 30 October 2019).

Davids, L. M., Van Wyk, J., Khumalo, P. N. and Jabonski, G. N. 2016. The phenomenon of skin lightening: is it right to be light. *South African Journal of Science* (online), 112(11-12): 1-6. Available: <https://go.openathens.net/redirector/dut.ac.za?url=http%3A%2F> (Accessed 11 July 2019).

Davis, E. C. and Callender, V. D. 2010. Postinflammatory hyperpigmentation: a review of the epidemiology, clinical features, and treatment options in skin of color. *Clinical Aesthetic Dermatology* (online), 3 (7): 20-31. Available: http://www.ncbi.nlm.nih.gov/pmc/articles/PMC2921758/pdf/jcad_3_7_20.pdf (Accessed 22 February 2016).

De Melo, E. D., Munteer, A. H., de Souza Leão, L. H. and Bahia, R. C. B. 2013. Toxicity identification evaluation of cosmetics industry wastewater. *Journal of Hazardous Materials* (online), 244(1): 329-334. Available: <https://pdf.sciencedirectassets.com/271390/1-s2.0-S0304389412X00232/1-s2.0-> (Accessed 03 September 2019).

De Wet, H., Nciki, S. and Van Vuuren, S. F. 2013. Medicinal plants used for the treatment of various skin disorders by a rural community in northern Maputaland, South Africa. *Journal of Ethnobiology and Ethnomedicine* (online), 9(51): 1-11. Available: <https://reader.elsevier.com/reader/sd/pii/S0378874110003041?token> (Accessed 11 July 2019).

Deckers, J., Hammad, H. and Hoste, E. 2018. Langerhans cells: sensing the environment in health and disease. *Frontiers in Immunology* (online), 9(93): 1-14. Available: <https://www.ncbi.nlm.nih.gov/pmc/articles/PMC5799717/pdf/fimmu-09-00093.pdf> (Accessed 18 September 2019).

Deeva, N. V., Krinitsyna, Y. M., Mustafina, S. V., Rymar, O. D. and Sergeeva, I. G. 2017. Assessment of the degree of skin hypopigmentation in patients with vitiligo by using mexametry. *The Open Dermatology Journal* (online), 11(1): 53-58. Available: <https://benthamopen.com/contents/pdf/TODJ/TODJ-11-53.pdf> (Accessed 13 May 2018).

Degitz, K. and Ochsendorf, F. 2017. Acne. *Journal of the German Society of Dermatology* (online), 15(7): 709-722. Available: <http://web.b.ebscohost.com/ehost/pdfviewer/pdfviewer?vid=1&sid=38843600-6878-4650-a0fc-e4bf5e5eaf60%40pdc-v-sessmgr02> (Accessed 06 September 2019).

DeMaria, A. L., Flores, M., Hirth, J. M., Berenson, A. B. 2014. Complications related to pubic hair removal. *American Journal of Obstetrics and Gynecology* (online), 211(6): 713-714. Available: <https://pdf.sciencedirectassets.com/272360/1-s2.0-S0002937813X00183/1-s2.0-S0002937814000659/main.pdf?X-Amz> (Accessed 20 September 2019).

De Mendonca, C. M. S, de Barros Lima, I. P., Arago, C. F. S. and Gomes, A. P. B. 2014. Thermal compatibility between hydroquinone and retinoic acid in pharmaceutical formulations. *Journal of Thermal Analysis and Calorimetry* (online), 115(3): 2275-2285. Available: <https://dut.summon.serialssolutions.com/search?s.q=Glazer%2C+Sofen+and+Gallo+2016#!/search?ho=t&l=en&q=Thermal%20compatibility%20between%20hydroquinone%20and%20retinoic%20acid> (Accessed 02 September 2019).

Dendle, C., Mulvey, S., Pyrlis, F., Grayson, M. L. and Johnson, P. D. 2007. Severe complications of a “Brazilian” bikini wax. *Clinical Infectious Diseases* (online), 45(1): 29-31. Available: <https://watermark.silverchair.com/45-3-e29.pdf?token=AQECAHi208BE49Ooan> (Accessed 09 October 2019).

Deo, P. N. and Deshmukh, R. 2018. Pathophysiology of keratinization. *Journal of Oral and Maxillofacial Pathology* (online), 22(1): 86-91. Available: <https://www.ncbi.nlm.nih.gov/pmc/articles/PMC5917548/> (Accessed 14 October 2019).

Desai, S. R. and Alexis, A. 2014. Hyperpigmentation therapy: a review. *The Journal of Clinical and Aesthetic Dermatology* (online), 7(8): 13-17. Available: <https://www.ncbi.nlm.nih.gov/pmc/articles/PMC4142815/?tool=pmcentrez&report=abstract> (Accessed 29 August 2019).

Dhadhal, C. H. 2015. It all boils down to the price – a study of the perception of women skincare cosmetics buyers regarding the relative importance of the major price components of a brand. *Sumedha Journal of Management* (online), 4(2): 83-91. Available: <https://media.proquest.com/media/pq/classic/doc/4004227401/fmt/pi/rep/NONE?ci> (Accessed 26 September 2019).

- Diaz-Chavez, M. L., Moniodis, J., Madilao, L. L., Jancsik, S., Keeling, C. I., Barbour, E. L., Ghisalberty, E. L., Plummer, J. A., Jones, C. G. and Bohlmann, J. 2013. Biosynthesis of Sandalwood oil: Santalum album CYP76F Cytochromes P450 Produce Santalols and Bergamotol. *PLOS ONE* (online), 8(9):1-12. Available: <https://media.proquest.com/media/hms/PFT/1/YvNt5?cit%3Aauth=Diaz-Chavez%2C+Maria+L%3BMoniodis%2C+Jessie%3BMadilao%2C+Lufiani+L%3B> (Accessed 16 October 2019).
- Dimitrova, V., Kaneva, M. and Gallucci, T. 2009. Customer knowledge management in the natural cosmetics industry. *Customer Knowledge Management* (online), 109(9): 1155-1165. Available: <https://www.emerald.com/insight/content/doi/10.1108/02635570910777777> (Accessed 11 July 2019).
- Dlova, C. N., Hendricks, N. E. and Martin, B. S. 2012. Skin lightening creams used in Durban, South Africa. *International Journal of Dermatology* (online), 51(1): 51-53. Available: <http://web.b.ebscohost.com/ehost/pdfviewer/pdfviewer?sid=5c8d4855-d732-4ae5-a72a048790f4f382%40sessionmgr120&vid=1&hid=115> (Accessed 02 March 2016).
- Dlova, N., Hamed, S. H., Tsoka-Gwegweni, J., Grobler, A. and Hift, R. 2014. Womens' perceptions of the benefits and risks of skin-lightening creams in two South African communities. *Journal of Cosmetic Dermatology* (online), 13(3): 236-241. Available: <http://web.a.ebscohost.com/ehost/pdfviewer/pdfviewer?vid=1&sid=783ad037-659a-44a2-ba56-9488a6c23afe%40sessionmgr4006> (Accessed 11 July 2019).
- Do, T. K. T., Hadji-Minaglou, F., Antoniotti, S. and Fernandez, X. 2015. Authenticity of essential oils. *Trends in Analytical Chemistry* (online), 66(1): 146-157. Available: http://ac.elscdn.com/S0165993614002519/1-s2.0-S0165993614002519-main.pdf?_tid=cc120cea-ea8f-11e583bc-00000aab0f01 (Accessed 12 March 2016).
- Dosoky, N. S. and Setzer, W. N. 2018. Biological activities and safety of Citrus spp. essential oils. *International Journal of Molecular Sciences* (online), 19(7): 1-25. Available: <https://media.proquest.com/media/hms/PFT/1/gob97?cit%3Aauth=Dosoky%2C+Noura+S%3BSetzer%2C+William+N&cit%3Atitle=Biological+> (Accessed 09 September 2019).

Dozmorov, M. G., Yang, Q., Wu, W., Wren, J., Suhail, M. M., Woolley, C. L., Young, D. G., Fung, K. and Lin, H. 2014. Differential effects of selective frankincense (*Ru Xiang*) essential oil versus non-selective sandalwood (*Tan Xiang*) essential oil on cultured bladder cancer cells: a microarray and bioinformatics study. *Chinese Medicine* (online), 9(18): 1-12. Available: <https://media.proquest.com/media/pq/classic/doc/3367490511> (Accessed 10 July 2019).

Draelos, Z. D. 2007. Skin lightening preparations and the hydroquinone controversy. *Dermatologic Therapy* (online), 20(5): 308-313. Available: <http://web.b.ebscohost.com/ehost/pdfviewer/pdfviewer?vid=1&sid=2343c219-6a84-461a-8024-3f1e679f9df9%40pdc-v-sessmgr01> (Accessed 30 August 2019).

Draelos, Z. D. 2015. Cosmetics: the medicine of beauty. *Journal of Cosmetic Dermatology* (online), 14(2): 91. Available: <http://web.b.ebscohost.com/ehost/pdfviewer/pdfviewer?vid=1&sid=132a4153-caf5-4039-958f-112cf3617a6f%40pdc-v-sessmgr01> (Accessed 03 September 2019).

Dreger, M. and Wielgus, K. 2013. Application of essential oils as natural cosmetic preservatives. *Herba Polonica* (online), 59(4): 142-156. Available: http://wu4wl9yj2g.search.serialssolutions.com/?ctx_ver=Z39.88- (Accessed 05 September 2019).

Dreher, F., Draelos, Z. D., Gold, M. H., Goldman, M. P., Fabi, S. G. and Puissegur Lupo, M. L. 2013. Efficacy of hydroquinone-free skin-lightening cream for photoaging. *Journal of Cosmetic Dermatology* (online), 12(1): 12-17. Available: <http://web.a.ebscohost.com/ehost/pdfviewer/pdfviewer?vid=1&sid=220029c1-23e7-4892-b728-66a838312d51%40sdc-v-sessmgr01> (Accessed 02 September 2019).

Duckney, P., Wong, H. K., Serrano, J., Yaradou, D., Oddos, T. and Stamatias, G. N. 2013. The role of the skin barrier in modulating the effects of common skin microbial species on the inflammation, differentiation and proliferation status of epidermal keratinocytes. *BMC Research Notes* (online), 6(474): 1-10. Available: <http://www.biomedcentral.com/1756-0500/6/474> (Accessed 01 October 2014).

Dupuy, A., Athes, V., Schenk, J., Jenelten, U. and Souchon, I. 2011. Solvent extraction of highly valuable oxygenated terpenes from lemon essential oil using a polypropylene membrane contactor: potential and limitations. *Flavour and Fragrance Journal* (online), 26(3): 192-203. Available: <https://onlinelibrary.wiley.com/doi/epdf/10.1002/ffj.2052> (Accessed 27 September 2019).

Ebanks, J. P., Wickett, R. R. and Boissy, R. E. 2009. Mechanisms regulating skin pigmentation: the rise and fall of complexion coloration. *International Journal of Molecular Sciences* (online), 10(1): 4066-4087. Available: <https://www.google.co.za/search?q=antioxidant+effects+on+post+inflammatory+pigmentation&sxsrf=ACYBGNQwOjwsmghoEac0fJ9ixHK5COjQhc> (Accessed 09 September 2019).

Eimpunth, S., Wanitphadeedecha, R. and Manuskiatti, W. 2013. A focused review on acne-induced and aesthetic procedure-related postinflammatory hyperpigmentation in Asians. *Journal of the European Academy of Dermatology and Venereology* (online), 27(1): 7-18. Available: <https://onlinelibrary.wiley.com/doi/epdf/10.1111/jdv.12050> (Accessed 29 August 2019).

El Asbahani, A., Miladi, K., Badri, W., Sala, W., Ait Addi, E. H., Casabianca, H., El Mousadik, A., Hartmann, D., Jilale, A., Renaud, F. N. R. and Elaissari, A. 2015. Essential oils: from extraction to encapsulation. *International Journal of Pharmaceutics* (online), 483(1-2): 220-243. Available: <https://reader.elsevier.com/reader/sd/pii/S0378517314009661?token=BE6F0DE7062C93E8B2D27F244E753884A7098CCD7AD433D1F287E2E3000112B136FFEAFA7B7F8A0CD458FCEFB2584982> (Accessed 10 July 2019).

Eliason, S., John, K. A., Eliason, C., Novignon, J., Novignon, J. and Aikins, M. 2014. Determinants of modern family planning use among women of reproductive age in the Nkwanta district of Ghana: a case-control study. *Reproductive Health* (online), 11(1): 1-10. Available: <https://media.proquest.com/media/pq/classic/doc/3500100491/fmt/pi/rep/NONE?cit%3Aauth=Eliason%2C+Sebastian%3BAwoonor-> (Accessed 20 September 2019).

Fabbrocini, G., Annunziata, V. D., Vita, V., Lodi, G., Mauriello, M. C., Pastore, F. and Monfrecola, G. 2010. Acne scars: pathogenesis, classification and treatment. *Dermatology Research and Practice* (online), 2010(1): 1-13. Available: <https://www.ncbi.nlm.nih.gov/pmc/articles/PMC2958495/pdf/DRP2010-893080.pdf> (Accessed 09 October 2019).

Faidi, K., El Mokni, R., Joshi, R. K., Hammami, S., M'Henni, M. F. and Mighri, Z. 2014. Comparative study on the chemical constituents of essential oils from different organs of the Sicilian *Kundmannia* (*Kundmannia sicula* L.) DC. (Apiaceae) growing spontaneously in Tunisia. *Natural Product Research* (online), 28(20): 1680-1684. Available: <http://web.b.ebscohost.com/ehost/pdfviewer/pdfviewer?vid=1&sid=4da6db5f-b9d6-4ef3-b8d0-680988ebc05e%40pdc-v-sessmgr05> (Accessed 05 September 2019).

Farzaneh, V. and Carvalho, I. S. 2015. A review of the health benefit potentials of herbal plant infusions and their mechanism of actions. *Industrial Crops and Products* (online), 65(1): 247-258. Available: <https://reader.elsevier.com/reader/sd/pii/S092666901400675X?token> (Accessed 11 July 2019).

Felton, S. J., Cooke, M. S., Kift, R., Berry, J. L., Webb, A. R., Lam, P. M. W., Gruijl, F. R., Vail, A. and Rhodes, L. E. 2016. Concurrent beneficial (vitamin D production) and harardous (cutaneous DNA damage) impact of repeated low-level summer sunlight exposures. *British Journal of Dermatology* (online), 175(6): 1320-1328. Available: <https://onlinelibrary.wiley.com/doi/epdf/10.1111/bjd.14863> (Accessed 26 September 2019).

Fornari, T., Vicente, G., Vazquez, E., Garcia-Risco, M. R. and Reglero, G. 2012. Isolation of essential oil from different plants and herbs by supercritical fluid extraction. *Journal of Chromatography* (online), 1250(1): 34-48. Available: <https://reader.elsevier.com/reader/sd/pii/S0021967312006437?token=FD6CA62DC41F162A996EEAB8462E081690FA55174D9C5CC696A88A5E71311989C63F02D8B> (Accessed 10 July 2019).

Garbossa, W. A. C. and Campos, P. M. B. G. M. 2016. Evaluation of the Brazilian cosmetic legislation and its impact on the industries during the 20th century. *Brazillian Journal of Pharmaceutical Sciences* (online), 52(2): 319-328. Available: <http://www.scielo.br/pdf/bjps/v52n2/2175-9790-bjps-52-02-00319.pdf> (Accessed 11 July 2019).

Ghodsee, K. 2007. Potions, lotions and lipstick: the gendered consumption of cosmetics and perfumery in socialist and post-socialist urban Bulgaria. *Womens Studies International Forum* (online), 30(1): 26-39. Available: <https://reader.elsevier.com/reader/sd/pii/S0277539506001075?token> (Accessed 12 May 2016).

Gite, S. S., Jadhav, A. J., Zalte, A. G. and Saudagar, R. B. 2013. A review on oils used in herbal cosmetics. *Research Journal of Topical and Cosmetic Sciences* (online), 4(2): 61-64. Available: <http://www.anvpublication.org/viewarticles.php?j=0976-2981&vol=4&issue=2> (Accessed 27 October 2015).

Glazer, A., Sofen, B. D., Gallo and E. S. 2016. Nail discoloration after use of hydroquinone. *American Academy of Dermatology* (online), 2(1): 57-58. Available: <https://pdf.sciencedirectassets.com/311971/1-s2.0-S2352512615X00099/1-s2.0-> (Accessed 02 September 2019).

Goding, C. R. 2007. Melanocytes: the new black. *The International Journal of Biochemistry & Cell Biology* (online), 39(2): 275-279. Available: <https://www.ncbi.nlm.nih.gov/pubmed/17095283> (Accessed 02 August 2017).

Gold, M. H. and Biron, J. 2011. Efficacy of a novel hydroquinone-free skin-brightening cream in patients with melasma. *Journal of Cosmetic Dermatology* (online), 10(3): 189-196. Available: <http://web.b.ebscohost.com/ehost/pdfviewer/pdfviewer?vid=1&sid=38c06088-ce1c-430c-85bb-05bf23a3ef17%40pdc-v-sessmgr04> (Accessed 30 August 2019).

Goldberg, D. 2006. Laser complications: hair removal. *Journal of Cosmetic and Laser Therapy* (online), 8(4): 197-202. Available: <http://web.b.ebscohost.com/ehost/pdfviewer/pdfviewer?vid=1&sid=c050895b-5074-4aad-96ec-ccc560b72498%40pdc-v-sessmgr05> (Accessed 09 October 2019).

Golmakani, M. and Moayyedi, M. 2015. Comparison of heat and mass transfer of different microwave-assisted extraction methods of essential oil from Citrus limon (Lisbon variety) peel. *Food Science & Nutrition* (online), 3(6): 506-518. Available: <https://search.proquest.com/docview/1757254302?pq-origsite=summon> (Accessed 05 September 2019).

Greydanus, D. E. 2015. Acne. *International Journal of Child Health and Human Development* (online), 8(3): 311-332. Available: [https://media.proquest.com/media/pq/classic/doc/3787075501/fmt/pi/rep/NONE?cit%](https://media.proquest.com/media/pq/classic/doc/3787075501/fmt/pi/rep/NONE?cit%40pdc-v-sessmgr04) (Accessed 14 October 2019).

Grippaudo, F. R. and Di Russo, P. P. 2016. Effects of topical application of B-Resorcinol and Glycyrrhetic acid monotherapy and in combination with fractional CO2 laser treatment for benign hand hyperpigmentation treatment. *Journal of Cosmetic Dermatology* (online), 15(4): 413-419. Available: <http://web.b.ebscohost.com/ehost/pdfviewer/pdfviewer?vid=1&sid=cca18018-42e3-4fb0-9167-6c26d24fa6ad%40pdc-v-sessmgr04> (Accessed 29 August 2019).

Guevara, I. L., Pandya, A. G. 2003. Safety and efficacy of 4% hydroquinone combined with 10% glycolic acid, antioxidants, and sunscreen in the treatment of melasma. *The International Society of Dermatology* (online), 42(12): 966-972. Available: <https://onlinelibrary.wiley.com/doi/full/10.1111/j.1365-4632.2003.02017.x> (Accessed 02 September 2019).

Gupta, A. K., Gover, M. D., Nouri, K. and Taylor, S. 2006. The treatment of melasma: a review of clinical trials. *Journal of the American Academy of Dermatology* (online), 55(6): 1048-1065. Available: <https://www.ncbi.nlm.nih.gov/pubmed/17097400> (Accessed 29 August 2019).

Haque, M. and Coury, D. L. 2018. Topical sandalwood oil for common warts. *Clinical Paediatrics* (online), 57(1): 93-95. Available: <https://journals.sagepub.com/doi/pdf/10.1177/0009922817691536> (Accessed 16 October 2019).

Halder, R. M. and Nootheti, P. K. 2003. Ethnic skin disorders overview. *Journal of the American Academy of Dermatology* (online), 48(6): 143-148. Available: http://wu4wl9yj2g.search.serialssolutions.com/?ctx_ver=Z39.88 (Accessed 29 August 2019).

Handel, A. C., Miot, L. D. B., Miot, H. A. 2014. Melasma: a clinical and epidemiological review. *Anais Brasileiros de Dermatologia* (online), 89(5): 771-782. Available: <https://www.ncbi.nlm.nih.gov/pmc/articles/PMC4155956/pdf/abd-89-05-0771.pdf> (Accessed 29 August 2019).

Hassim, N., Markom, M., Anuar, N. and Baharum, S. N. 2014. Solvent selection in extraction of essential oil and bioactive compounds from polygonum minus. *Journal of Applied Sciences* (online), 14(13): 1440-1444. Available: <http://docsdrive.com/pdfs/ansinet/jas/2014/1440-1444.pdf> (Accessed 05 September 2019).

Herman, A., Herman, A. P., Domagalska, B. W. and Młynarczyk, A. 2013. Essential oils and herbal extracts as antimicrobial agents in cosmetic emulsion. *Indian Journal of Microbiology* (online), 53(2): 232–237. Available: <https://www.ncbi.nlm.nih.gov/pmc/articles/PMC3626961/?tool=pmcentrez&report=abstract> (Accessed 29 August 2019).

Hernando, B., Ibarrola-Villava, M., Fernandez, L.P., Pena-Chilet, M., Llorca-Cardenosa, M., Oltra, S. S., Alonso, S., Boyano, M. D., Martinez-Cadenas, C. and Ribas, G. 2016. Sex specific genetic effects associated with pigmentation, sensitivity to sunlight and melanoma in a population of Spanish origin. *Biology of Sex Differences* (online), 7(17): 1-9. Available: https://www.ncbi.nlm.nih.gov/pmc/articles/PMC4797181/pdf/13293_2016_Article_70.pdf (Accessed 03 October 2019).

Herrling, T., Jung, K. and Fuchs, J. 2008. The role of melanin as protector against free radicals in skin and its role as free radical indicator in hair. *Spectrochimica Acta Part A: Molecular and Biomolecular Spectroscopy* (online), 63(83): 1-7. Available: http://www.gematria-test-lab.com/pdf/SAA_6383.pdf (Accessed 02 February 2017).

Hill, J. P. and Batchelor, J. M. 2017. An approach to hypopigmentation. *British Medical Journal* (online), 356(1): 1-6. Available: <https://media.proquest.com/media/hms/PFT/1/gxAO4?cit> (Accessed 29 August 2019).

Ho, S. G. Y., Yeung, C. K., Chan, N. P. Y., Shek, S. Y. and Chan, H. H. L. 2011. A comparison of Q-switched and long pulsed alexandrite laser for the treatment of freckles and lentiginos in oriental patients. *Laser in Surgery and Medicine* (online), 42(2): 108-133. Available: <https://onlinelibrary.wiley.com/doi/epdf/10.1002/lsm.21045> (Accessed 06 September 2019).

Hojjati, M. and Barzegar, H. 2017. Chemical composition and biological activities of lemon (citrus limon) leaf essential oil. *Nutrition and Food Sciences Research* (online), 4(4): 15-24. Available: <http://nfsr.sbm.ac.ir/article-1-244-en.pdf> (Accessed 15 October 2019).

- Hourblin, V., Nouveau, S., Roy, N. and de Lacharrière, O. 2014. Skin complexion and pigmentary disorders in facial skin of 1204 women in 4 Indian cities. *Indian Journal of Dermatology, Venereology and Leprology* (online), 80(5): 395-401. Available: <https://search.proquest.com/docview/1561125352?pq-origsite=summon> (Accessed 29 August 2019).
- Hsouna, A. B., Halima, N. B., Smaoui, S. and Hamdi, N. 2017. Citrus lemon essential oil: chemical composition, antioxidant and antimicrobial activities with its preservative effect against *Listeria monocytogenes* inoculated in minced beef meat. *Lips in Health and Disease* (online), 16(146): 1-11. Available: https://www.ncbi.nlm.nih.gov/pmc/articles/PMC5543433/pdf/12944_2017_Article_487.pdf (Accessed 15 October 2019).
- Hu, Z., Zhou, Q., Lei, T., Ding, S. and Xu, S. 2009. Effects of hydroquinone and its glucoside derivatives on melanogenesis and antioxidation: biosafety as skin whitening agents. *Journal of Dermatological Science* (online), 55(3): 179-184. <https://pdf.sciencedirectassets.com/271255/1-s2.0-S0923181109X00083/1-s2.0-S0923181109001613/main.pdf?X-Amz-Date=20190830T115914Z&X-Amz> (Accessed 30 August 2019).
- Huang, H., Wang, H., Yih, K., Chang, L. and Chang, T. 2012. The dual antimelanogenic and antioxidant activities of the essential oil extracted from the leaves of *Acorus macrospadicus* (Yamamoto). *Evidence-Based Complementary and Alternative Medicine* (online), 1(1): 1-10. Available: <http://www.hindawi.com/journals/ecam/2012/781280/> (Accessed 20 September 2014).
- Hwa, C, Bauer, E. A. and Cohen, D. A. 2011. Skin biology. *Dermatologic Therapy* (online), 24 (1): 464-470. Available: <https://www.ncbi.nlm.nih.gov/pubmed/22353152> (Accessed 06 August 2017).
- Hyldgaard, M., Mygind, T. and Meyer, R. L. 2012. Essential oils in food preservation: mode of action, synergies, and interactions with food matrix components. *Frontiers in Microbiology* (online), 3(12): 1-24. Available: <https://doi.org/article/bfc398b274dd43ed8e1ef02bc835da1f>. (Accessed 10 July 2019).

Ibrahim, Z. A., Gheida, S. F., El Maghraby, G. M. and Farag, Z. E. 2015. Evaluation of the efficacy and safety of combinations of hydroquinone, glycolic acid, and hyaluronic acid in the treatment of melasma. *Journal of Cosmetic Dermatology* (online), 14(2): 113-123. Available: <http://web.b.ebscohost.com/ehost/pdfviewer/pdfviewer?vid=1&sid=aca9a208-e613-4521-b201-bb692a9a687f%40sessionmgr103> (Accessed 02 September 2019).

Ingber, A. 2009. Hyperpigmentation and melasma. *Obstetric Dermatology* (online). 1(1): 7-18. Available: <http://www.springer.com/cda/content/.../cda.../9783540883982-c1.pdf> (Accessed 22 June 2016).

Isedeh, P., Kohli, I., Al-Jamal, M., Agbai, O. N., Chaffins, M., Devpura, S., Mahan, M., Vanderover, G., Lim, H. W., Matsui, M. S. and Hamzavi, I. H. 2016. An in vivo model for postinflammatory hyperpigmentation: an analysis of histological, spectroscopic, colorimetric and clinical traits. *British Journal of Dermatology* (online), 174(4): 862-868. Available: <https://onlinelibrary.wiley.com/doi/full/10.1111/bjd.14184> (Accessed 29 August 2019).

Ismail, S. A. 2012. Long pulsed Nd: YAG laser vs intense pulsed light for hair removal in dark skin: a randomised controlled trial. *British Journal of Dermatology* (online), 166(2): 317-321. Available: <https://onlinelibrary.wiley.com/doi/epdf/10.1111/j.1365-2133.2011.10695.x> (Accessed 06 September 2019).

Ito, S., Kolbe, L., Weets, G. and Wakamatsu, K. 2018. Visible light accelerates the ultraviolet A-induced degradation of eumelanin and pheomelanin. *Pigment Cell & Melanoma Research* (online), 32(3): 441-447. Available: <https://onlinelibrary.wiley.com/doi/epdf/10.1111/pcmr.12754> (Accessed 18 September 2019).

Ito, S., Nakanishi, Y., Valenzuela, R. K., Brilliant, M. H., Kolbe, L. and Wakamatsu, K. 2011. Usefulness of alkaline hydrogen peroxide oxidation to analyze eumelanin and pheomelanin in various tissue samples: application to chemical analysis of human hair melanins. *Pigment Cell & Melanoma Research* (online), 24(4): 605-613. Available: <http://web.a.ebscohost.com/ehost/pdfviewer/pdfviewer?vid=1&sid=7c67834c-29de> (Accessed 28 August 2019).

- Itoi-Ochi, S., Matsumura, S., Terao, Murota, H. and Katayama, I. 2016. Sandalwood oil downregulates skin inflammation through 11 β -HSD1 activation in keratinocytes. *Journal of Dermatological Science* (online), 84(1): 134. Available: <https://pdf.sciencedirectassets.com/271255/1-s2.0-S0923181116X00102/1-s2.0-> (Accessed 09 September 2019).
- Jablonski, N. G. and Chaplin, G. 2000. The evolution of human skin coloration. *Journal of Human Evolution* (online), 39(1): 57-106. Available: http://ac.els-cdn.com/S0047248400904032/1-s2.0S0047248400904032-main.pdf?_tid=3be56dfc-99ca-11e6-adaf (Accessed 24 October 2016).
- Jaitley, S. and Saraswathi, T. R. 2012. Pathophysiology of Langerhans cells. *International Journal of Oral and Maxillofacial Pathology* (online), 16(2): 239-244. Available: <https://www.ncbi.nlm.nih.gov/pmc/articles/PMC3424941> (Accessed 12 May 2018).
- Jiang, J., Akinseye, O., Tovar-Garza, A. and Pandya, A. G. 2018. The effect of melasma on self-esteem: a pilot study. *International Journal of Women's Dermatology* (online), 4(1): 38-42. Available: <https://ac.els-cdn.com/S2352647517300941/1-s2.0-> (Accessed 09 May 2018).
- Jonczyk-Matysiak, E., Weber-Dabrowska, B., Zaczek, M., Miedzybrodzki, R., Letkiewicz, S., Lusiak-Szelchowska, M. and Gorski, A. 2017. Prospects of phage application in the treatment of acne caused by propionibacterium acnes. *Frontiers of Microbiology* (online), 8(164): 1-11. Available: <https://www.frontiersin.org/articles/10.3389/fmicb.2017.00164/full> (Accessed 14 October 2019).
- Jones, C. G., Plummer, J. A. and Barbour, E. L. 2007. Non-destructive sampling of Indian sandalwood (*Santalum album* L.) for oil content and composition. *Journal of Essential Oil Research* (online), 19(2): 157-164. Available: <https://media.proquest.com/media/pq/classic/doc/1268068361/fmt/pi/rep/NONE?cit%3Aauth=Jones%2C+Christopher+G%3BPlummer%2C+Julie+A%3BBarbour%2C+> (Accessed 05 September 2019).
- Jones, M. L. 2014. Personal hygiene 3.2: anatomy and physiology (A&P) of the skin. *British Journal of Healthcare Assistants* (online), 8(8): 374-375. Available: <https://www.magonlinelibrary.com/doi/abs/10.12968/bjha.2014.8.8.374?journalCode=bjha> (Accessed 21 February 2017).

Joshi, S. L. and Pawar, A. H. 2015. Herbal cosmetics and cosmeceuticals: an overview. *Natural Products Chemistry & Research* (online), 3(2): 1-8. Available: <http://www.esciencecentral.org/journals/herbal-cosmetics-and-cosmeceuticals-an-overview-2> (Accessed 27 October 2015).

Kaczmarczyk, D., Strub, D. J., Polowy, A., Wilk, K. A. and Lochyński, S. 2015. selected essential oils in cosmetic emulsions: process-oriented stability studies and antimicrobial activity. *Natural Volatiles and Essential Oils* (online), 2(4): 27-39. Available: <https://dergipark.org.tr/download/article-file/185271> (Accessed 04 September 2019).

Kamagaju, L., Morandini, R., Gahongayire, F., Stevigny, C., Ghanem, G., Pirotte, G. and Duez, P. 2016. Survey on skin lightening practices and cosmetics in Kigali Rwanda. *International Journal of Dermatology* (online), 55(1): 45-51. Available: <https://onlinelibrary.wiley.com/doi/epdf/10.1111/ijd.12833> (Accessed 09 September 2019).

Kang, H.Y. and Ortonne, J. 2010. What should be considered in treatment of melasma. *Annals of Dermatology* (online), 22(4): 373-378. Available: <https://www.ncbi.nlm.nih.gov/pmc/articles/PMC2991712/pdf/ad-22-373.pdf> (Accessed 29 August 2019).

Kanlayavattanakul, M. and Lourith, N. 2011. Body malodours and their topical treatment agents. *International Journal of Cosmetic Science* (online), 33(4): 298-311. Available: <https://www.ncbi.nlm.nih.gov/pubmed/21401651> (Accessed 10 July 2019).

Kanthraj, G. R. 2010. Skin-lightening agents: new chemical and plant extracts – ongoing search for the holy grail. *Indian Journal of Dermatology, Venereology and Leprology* (online), 76(1): 3-6. Available: <http://www.ijdvl.com/article.asp?issn=0378-6323;year=2010;volume=76;issue=1;spage=3;epage=6;aulast=Kanthraj> (Accessed 02 September 2019).

Kaufman, B. P., Aman, T. and Alexis, A. F. 2018. Postinflammatory hyperpigmentation: epidemiology, clinical presentation, pathogenesis and treatment. *American Journal of Clinical Dermatology* (online), 19(4): 489-503. Available: <https://media.proquest.com/media/hms/PFT/1/Pmer7?cit%3Aauth=Kaufman%2C+> (Accessed 04 October 2019).

Kejlova, K., Jirova, D. Bendova, H., Gajdos, P. and Kolarova, H. 2010. Phototoxicity of essential oils intended for cosmetic use. *Toxicology in Vitro* (online), 24(8): 2084-2089. Available: <https://pdf.sciencedirectassets.com/271266/1-s2.0-S0887233310X0008X/1-s2.0-S0887233310001864/main.pdf?X-Amz> (Accessed 24 October 2019).

Kerscher, M. and Buntrock, H. 2011. Update on cosmeceuticals. *Journal of the German Society of Dermatology* (online), 9(4): 314-327. Available: <http://web.b.ebscohost.com/ehost/pdfviewer/pdfviewer?vid=1&sid=ddaee475-39f8-457f-8574-94f3af77e83b%40pdc-v-sessmgr03> (Accessed 11 July 2019).

Kolarsick, P. A. J., Kolarsick, M. A. and Goodwin, C. 2011. Anatomy and physiology of the skin. *Journal of the Dermatology Nurses' Association* (online), 3(4): 203-213. Available: https://journals.lww.com/jdnaonline/Fulltext/2011/11000/Anatomy_and_Physiology_of_the_Skin (Accessed 02 February 2017).

Kole, P. L., Jadhav, H. R., Thakurdesai, P. and Nagappa, A. N. 2005. Cosmetics potential of herbal extracts. *Birla Institute of Technology and Science* (online) 4(4): 315-321. Available <http://www.fedmaps.org/fedmaps-files/cosmetics-potential-of-herbal-extracts.pdf> (Accessed 2 October 2015).

Konda, S., Geria, A. N. and Halder, R. M. 2012. New horizons in treating disorders of hyperpigmentation in skin color. *Seminars in Cutaneous Medicine and Surgery* (online), 31(1): 133-139. Available: http://www.ecardiologynews.com/fileadmin/content_pdf/san/scms_pdf/SCMS_Vol31_no2_Hyperpigmentation.pdf (Accessed 16 October 2014).

Kubba, R., Bajaj, A. K., Thappa, D. M., Sharma, R., Vedamurthy, M., Dhar, S., Criton, S., Fernandez, R., Kanwar, A. J., Khopkar, U., Kohli, M., Kurivipe, V. P., Lahiri, K., Madnani, N., Parikh, D., Pujara, S., Rajababu, K. K., Sacchidanand, S. S., Sharma, V. K. and Thomas, J. 2009. Acne in India: guidelines for management – IAA consensus document. *Indian Journal of Dermatology, Venereology and Leprology* (online), 75(7): 54. Available: <http://www.ijdv1.com/article.asp?issn=0378-6323;year=2009;volume=75;issue=7;spage=54;epage=54> (Accessed 29 August 2019).

Kubiak, M. and Rotsztein, H. 2012. Effects of hormonal changes in women on skin pigmentation: *Przegląd Menopauzalny* (online), 16(3): 228-232. Available: <https://search.proquest.com/docview/1237577045?pq-origsite=summon> (Accessed 16 September 2019).

Kumar, B., Pathak, R., Mary, P. B., Jha, D., Sardana, K. and Gautam, H. K. 2016. New insights into acne pathogenesis: exploring the role of acne-associated microbial populations. *Dermatologica Sinica* (online), 34(2): 67-73. Available: <https://pdf.sciencedirectassets.com/280171/1-s2.0-S1027811716X00031/1-s2.0-> (Accessed 14 October 2019).

Kumar, P. and Paulose, R. 2014. Patch testing in suspected allergic contact dermatitis to cosmetics. *Dermatology Research and Practice* (online), 2014(1): 1-5. Available: <https://media.proquest.com/media/pq/classic/doc/3796626041/fmt/pi/rep/NONE?cit%> (Accessed 10 May 2016).

Kumar, S., Massie, C. and Dumonceaux, M. D. 2006. Comparative innovative business strategies of major players in cosmetic industry. *Innovative Business Strategies* (online), 106(3): 285-306. Available: <https://www.emerald.com/insight/content/doi/10.1108/02635570610653461/full/html> (Accessed 11 July 2019).

Kunicka-Styczynska, A., Sikora, M. and Kalemba, D. 2011. Lavender, tea tree and lemon oils as antimicrobials in washing liquids and soft body balms. *International Journal of Cosmetic Science* (online), 33(1): 53-61. Available: <http://web.b.ebscohost.com/ehost/pdfviewer/pdfviewer?vid=1&sid=809dc4f6-f2d9-4692-b244-03f046c83783%40sessionmgr101> (Accessed 20 September 2019).

Kuriakose, S. and Joe, H. 2012. Qualitative and quantitative analysis in sandalwood oils using near infrared spectroscopy combined with chemometric techniques. *Food Chemistry* (online), 135(1): 213-218. Available: <https://www.sciencedirect.com/science/article/pii/S0308814612007364> (Accessed 05 September 2019).

Kurokawa, I., Danby, F. W., Ju, Q., Wang, X., Xiang, L. F., Xia, L., Chen, W., Nagy, I., Picardo, M., Suh, D. H., Ganceviciene, R., Schagen, S., Tsatsou, F. and Zouboulis, C. C. 2009. New developments in our understanding of acne pathogenesis and treatment. *Experimental Dermatology* (online), 18 (6): 821-832. Available: <http://web.b.ebscohost.com/ehost/pdfviewer/pdfviewer?vid=1&sid=ca37ba66-e34b-4391-9d1b-12f88b24d31f%40sessionmgr103> (Accessed 14 October 2019).

Lacz, N. L., Vafaie, J., Kihiczak, N. I. and Schwartz, R. A. 2004. Postinflammatory hyperpigmentation: a common but troubling condition. *The International Society of Dermatology* (online), 43(5): 362-365. Available: <https://onlinelibrary.wiley.com/doi/full/10.1111/j.1365-4632.2004.02267.x> (Accessed 29 August 2019).

Lai-Cheong, J. E. and McGrath, J. A. 2013. Structure and function of skin, hair and nails. *Medicine* (online), 41(6): 317-320. Available: [https://www.medicinejournal.co.uk/article/S1357-3039\(13\)00111-4/pdf](https://www.medicinejournal.co.uk/article/S1357-3039(13)00111-4/pdf) (Accessed 02 April 2017)

Landau, J. M., Vergilis-Kalner, I., Goldberg, L. H., Geronemus, R. G. and Friedman, P. M. 2011. Treatment of Nevus of Ota in Fitzpatrick skin type VI with the 1064-nm QS Nd: YAG Laser. *Lasers in Surgery and Medicine* (online), 43(2): 65-67. Available: <https://onlinelibrary.wiley.com/doi/epdf/10.1002/lsm.21011> (Accessed 06 September 2019).

Lang, D., Mascarenhas, J. B. and Shea, C. R. 2013. Melanocytes, melanocyte stem cells and melanoma stem cells. *Clinics in Dermatology* (online), 31(2): 166-178. Available: <https://www.ncbi.nlm.nih.gov/pubmed/23438380> (Accessed 12 May 2017).

Lante, A. and Tinello, F. 2014. Citrus hydrosols as useful by-products for tyrosinase inhibition. *Innovative Food Science and Emerging Technologies* (online), 27(1): 154-159. Available: <https://pdf.sciencedirectassets.com/272137/1-s2.0-> (Accessed 23 October 2019).

Lavers, I. 2017. Exploring skin anatomy, function and site-specific treatment options. *Journal of Aesthetic Nursing* (online), 6(4): 172-179. Available: <http://web.a.ebscohost.com.dutlib.dut.ac.za/ehost/pdfviewer/pdfviewer?vid=1&sid> (Accessed 13 May 2018).

Lawrencet, B. M. 2001. Essential oils: from agriculture to chemistry. *The International Journal of Aromatherapy* (online), 10(3/4): 82-98. Available: <https://pdf.sciencedirectassets.com/272638/1-s2.0-S0962456200X00185/1-s2.0-> (Accessed 05 September 2019).

Lee, S. J., Hossaine, A. and Park, S. C. 2016. A potential anti-inflammation activity and depigmentation effect of Lespedeza bicolor extract and its fractions. *Saudi Journal of Biological Sciences* (online), 23(1): 9-14. Available: <https://www.ncbi.nlm.nih.gov/pmc/articles/PMC4705262/pdf/main.pdf> (Accessed 29 August 2019).

Leok, G. C. 2010. Lasers and light devices in the treatment of cosmetic pigmentary disorders in Asian skin. *Dermatology Nursing* (online), 22(2): 17-22. Available: <https://search.proquest.com/docview/347857016/fulltextPDF/46C26F73497C46C7PQ/1?accountid=10612> (Accessed 29 August 2019).

Leyden, J., Shergill, B., Micali, G., Downie, J. and Wallo, W. 2011. Natural options for the management of hyperpigmentation. *Journal of the European Academy of Dermatology and Venereology* (online), 25(1): 1140-1145. Available: <http://www.ncbi.nlm.nih.gov/pubmed/21623927>

Lin, J. Y. and Fisher, D. E. 2007. Melanocyte biology and skin pigmentation. *Nature* (online), 445(7130): 843-850. Available: <https://www.ncbi.nlm.nih.gov/pubmed/17314970> (Accessed 05 April 2018).

Little, C. A., Roberts, S. C., Jones, B. C. and DeBruine, L. M. 2012. The perception of attractiveness and trustworthiness in male faces affects hypothetical voting decisions differently in wartime and peacetime scenarios. *The Quarterly Journal of Experimental Psychology* (online), 65(10): 2018-2032. Available: <https://journals.sagepub.com/doi/pdf/10.1080/17470218.2012.677048> (Accessed 11 July 2019).

Lopaciuk, A. and Loboda, M. 2013. Global beauty industry trends in the 21st century: *Management, Knowledge and Learning International Conference 2013* (online), 19-21 June. Available: <http://www.toknowpress.net/ISBN/978-961-6914-02-4/papers/ML13-365.pdf> (Accessed 11 July 2019).

Łopaciuk, A. and Łoboda, M. 2013. *Global beauty industry trends in the 21st century*. Management, Knowledge and Learning International Conference (online), 19-21 June 2013. Available: <http://www.toknowpress.net/ISBN/978-961-6914-02-4/papers/ML13-365.pdf> (Accessed 05 September 2019).

Luebberding, S., Krueger, N. and Kerscher, M. 2013. Age-related changes in skin barrier function: quantitative evaluation of 150 female subjects. *International Journal of Cosmetic Science* (online), 35(1), 183-190. Available: <https://www.ncbi.nlm.nih.gov/pubmed/23113564> (Accessed 08 February 2018).

Lulevich, V., Hsin-ya, Y., Rivkah Isseroff, R. and Gang-yu, L. 2010. Single cell mechanics of keratinocyte cells. *Ultramicroscopy* (online), 110(12): 1435-1442. Available: <https://pdf.sciencedirectassets.com/271581/1-s2.0-S0304399110X00110/1-s2.0> (Accessed 28 August 2019).

Lundov, M. D., Johansen, J. D., Zachariae, C., and Moesby, L. 2011. Low-level efficacy of cosmetic preservatives. *International Journal Of Cosmetic Science* (online), 33(2): 190-196. Available: <https://onlinelibrary.wiley.com/doi/full/10.1111/j.1468-2494.2010.00619.x> (Accessed 11 July 2019).

Lv, C., Hou, J, Xie, W. and Cheng, H. 2015. Investigation on formaldehyde release from preservatives in cosmetics. *International Journal of Cosmetic Science* (online), 37(1): 474-478. Available: <https://www.ncbi.nlm.nih.gov/pubmed/25704726> (Accessed 11 July 2019).

Magin, P., Adams, J., Heading., Pond, D. and Smith, W. 2006. The causes of acne: a qualitative study of patient perceptions of acne causation and their implications for acne care. *Dermatology Nursing* (online), 18(4): 344-370. Available: <https://media.proquest.com/media/pq/classic/doc/1113105131/fmt/pi/rep> (Accessed 09 July 2019).

Mahdalena, Jusuf, N. K. and Putra, I. B. 2018. Melasma characteristic in hormonal contraceptive acceptors at Kelurahan Mangga Kecamatan Medan Tuntungan, Medan-Indonesia. *Bali Medical Journal* (online), 7(3): 645-649. Available: <https://www.balimedicaljournal.org/index.php/bmj/article/viewFile/1000/pdf> (Accessed 16 September 2019).

Maldonado, M. C., Aban, M. P., Navarro and A. R. 2013. Chemicals and lemon essential oil effect on *Alicyclobacillus acidoterrestris* viability. *Brazilian Journal of Microbiology* (online), 44(4): 1133-1137. Available: <http://www.scielo.br/pdf/bjm/v44n4/15.pdf> (Accessed 27 September 2019)

Malek, J., Chedraoui, A., Nikolic, D., Barouti, N., Ghosn, S. and Abbas, O. 2013. Successful treatment of hydroquinone-resistant melasma using topical methimazole. *Dermatologic Therapy* (online), 26(1): 69-72. Available: <https://www.ncbi.nlm.nih.gov/pubmed/23384022> (Accessed 02 September 2019).

Mallman, M. and Lee, H. 2017. Isolated learners: young mature-aged students, university culture, and desire for academic sociality. *International Journal of Lifelong Education*, 36(5): 512-525. Available: <https://www.tandfonline.com/doi/pdf/10.1080/02601370.2017.1302012?needAccess=true> (Accessed 22 October 2019).

Manga, P., Kerr, R., Ramsay, M., and Kromberg, J. G. R. 2013. Biology and genetics of oculocutaneous albinism and vitiligo – common pigmentation disorders in southern Africa: *South African Medical Journal* (online), 103(12): 984-988. Available: <http://www.samj.org.za/index.php/samj/article/view/7046/5574> (Accessed 09 July 2019).

Martinelli, L., Rosa, J. M., Ferreira, C. S. B., Nascimento, G. M. L., Freitas, M. S., Pizato, L. C., Santos, W. O., Pires, R. F., Okura, M. H., Malpass, G. R. P. and Granato, A. C. 2017. Antimicrobial activity and chemical constituents of essential oils and oleoresins extracted from eight pepper species. *Ciencia Rural* (online), 47(5): 1-7. Available: <http://www.scielo.br/pdf/cr/v47n5/1678-4596-cr-47-05-e20160899.pdf> (Accessed 05 September 2019).

Marway, H. 2018. Should we genetically select for the beauty norm of fair skin. *Health Care Analysis* (online), 26(3): 246-268. Available: <https://media.proquest.com/media/hms/PFT/1/mPmP6?cit%3Aauth=Marway%2C+Herjeet&cit%3Atitle=Should+We+Genetically+Select+for+the+Beauty+Norm+of+Fair> (Accessed 26 September 2019).

Marza, L. 2014. Laser facial hair removal protocol and key consultation considerations. *Journal of Aesthetic Nursing* (online), 3(9): 436-441. Available: <http://web.a.ebscohost.com/ehost/pdfviewer/pdfviewer?vid=1&sid=f655533c-f5c0-468e-8c51-5537c1f10f42%40sessionmgr4007> (Accessed 09 October 2019).

Matic, M. and Puh, B. 2015, Consumers purchase intentions towards natural cosmetics. *Econviews* (online), 29(1): 53-64. Available: <https://search.proquest.com/docview/1802592263?pq-origsite=summon>. (Accessed 11 July 2019).

Matsuura, R., Hiroyuki, U. and Masayoshi, S. 2006. Tyrosinase inhibitory activity of citrus essential oils. *Journal of Agricultural and Food Chemistry* (online), 54(6): 2309-2313. Available: <https://dut.summon.serialssolutions.com/search?s.q=Tyrosinase+inhibitory+activity> (Accessed 15 October 2019).

Mauricio, T., Karmon, Y. and Khaiat, A. 2011. A randomized and placebo-controlled study to compare the skin-lightening efficacy and safety of lignin peroxidase cream vs. 2% hydroquinone cream. *Journal of Cosmetic Dermatology* (online), 10(4): 253-259. Available: <http://web.b.ebscohost.com/ehost/pdfviewer/pdfviewer?vid=1&sid=d47c1ce6-792f-470d-852e-2d6005b8a813%40pdc-v-sessmgr02> (Accessed 03 September 2019).

McLafferty, E., Hendry, C. and Farley, A. 2012. The integumentary system: anatomy, physiology and function of skin. *Nursing Standard* (online), 27(3): 35-42. Available: <https://www.ncbi.nlm.nih.gov/pubmed/23248884> (Accessed 03 February 2018).

Mendoza, C. G., Singzon, I. A. and Handog, E. B. 2014. A randomized, double-blind, placebo-controlled clinical trial on the efficacy and safety of 3% *Rumex occidentalis* cream versus 4% hydroquinone cream in the treatment of melasma among Filipinos. *International Journal of Dermatology* (online), 53(11): 1412-1416. Available: <https://onlinelibrary.wiley.com/doi/full/10.1111/ijd.12690> (Accessed 03 September 2019).

Meyer, W. and Seegers, U. 2012. Basics of skin structure and function in elasmobranchs: a review. *Journal of Fish Biology* (online), 80(5): 1940-1967. Available: <https://onlinelibrary.wiley.com/doi/abs/10.1111/j.1095-8649.2011.03207.x> (Accessed 11 October 2017).

Michelle, G. and Hye-Shin, K. 2009. The relationship between consumer involvement and brand perceptions of female cosmetic consumers. *Journal of Brand Management* (online), 17(2): 114-133. Available: <https://search.proquest.com/docview/232487252?pq-origsite=summon> (Accessed 11 July 2019).

Miranda, F. A., Kenneth, M. W., Peter, E. and Howard, M. I. 2007. Structural characteristics of the aging skin: a review. *Cutaneous and Ocular Toxicology* (online), 26(4): 343-357. Available: <https://dut.summon.serialssolutions.com/search?s.q=Structural+Characteristics+of+the> (Accessed 4 November 2019).

Misharina, T. A. and Samusenko, A. L. 2008. Antioxidant properties of essential oils from lemon, grapefruit, coriander, clove and their mixtures. *Applied Biochemistry and Microbiology* (online), 44(4): 438-442. Available: <http://search.proquest.com/docview/231008828?pq-origsite=summon> (Accessed 15 September 2014).

Misra, B. B. and Dey, S. 2013. Biological activities of East Indian Sandalwood tree, *Santalum album*. *PeerJ PrePrints* (online), 96(1): 1-30. Available: https://journals.scholarsportal.info/search?q=&search_in=ISSN (Accessed 05 September 2019).

Mizukoshi, K, Nakamura, T. and Oba, A. 2015. The relationship between dermal papillary structure and skin surface properties, color, and elasticity. *Skin Research and Technology* (online), 22(3): 295-304. Available: <https://www.ncbi.nlm.nih.gov/pubmed/26336894> (Accessed 02 August 2017).

Mizutani, Y., Mitsutake, S., Tsuji, K., Kihara, A. and Igarashi, Y. 2009. Ceramide biosynthesis in keratinocyte and its role in skin function. *Biochimie* (online), 91(1): 874-790. Available: <https://www.ncbi.nlm.nih.gov/pubmed/19364519> (Accessed 06 February 2018).

Mlosek, R. K., Wozniak, W., Malinowska, S., Migda, B., Serafin-Król, M and, Milek, T. 2012. The removal of post-sclerotherapy pigmentation following sclerotherapy alone or in combination with crossectomy. *European Journal of Vascular and Endovascular Surgery* (online), 43(1): 100-105. Available: <https://pdf.sciencedirectassets.com/272423/1-s2.0-S1078588411X0014X/1-s2.0-S1078588411006721/main.pdf?X-Amz-Date=20190830T112108Z&X-Amz-> (Accessed 30 August 2019).

Moon, J., Yoon, J. Y., Yang, J. H., Kwon, H. H., Min, S. and Suh, D. H. 2019. Atrophic acne scar: a process from altered metabolism of elastic fibres and collagen fibres based on transforming growth factor- β 1 signalling. *British Journal of Dermatology* (online), March. Available: <https://onlinelibrary.wiley.com/doi/epdf/10.1111/bjd.17851> (Accessed 14 October 2019).

Moshammer, H., Simic, S. and Haluza, D. 2017. UV-radiation: from physics to impacts. *International Journal of Environmental Research and Public Health* (online), (online), 14(2): 1-5. Available: <https://www.ncbi.nlm.nih.gov/pmc/articles/PMC5334754/pdf/ijerph-14-00200.pdf> (Accessed 09 October 2019).

Moy, R. L. and Levenson, C. 2017. Sandalwood album oil as a botanical therapeutic in dermatology. *Journal of Clinical and Aesthetic Dermatology* (online), 10(10): 34-39. Available: https://www.ncbi.nlm.nih.gov/pmc/articles/PMC5749697/pdf/jcad_10_10_34.pdf (Accessed 15 October 2019).

Mukherjee, P. K., Maity, N., Nema, N. K. and Sarkar, B. K. 2011. Bioactive compounds from natural resources against skin aging. *Phytomedicine* (online), 19(1): 64-73. Available: http://www.pnei-it.com/1/upload/bioactive_compounds_from_natural_resources_against_skin_aging.pdf (Accessed 04 September 2019).

Narayanaswamy, R. and Ismail, I. S. 2015. Cosmetic potential of Southeast Asian herbs: an overview. *International Journal of Food Properties* (online), 14(3): 419-128. Available: [https://media.proquest.com/media/hms/PFT/1/8bWNA?cit%](https://media.proquest.com/media/hms/PFT/1/8bWNA?cit%25) (Accessed 04 September 2019).

Natale, C. A., Duperrier, E. K., Zhang, J., Sadeghi, R., Dahal, A., O'Brien, K. T., Cookson, R., Winkler, J. D. and Ridky, T. W. 2016. Sex steroids regulate skin pigmentation through nonclassical membrane-bound receptors: *Cell biology Human Biology and Medicine* (online), 5(2016): 1-16. Available: <https://www.ncbi.nlm.nih.gov/pmc/articles/PMC4863824/pdf/elife-15104.pdf> (Accessed 05 September 2019).

Negishi, K., Akita, H., Tanaka, S., Yokoyama, Y., Wakamatsu, S. and Matsunaga, K. 2013. Comparative study of treatment efficacy and the incidence of post-inflammatory hyperpigmentation with different degrees of irradiation using two different quality-switched lasers for removing solar lentigines on Asian skin. *Journal of the European Academy of Dermatology and Venereology* (online), 27(3): 307-312. Available: <https://onlinelibrary.wiley.com/doi/epdf/10.1111/j.1468-3083.2011.04385.x> (Accessed 30 August 2017).

Nestor, M., Bucay, V., Callender, V., Cohen, J.L., Sadick, N. and Waldorf, H. 2014. Polypodium leucotomos as an adjunct treatment of pigmentary disorders. *The Journal of Clinical Aesthetic Dermatology* (online), 7(3): 13-17. Available: <https://www.ncbi.nlm.nih.gov/pmc/articles/PMC3970827/?tool=pmcentrez&report=abstract> (Accessed 29 August 2019).

Nicolaidou, E. and Katsambas, A. D. 2014. Pigmentation disorders: hyperpigmentation and hypopigmentation. *Clinics in Dermatology* (online), 32(1): 66-72. Available: <https://www.sciencedirect.com/science/article/pii/S0738081X1300093X> (Accessed 28 August 2019).

Nieuweboer-Krobotova, L. 2013. Hyperpigmentation: types, diagnostics and targeted treatment options. *Journal of the European Academy of Dermatology and Venereology* (online), 27(1): 2-4. Available: <https://onlinelibrary.wiley.com/doi/epdf/10.1111/jdv.12048> (Accessed 29 August 2019).

Nohynek, G. J., Antignac, E., Re, T. and Toutain, H. 2010. Safety assessment of personal care products/cosmetics and their ingredients. *Toxicology and Applied Pharmacology* (online), 243(1):239-259. Available: <http://courses.engr.uky.edu/CME/cme470/cme%20470%20f10/final%20materials/nohynek%202010.pdf> (Accessed 23 June 2015).

Nordlund, J., Grimes, P. and Ortonne, J. 2006. The safety of hydroquinone. *Journal of Cosmetic Dermatology*(online),5(2):168-170. Available: <http://web.b.ebscohost.com/ehost/pdfviewer/pdfviewer?vid=1&sid=c887f7ff-b4b3-42ca-959b-9078b8225f3a%40pdc-v-sessmgr04> (Accessed 03 September 2019).

Nordlund, J. J. 2007. Hydroquinone: its value and safety. Commentary on the US FDA proposal to remove hydroquinone from the over-the-counter market. *Expert Review of Dermatology*(online),2(3):283-287.Available:
<https://media.proquest.com/media/pq/classic/doc/2545093201/fmt/pi/rep/NONE?cit%3Aauth=Nordlund%2C+James+J&cit%3Atitle=Hydroquinone%3A+its+value+and> (Accessed 09 October 2019).

Nouveau, S., Agrawal, D., Kohli, M., Bernerd, F., Misra, N. and Nayak, C. S. 2016. Skin hyperpigmentation in Indian population: insights and best practice. *Indian Journal of Dermatology* (online), 61(5): 487-495. Available: <http://www.eijd.org/article.asp?issn=0019-5154;year=2016;volume=61;issue=5> (Accessed 11 October 2017).

Oprean, R., Oprean, L., Tamas, M., Sandulescu, R. and Roman, L. 2001. Essential oils analysis. II. Mass spectra identification of terpene and phenylpropane derivatives. *Journal of Pharmaceutical and Biomedical Analysis* (online), 24(5/6): 1163-1168. Available: <https://pdf.sciencedirectassets.com/271442/1-s2>. (Accessed 05 September 2019).

Owens, D. M. and Lumpkin, E. A. 2014. Diversification and specialization of touch receptors in skin. *Cold Spring Harbor Perspectives in Medicine* (online), 4(6): 1-12. Available: <https://www.ncbi.nlm.nih.gov/pmc/articles/PMC4031957/pdf/cshperspectmed-SKN-a013656.pdf> (Accessed 18 September 2019).

Padma, D., Satyamoorthy, K. and Bhat, K. M. R. 2015. Role of gap junctions between keratinocyte and melanocyte in melanogenesis. *Frontiers in Biology* (online), 10(6): 495-502. Available: <https://link.springer.com/article/10.1007%2Fs11515-015-1381> (Accessed 08 May 2018).

Pandey, A. K., Singh, P. and Tripathi, N. N. 2014. Chemistry and bioactivities of essential oils of some *Ocimum* species: an overview. *Asian Pacific Journal of Tropical Biomedicine* (online), 4(9): 682-694. Available: <https://pdf.sciencedirectassets.com/280743/1-s2.0-S2221169115X60060/1-s2.0> (Accessed 05 September 2019).

Pang, S., Wu, H., Wang, Q., Cai, M., Shi, W. and Shang, J. 2014. Chronic stress suppresses the expression of cutaneous hypothalamic pituitary adrenocortical axis elements and melanogenesis. *PLOS ONE* (online), 9(5): 1-11. Available: <https://journals.plos.org/plosone/article/file?id=10.1371/journal.pone.0098283&type=printable> (Accessed 20 September 2019).

Park, H. Y., Kosmadaki, M., Yaar, M., and Gilchrest, B. A. 2009. Cellular mechanisms regulating human melanogenesis. *Cell and Molecular Life Sciences* (online), 66(9): 1493-506. Available: <https://www.ncbi.nlm.nih.gov/pubmed/19153661> (Accessed 12 June 2017).

Parveen, A., Rabea, B., Parveen, R. and Ahmed, S. 2015. Challenges and guidelines for clinical trial of herbal drugs. *Symposium: Gastroenterology & Hepatology* (online), 7(4): 329-333. Available: <https://search.proquest.com/docview/1729124513/fulltextPDF/CB79DB1114F94B2DPQ/1?accountid=10612> (Accessed 10 July 2019).

Passeron, T., Genedy, R., Salah, L., Fusade, T., Kositratna, G., Laubach, H. J., Marini, L. and Badawi, A. 2019. Laser treatment of hyperpigmented lesions: position statement of the European Society of Laser in Dermatology. *European Academy of Dermatology* (online), 33(6): 987-1005. Available: <https://onlinelibrary.wiley.com/doi/full/10.1111/jdv.15497> (Accessed 09 July 2019).

Patel, D. R. 2015. Skin pigmentation. *International Journal of Child Health and Human Development* (online), 8(1): 21-28. Available: <https://www.questia.com/library/journal/1P3-3785964201/skin-pigmentation> (Accessed 10 August 2017).

Patel, N., Padhtare, D. and Saudagar, R. B. 2015. Newer trends in cosmetology. *World Journal of Pharmacy and Pharmaceutical Sciences* (online), 4(3): 483-502. Available: <https://www.google.co.za/url?sa=t&rct=j&q=&esrc=s&source=web&cd=3&ved=2ahUKEwil8Yyy4LbkAhUzTxUIHVGTD> (Accessed 04 September 2019).

Patkar, K. B. 2008. Herbal cosmetics in ancient India. *Indian Journal of Plastic Surgery* (online), 41(3): 134-137. Available: <http://www.bioline.org.br/abstract?id=pl08083> (Accessed 03 September 2019).

Persson, G., Johansson-Jankanpaa, E., Ganceviciene, R., Karadag, A. S., Bilgil, S. G., Omer, H. and Alexeyev, O. A. 2018. No evidence of follicular keratinocyte hyperproliferation in acne lesions as compared to autologous healthy hair follicles. *Experimental Dermatology* (online), 27(6):668-671. Available: <http://web.b.ebscohost.com/ehost/pdfviewer/pdfviewer?vid=1&sid=a99c88d4-8fa2-4e13-852e-10a83e2bb1da%40pdc-v-sessmgr01> (Accessed 14 October 2019).

Petit, A., Cohen-Ludmann, C. C., Clevenbergh, P., Bergmann, J. and Dubertret, L. 2006. Skin lightening and its complications among African people living in Paris. *Journal of the American Academy of Dermatology* (online), 55(5): 873-878. Available: <https://www.sciencedirect.com/science/article/pii/S0190962206015167> (Accessed 11 July 2019).

Pink, A., Anzengruber, F. and Navarini, A. A. 2017. Acne and hidradenitis suppurativa. *British Journal of Dermatology* (online), 178(3): 619-631. Available: <https://onlinelibrary.wiley.com/doi/epdf/10.1111/bjd.16231> (Accessed 04 October 2019).

Piqueres-Zubiaurre, T., Martinez de Lagran, Z., Gonzalez-Perez, R., Urtaran-Ibarzabal, A. and Perez de Nanclares, G. 2017. Familial progressive hyperpigmentation, cutaneous mastocytosis, and gastrointestinal stromal tumor as clinical manifestations of mutations in the c-KIT receptor gene. *Paediatric Dermatology* (online), 34(1): 84-89. Available: <https://onlinelibrary.wiley.com/doi/epdf/10.1111/pde.13040> (Accessed 09 July 2019).

Plonka, P. M., Passeron, T., Brenner, M., Tobin, D. J., Shibahara, S.A., Slominski, A. T., Kadekaro, A. L., Hershkovitz, D., Peters, E., Nordlund, J. J., Abdel-Malek, Z. K., Takeda, R. P., Ortonne, J. P., Hearing, J. K. and Schallreuter, K. U. 2009. What are melanocytes really doing all day long. *Experimental Dermatology* (online), 18(9): 799-819. Available: <https://www.ncbi.nlm.nih.gov/pubmed/19659579> (Accessed 26 April 2017).

Proksch, E., Brandner, J. M. and Jensen, J. 2008. The skin: an indispensable barrier. *Experimental Dermatology* (online), 17(12): 1063-1072. Available: <https://www.ncbi.nlm.nih.gov/pubmed/19043850> (Accessed 06 February 2018).

Purdy, S. and de Berker, D. 2011. Acne vulgaris. *Clinical Evidence* (online), 1714(1): 1-71. Available: <https://www.ncbi.nlm.nih.gov/pmc/articles/PMC3275168/pdf/2011-1714.pdf> (Accessed 29 August 2019).

Qidwai, A., Panday, M., Pathak, S., Kumar, R. and Dikshit, A. 2017. The emerging principles for acne biogenesis: a dermatological problem of puberty. *Human Microbiome Journal* (online), 4(1): 7-13. Available: <https://reader.elsevier.com/reader/sd/pii/S2452231717300064?> (Accessed 09 July 2019).

Qiu, J., Zhong, L., Zhou, M., Chen, D., Huang, X., Chen, J., Chen, M., Ni, H. and Cai, Z. 2016. Establishment and characterization of a reconstructed Chinese human epidermis model: *International Journal of Cosmetic Science* (online), 38(1): 60-67. Available: <https://www.ncbi.nlm.nih.gov/pubmed/26119692> (Accessed 02 March 2016).

Ramli, N. S. 2015. Immigrant entrepreneurs on the worlds successful global brands in the cosmetic industry. *Procedia - Social and Behavioral Sciences* (online), 195(1): 113-122. Available: <https://www.sciencedirect.com/science/article/pii/S187704281> (Accessed 11 July 2019).

Raut, J. S. and Karuppayil, S. M. 2014. A status review on the medicinal properties of essential oils. *Industrial Crops and Products* (online), 62(1): 250-264. Available: <https://pdf.sciencedirectassets.com/271144/1-s2.0-S0926669014X00105/1-s2.0-> (Accessed 05 September 2019).

Rendon, M., Berneburg, M., Arellano, I. and Picardo, M. 2006. Treatment of melasma. *Journal of the American Academy of Dermatology* (online), 54(5): 272-281. Available: <https://www.ncbi.nlm.nih.gov/pubmed/16631968> (Accessed 29 August 2019).

Rodrigues, M. and Pandya, A. G. 2015. Melasma: clinical diagnosis and management options. *Australasian Journal of Dermatology* (online), 56(3): 151-163. Available: http://wu4wl9yj2g.search.serialssolutions.com/?ctx_ver=Z39.88 (Accessed 29 August 2019).

Rolstad, B. S., Ermer-Seltun, J. and Bryant, R. A. 2011. Relating knowledge of anatomy and physiology to peristomal skin care. *Gastrointestinal Nursing* (online), 9(9): 3-9. Available: <https://www.magonlinelibrary.com/doi/abs/10.12968/gasn.2011.9.Sup3.3?journalCode=gasn> (Accessed 21 February 2017).

Roulin, A., Almasi, B., Meichtry-Stier, K. S. and Jenni, L. 2011. Eumelanin and pheomelanin-based colour advertise resistance to oxidative stress in opposite ways. *Journal of Evolutionary Biology*(online),24(10):2241-2247.Available: <https://onlinelibrary.wiley.com/doi/epdf/10.1111/j.1420-9101.2011.02353.x> (Accessed 18 September 2019).

Ruvolo, E., Fair, M., Hutson, A. and Liebel, F. 2018. Photoprotection against visible light-induced pigmentation. *International Journal of Cosmetic Science* (online), 40(6): 589-595. Available: <https://onlinelibrary.wiley.com/doi/epdf/10.1111/ics.12502> (Accessed 09 September 2019).

Sarkar, R., Ranjan, R., Garg, S., Garg, V. K. Sonthalia, S. N. D. and Bansal, S. 2016. Periorbital hyperpigmentation: a comprehensive review. *Journal of Clinical and Aesthetic Dermatology* (online),9(1):49-55.Available: https://www.ncbi.nlm.nih.gov/pmc/articles/PMC4756872/pdf/jcad_9_1_49.pdf (Accessed 09 July 2019).

Schallreuter, K. U., Kothari, S., Chavan, B. and Spencer, J. D. 2008. Regulation of melanogenesis--controversies and new concepts. *Experimental Dermatology* (online), 17(5): 395-404. Available: <https://www.ncbi.nlm.nih.gov/pubmed/18177348>. (Accessed 11 May 2017).

Scheinfeld, N. S. 2007. Melasma. *Dermatology for the Clinician* (online), 6(1): 35-37. Available:<https://onlinelibrary.wiley.com/doi/pdf/10.1111/j.1540-9740.2007.06338.x> (Accessed 29 August 2019).

Scherer, D. and Kumar, R. 2010. Genetics of pigmentation in skin cancer--a review. *Mutation Research*(online),705(2):141-153.Available: <https://www.ncbi.nlm.nih.gov/pubmed/20601102> (Accessed 29 August 2019).

Sebaratnam, D. F., Lim, A. C., Lowe, P. M., Goodman, G. J., Bekhor, P. and Richards, S. 2014. Lasers and laser-like devices: Part two. *Australasian Journal of Dermatology* (online), 55(1): 1-14.Available: <http://web.a.ebscohost.com/ehost/pdfviewer/pdfviewer?vid=1&sid=733adc9e-db1d-4c2f-bc71-331a810f7b35%40sessionmgr4006> (Accessed 30 August 2019).

Sehgal, V. N., Verma, P., Srivastava, G., Aggarwal, A. K. and Verma, S. 2011. Melasma: treatment strategy. *Journal of Cosmetic and Laser Therapy* (online), 13(6): 265-279. Available: <http://web.a.ebscohost.com/ehost/pdfviewer/pdfviewer?vid=1&sid=0ada0c9a-11f9-4057-98c1-1fa5b34ea529%40sdc-v-sessmgr03> (Accessed 29 August 2019).

Sengupta, A., Lichti, U. F., Carlson, B. A., Ryscavage, A. O., Gladdyshev, V. N., Yuspa, S. H. and Hatfield, D. L. 2010. Selenoproteins are essential for proper keratinocyte function and skin development: *PLOS ONE*(online),5(8):1-15.Available:

<http://journals.plos.org/plosone/article?id=10.1371/journal.pone.0012249> (Accessed 04 April 2017).

Shahriari, M., Kerr, P. E., Slade, K. and Grant-Kels, J. E. 2010. Vitamin D and the skin. *Clinics in Dermatology*(online),28(6):663-668.Available:

<https://pdf.sciencedirectassets.com/271159/1-s2.0-S0738081X10X00062/1-s2.0>. (Accessed 28 August 2019).

Sharma, B. and Sharma, A. 2012. Future prospect of nanotechnology in development of anti-aging formulations. *International Journal of Pharmacy and Pharmaceutical Sciences* (online), 4(3): 57-66. Available: <http://www.ijppsjournal.com/Vol4Issue3/4295.pdf> (Accessed 12 October 2014).

Sharma, M., Levenson, C., Browning, J.nC., Becker, E. M., Clements, I., Castella, P. and Coz, E. 2018. East Indian sandalwood oil is a phosphodiesterase inhibitor: a new therapeutic option in the treatment of inflammatory skin disease. *Frontiers in Pharmacology* (online), 9(200): 1-12. Available: <https://www.frontiersin.org/articles/10.3389/fphar.2018.00200/full> (Accessed 10 September 2019).

Sheth, A. M. and Pandya, A. G. 2011. Melasma: a comprehensive update. *American Academy of Dermatology* (online), 65(4): 689-697. Available: <https://www.sciencedirect.com/science/article/pii/S0190962211003094> (Accessed 29 August 2019).

Shetty, S. and Gokul, S. 2012. Keratinization and its disorders. *Oman Medical Journal* (online), 27(5):348-357.Available:

<https://www.ncbi.nlm.nih.gov/pmc/articles/PMC3472583/pdf/OMJ-D-11-00308.pdf> (Accessed 11 October 2019).

Shier, D., Butler, J. and Lewis, R. 2007. *Hole's human anatomy and physiology*. 11th ed. New York: McGraw Hill.

Shroff, H., Diedrichs, P. C. and Craddock, N. 2018. Skin colour, cultural capital and beauty products: an investigation of the use of skin fairness products in Mumbai, India. *Frontiers in Public Health*(online),5(365):1-9.Available:

<https://www.ncbi.nlm.nih.gov/pmc/articles/PMC5787082/pdf/fpubh-05-00365.pdf> (Accessed 09 May 2018).

Silpa-Archa, N., Kohli, I., Chaowattanapanit, S., Lim, H. W. and Hamzavi, I. 2017. Postinflammatory hyperpigmentation: a comprehensive overview epidemiology, pathogenesis, clinical presentation, and noninvasive assessment technique. *Journal of the American Academy of Dermatology*(online),77(4):591-605.Available:

<https://www.sciencedirect.com/science/article/pii/S0190962217301287> (Accessed 30 August 2019).

Singh, B. and Maibach, H. 2013. Climate and skin function: an overview *Skin Research and Technology* (online), 19(3), 207-212. Available: <https://www.ncbi.nlm.nih.gov/pubmed/23521370> (Accessed 08 February 2018).

Sitek, A., Źądzińska, E. and Rosset, I. 2012. Effects of psychological stress on skin and hair pigmentation in Polish adolescents. *Anthropological Review* (online), 75(1): 1-17. Available: <https://search.proquest.com/docview/1328681974?pq-origsite=summon> (Accessed 07 July 2019).

Situm, M., Kolic, M., Bolanca, Z., Ljubicic, I. and Misanovic, B. 2011. Melasma – updated treatments. *Collegium Antropologicum* (online), 35(2): 315-318. Available: <http://web.a.ebscohost.com/ehost/pdfviewer/pdfviewer?vid=1&sid=d2dba6e7-6f30-441a-b7a4-8c5dbeebeef3%40sessionmgr4008> (Accessed 29 August 2019).

Solano, F. 2014. Melanins: skin pigments and much more—types, structural models, biological functions, and formation routes. *New Journal of Science* (online), Available: <https://www.hindawi.com/journals/njos/2014/498276/> (Accessed 24 October 2016)

Solorzano-Santos, F. and Miranda-Novales, M. G. 2012. Essential oils from aromatic herbs as antimicrobial agents: current opinion in biotechnology (online), 23(2): 136-141. Available: <https://pdf.sciencedirectassets.com/272028/1-s2.0-> (Accessed 05 September 2019).

Sondenheimer, K. and Krutmann, J. 2018. Novel means for photoprotection. *Frontiers in Medicine* (online), 5(162): 1-5. Available: <https://www.frontiersin.org/articles/10.3389/fmed.2018.00162/full> (Accessed 26 September 2019).

Speeckaert, R., Van Gele, M., Speeckaert, M. M., Lambert, J. and Van Geel N. 2014. The biology of hyperpigmentation syndromes. *Pigment Cell & Melanoma Research* (online), 27(1): 512-524. Available: <http://web.a.ebscohost.com/ehost/pdfviewer/pdfviewer?vid=1&sid=bbf8c4f1-5822-4d2f-b756-8b24c7225108%40sessionmgr4007> (Accessed 29 August 2019).

Steflitsch, W. and Steflitsch, M. 2008. Clinical aromatherapy. *Practising Medicine* (online), 5(1): 74-85. Available: http://jonnsaromatherapy.com/pdf/Steflitsch_Clinical_Aromatherapy_2008.pdf (Accessed 04 September 2019).

Stephen-Haynes, J. 2013. The role of barrier protection in pressure ulcer prevention. *British Journal of Nursing* (online), 22(20): 52-58. Available: <https://pdfs.semanticscholar.org/59ac/0c4397c0dfe7f00f4be8536bdc9bca594673.pdf> (Accessed 03 February 2018).

Stephen-Haynes, J. 2014. The outcomes of barrier protection in periwound skin and stoma care: *British Journal of Nursing* (online), 23(5): 13-26. Available: <https://www.ncbi.nlm.nih.gov/pubmed/24642771> (Accessed 03 February).

Sumit, K., Swarankar, V., Sujata, S. and Ashish, B. 2012. Herbal cosmetics: used for skin and hair. *Inventi Journals* (online), 4(1): 1-7. Available: www.researchgate.net/...Herbal_Cosmetics_Used_for_Skin_and_Hair (Accessed 15 September 2014).

Sundaram, H. and Emer, J. 2011. Natural therapies for hyperpigmentation. *Journal of Drugs in Dermatology* (online), 10(9): 15-20. Available: <http://dut.summon.serialssolutions.com/document/show?id=FETCH-LOGICAL-e833> (Accessed 15 October 2014).

Surber, C and Kottner, J. 2017. Skin care products: what do they promise, what do they deliver. *Journal of Tissue Viability* (online), 26(1): 29-36. Available: <https://pdf.sciencedirectassets.com/276836/1-s2.0-S0965206X17X00028/1-s2>. (Accessed 27 August 2019).

Swalwell, H., Latimer, J., Haywood, R. M. and Birch-Machin, M. A. 2012. Investigating the role of melanin in UVA/UVB and hydrogen peroxide induced cellular and mitochondrial ROS production and mitochondrial DNA damage in human melanoma cells. *Free Radical Biology and Medicine* (online), 52(3): 626-634. Available: <https://pdf.sciencedirectassets.com/271331/1-s2.0-S0891584912X00029/1-s2.0> (Accessed 26 September 2019).

Swanson, C. L., Leo, T. L. and Finlay, D. 2014. Methods for improving the appearance of hyperpigmented skin using a synergistic composition comprising banyan tree, lotus, and clover serum fractions. USA patent, US8673372 B2.

Tanghetti, E. A., Kawata, A. K., Daniels, S. R., Yeomans, K., Burk, C. T. and Callender, V. D. 2014. Understanding the burden of adult acne. *Journal of Clinical and Aesthetic Dermatology* (online), 7(2): 22-30. Available: https://www.ncbi.nlm.nih.gov/pmc/articles/PMC3935648/pdf/jcad_7_2_22.pdf (Accessed 26 September 2019).

Tatebayashi, M., Oiso, N., Wada, T., Suzuki, K., Matsunaga, K. and Kawada, A. 2014. Possible allergic contact dermatitis with reticulate postinflammatory pigmentation caused by hydroquinone *The Journal of Dermatology* (online), 41(7): 669-670. Available: <http://web.b.ebscohost.com/ehost/pdfviewer/pdfviewer?vid=1&sid=45f697d0-bfb8-4fbe-b931-78146a05652a%40pdc-v-sessmgr02> (Accessed 02 September 2019).

Thakur, T., Negi, A. and Kush, L. 2013. Ayurvedicophoric designing of facial cosmeceutical models. *International Journal of Innovative Research and Development* (online), 2(8). Available: <http://www.ijird.com/index.php/ijird/article/viewFile/36198/29332> (Accessed 02 March 2015).

Thaysen-Petersen, D., Lin, J. Y., Nash, J. F., Beerwerth, F., Wulf, H. C., Philipsen, P. A. and Haedersdal, M. 2014. The role of natural and UV-induced skin pigmentation on low-influence IPL-induced side effects: a randomised controlled trial *Lasers in Surgery and Medicine* (online), 46(1): 104-111. Available: <https://onlinelibrary.wiley.com/doi/epdf/10.1002/lsm.22167> (Accessed 07 July 2019).

Thaysen-Petersen, D., Lin, J. Y., Nash, J. F., Beerwerth, F., Wulf, H. C., Philipsen, P. A. and Haedersdal, M. 2017. Side effects from intense pulsed light: importance of skin pigmentation, fluence level, and ultraviolet radiation—a randomized controlled trial. *Lasers in Surgery and Medicine* (online), 49(1): 88-96. Available: <https://onlinelibrary.wiley.com/doi/epdf/10.1002/lsm.22566> (Accessed 07 July 2019).

Thiboutot, D. M. 2000. The role of follicular hyperkeratinisation in acne. *Journal of Dermatological Treatment* (online), 11(2): 5-8. Available: <https://pennstate.pure.elsevier.com/en/publications/the-role-of-follicular-hyperkeratinization-in-acne> (Accessed 14 October 2019).

Thomas, R. J. 2010. *Advanced therapy in facial and plastic reconstructive surgery*. Shelton, CN: Peoples Medical Publishing House.

Thompson, A. E. 2015. Acne. *American Academy of Dermatology* (online), 313(6): 640. Available: <https://search.proquest.com/docview/1655805527?pq-origsite=summon> (Accessed 09 September 2019).

Tilles, G. 2014. Acne pathogenesis: history of concepts. *Dermatology* (online), 229(1): 1-46. Available: <https://media.proquest.com/media/pq/classic/doc/3466734961/fmt/pi/> (Accessed 14 October 2019).

Tongnuanchan, P. and Benjakul, S. 2014. Essential oils: extraction, bioactivities, and their uses for food preservation. *Journal of Food Science* (online), 79(7): 1231-1249. Available: http://wu4wl9yj2g.search.serialssolutions.com/?ctx_ver=Z39.88-2004&ctx_enc=info%3Aofi%2Fenc%3AUTF- (Accessed 05 September 2019).

Toombs, E. L. 2007. Hydroquinone – what is its future? *Dermatologic Therapy* (online), 20(3): 149-156. Available: <http://web.b.ebscohost.com/ehost/pdfviewer/pdfviewer?vid=1&sid=9afaf815-3f14-4854-9d2b-4b715c8380d7%40pdc-v-sessmgr06> (Accessed 30 August 2019).

Tse, T. W. 2010. Hydroquinone for skin lightening: safety profile, duration of use and when should we stop? *Journal of Dermatological Treatment* (online), 21(5): 272-275. Available: <http://web.a.ebscohost.com/ehost/pdfviewer/pdfviewer?vid=1&sid=e675f3bf-c514-4d7b-a5f9-9b1c0d21b14c%40sdc-v-sessmgr02> (Accessed 30 August 2019).

Tsuruta, D., Green, K. J., Getsios, S. and Jones, J. C. R. 2002. The barrier function of skin: how to keep a tight lid on water loss. *Trends in Cell Biology* (online), 12(8): 335-337. Available: <https://www.ncbi.nlm.nih.gov/pubmed/12191905> (Accessed 05 May 2017).

Vachiramon, V. and Thadanipon, K. 2011. Postinflammatory hypopigmentation. *Clinical and Experimental Dermatology* (online), 36(1): 708-714. Available: <http://web.a.ebscohost.com/ehost/pdfviewer/pdfviewer?vid=1&sid=e19f990c-11db-> (Accessed 28 August 2019).

Vaishnani, J. B. 2015. Secondary comedones after waxing. *Indian Journal of Dermatology, Venereology and Leprology* (online), 81(1): 96. Available: <http://www.ijdvl.com/article.asp?issn=0378-6323;year=2015;volume=81;issue=1;spage=96;epage=96;aualast=Vaishnani> (Accessed 30 July 2017).

Valgimigli, L., Gabbanini, S., Berlini, E., Lucchi, E., Beltrami, C. and Bertarelli, Y. L. 2012. Lemon (Citrus Limon) essential oil enhances the trans-epidermal release of lipid (A, E) and water (B6, C) soluble vitamins from topical emulsions in reconstructed human epidermis: *International Journal of Cosmetic Science* (online), 34(1): 347-356. Available: <https://onlinelibrary.wiley.com/doi/full/10.1111/j.1468-2494.2012.00725> (Accessed 10 July 2019).

Vashi, N. A. and Kundu, R. V. 2013. Facial hyperpigmentation: causes and treatment. *British Journal of Dermatology* (online), 169(3): 41-56. Available: <https://onlinelibrary.wiley.com/doi/epdf/10.1111/bjd.12536> (Accessed 29 August 2019).

Venus, M., Waterman J. and McNab, I. 2010. Basic physiology of the skin. *Surgery* (online), 28(10), 469-472. Available: [https://www.surgeryjournal.co.uk/article/S0263-9319\(10\)00159](https://www.surgeryjournal.co.uk/article/S0263-9319(10)00159) (Accessed 2 March 2017).

- Venus, M., Waterman J. and McNab, I. 2011. Basic physiology of the skin. *Surgery* (online), 29(10): 474-474. Available: [https://www.surgeryjournal.co.uk/article/S0263-9319\(11\)00131-1/pdf](https://www.surgeryjournal.co.uk/article/S0263-9319(11)00131-1/pdf). (Accessed 02 April 2017)
- Walters, K. A. and Roberts, M. S. 2008. *Dermatologic, cosmeceutic and cosmetic development: therapeutic and novel approaches*. New York: Informa Healthcare.
- Wang, C. and Chen, C. 2012. Effect of spot size and fluence on Q-switched alexandrite laser treatment for pigmentation in Asians: a randomized, double-blinded, split-face comparative trial. *Journal of Dermatological Treatment* (online), 23(5): 1471-1753. Available: <http://web.a.ebscohost.com/ehost/pdfviewer/pdfviewer?vid=1&sid=b4402574-4e34-4988-9f34-d71bd8b394f7%40sdc-v-sessmgr03> (Accessed 30 August 2019).
- Wang, Y., Xu, R., He, W., Yao, Z., Li, H., Zhou, J., Tan, J., Yang, S., Zhan, R., Luo, G. and Wu, J. 2015. Three-dimensional histological structures of the human dermis. *Tissue Engineering* (online), 21(9): 932-944. Available: <https://www.ncbi.nlm.nih.gov/pubmed/25781868> (Accessed 11 October 2017).
- White, R. M. and Zon, L. I. 2008. Melanocytes in development, regeneration, and cancer. *Stem Cell Review* (online), 3(3): 242-52. Available: <https://www.ncbi.nlm.nih.gov/pubmed/18786412> (Accessed 02 March 2017).
- Wickett, R. R. and Visscher, M. O. 2006. *Structure and function of the epidermal barrier*. Association for Professionals in Infection Control and Epidemiology (online). Available: http://ac.elscdn.com/S0196655306009503/1-s2.0-S0196655306009503-main.pdf?_tid=8c3f2f0c-99c2- (Accessed 24 October 2016).
- Williams, K. and Almasi, M. R. 2005. Help for waxing woes. *Shape* (online), 24(10): 98. Available: <https://media.proquest.com/media/pq/classic/doc/845945801/fmt/pi/rep/NONE?cit%> (Accessed 09 October 2019).
- Williams, H. C., Dellavalle, R. P. and Garner, S. 2012. Acne vulgaris. *Lancet* (online), 379 (9813): 361-372. Available: <https://pdf.sciencedirectassets.com/271074/1-s2.0-S0140673612X60045/1-s2.0-S0140673611603218/main.pdf?X-Amz> (Accessed 14 October 2019).

Wong, R., Geyer, S., Weninger, W., Guimberteau, J. and Wong, J. K. 2015. The dynamic anatomy and patterning of skin. *Experimental Dermatology* (online), 25(2): 92-98. Available: <https://kinesiotaping.com/wp-content/uploads/2015/11/Gui2mberteau-Wong-2016.pdf> (Accessed 25 October 2017).

Woo, S., Lumpkin, E.A. and Patapoutian, A. 2015. Merkel cells and neurons keep in touch. *Trends in Cell Biology* (online), 25(2): 74-81. Available: <https://www.ncbi.nlm.nih.gov/pmc/articles/PMC4312710/pdf/> (Accessed 12 May 2018).

Woolery-Lloyd, H. and Kammer, J. N. 2011. Treatment of hyperpigmentation. *Seminars in Cutaneous Medicine and Surgery* (online), 30(1): 171-175. Available: http://www.ecardiologynews.com/fileadmin/content_pdf/san/scms_pdf/Vol30_i3_Woolery-Lloyd.pdf (Accessed 15 September 2015).

Wright, C. I., Van-Buren, L., Kroner, C. I. and Koning, M. M. G. 2007. Herbal medicines as diuretics: a review of the scientific evidence. *Journal of Ethnopharmacology* (online), 114(1): 1-31. Available: <https://reader.elsevier.com/reader/sd/pii/S0378874107003662?token=07634261041> (Accessed 11 July 2019).

Wright, C. Y., Reddy, T., Mathee, A. and Street, R. A. 2017. Sun exposure, sun related symptoms nad sun protection practices in an African informal traditional medicines market: *International Journal of Environmental Research and Public Health* (online), 14(10): 1-7. Available: <https://www.ncbi.nlm.nih.gov/pmc/articles/PMC5664643/pdf/ijerph-14-01142.pdf> (Accessed 23 October 2019).

Yadav, A. 2018. Quality of life in patients with acquired pigmentation: an observational study: *Journal of Cosmetic Dermatology* (online), 17(6): 1293-1294. Available: <https://onlinelibrary.wiley.com/doi/epdf/10.1111/jocd.12686> (Accessed 11 October 2019).

Yamaguchi, Y. and Hearing, V. J. 2014. Melanocytes and their diseases. *Cold Spring Harbor Perspectives in Medicine* (online), 4(5): 1-18. Available: <https://www.ncbi.nlm.nih.gov/pmc/articles/PMC3996377/pdf/cshperspectmed-SKN-a017046.pdf> (Accessed 11 May 2017).


- Yazgan, H., Ozogul, Y. and Kuley, E. 2019. Antimicrobial influence of nanoemulsified lemon essential oil and pure lemon essential oil on food-borne pathogens and fish spoilage bacteria. *International Journal of Food Microbiology* (online), 306: 108-266. Available:<https://pdf.sciencedirectassets.com/271249/1-s2.0-S0168160519X00148/1-s2.0-S0168160519301965/main> (Accessed 15 October 2019).
- Yildizgoren, M. T. and Togrul, A. K. 2014. Preliminary evidence for vitamin D deficiency in nodulocystic acne. *Dermato-Endocrinology* (online), 6(1): 1-5. Available: <https://media.proquest.com/media/hms/PFT/1/iSGg8?cit%3Aauth=Mustafa+Turgut> (Accessed 14 October 2019).
- Youn, S. W. 2016. In vivo model for postinflammatory hyperpigmentation: a step forward. *British Journal of Dermatology* (online), 174(4): 862-868. Available: <https://onlinelibrary.wiley.com/doi/full/10.1111/jdv.12050> (Accessed 29 August 2019).
- Young, A. L., Levy, S., Nighland, M., Grossman, R., Silvers, D. N. and Celebi, J. T. 2009. Are dark skinned people really protected from ultraviolet radiation? *Clinical and Experimental Dermatology* (online), 126(8): 392-396. Available: <http://web.b.ebscohost.com/ehost/pdfviewer/pdfviewer?vid=1&sid=1948bc94-f0fc-4037-8c96-1debeb4a7ba3%40pdc-v-sessmgr06> (Accessed 17 September 2019).
- Zaragoza-Ninet, V., Blasco Encinas, R., Vilata-Corell, J. J., Perez-Ferriols, A., Sierra-Talamantes, C., Esteve-Martinez, A. and de la Cuadra-Oyanguren, J. 2016. Allergic contact dermatitis due to cosmetics: a clinical and epidemiological study in a tertiary hospital. *Actas Dermosifiliograficas* (online), 107(4): 329-336. Available: <https://reader.elsevier.com/reader/sd/pii/S1578219016300087?token> (Accessed 11 July 2019).
- Zawar, V. P., Agarwal, M. and Vasudevan, B. 2015. Treatment of postinflammatory pigmentation due to acne with Q-Switched Neodymium-Doped Yttrium Aluminum Garnet In 78 Indian cases. *Journal of Cutaneous and Aesthetic Surgery* (online), 8(4): 222-226. Available: <https://www.ncbi.nlm.nih.gov/pmc/articles/PMC4728904/?tool=pmcentrez&report=abstract> (Accessed 29 August 2019).

Zeigler-Hill, V. and Noser, A. 2013. Will I ever think I'm think enough? A women's moderated meditation study of women's contingent self-esteem, body image discrepancies and disordered eating. *Psychology of Women Quarterly* (online), 39(1): 109-118. Available: <https://journals.sagepub.com/doi/pdf/10.1177/0361684> (Accessed 11 July 2019).

Zhu, W. and Gao, J. 2008. The use of botanical extracts as topical skin-lightening agents for the improvement of skin pigmentation disorders. *Journal of Investigative Dermatology* (online), 13(1): 20-24. (Accessed 20 April 2015).

APPENDICES

Appendix 1: IREC approval



Institutional Research Ethics Committee
Research and Postgraduate Support Directorate
2nd Floor, Berwyn Court
Gate 1, Steve Biko Campus
Durban University of Technology

P O Box 1334, Durban, South Africa, 4001

Tel: 031 373 2375
Email: lavishad@dut.ac.za
http://www.dut.ac.za/research/institutional_research_ethics

www.dut.ac.za

31 March 2017

IREC Reference Number: **REC 62/16**

Ms R Ganesh
108 Pine Road
Clairwood

Dear Ms Ganesh

The relative effectiveness of Lemon (citrus limon) and Sandalwood (santalum album) essential oils in the treatment of post-inflammatory facial pigmentation in African females 18-35 years in eThekweni


The Institutional Research Ethics Committee acknowledges receipt of your notification regarding the piloting of your data collection tool.

Kindly ensure that participants used for the pilot study are not part of the main study.

In addition, the IREC acknowledges receipt of your gatekeeper permission letters.

Please note that FULL APPROVAL is granted to your research proposal. You may proceed with data collection.

Yours Sincerely,



Professor J K Adam
Chairperson: IREC



Appendix 2: Request for permission to conduct research

108 Pine Road,
Clairwood
Durban
4052

08 February 2017

The Director
Research and Postgraduate Support
Durban University of technology

APPLICATION FOR PERMISSION TO CONDUCT RESEARCH IN THE DEPARTMENT OF SOMATOLOGY, FACULTY OF HEALTH SCIENCES.

Dear Prof Moyo

My name is Ronell Ganesh and I am currently registered for my Master's Degree through the Department of Chiropractic and Somatology: Somatology at the Durban University of Technology.

My research dissertation is titled, "***The effectiveness of Lemon (*Citrus limon*) and Sandalwood (*Santalum album*) essential oils in the treatment of facial post-inflammatory pigmentation in African females aged 18-35 years in EThekweni***".

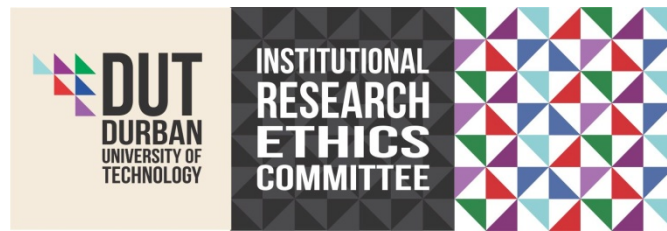The aim of this study is to explore the effectiveness of the two mentioned essential oils in the treatment of pigmentation as well as their overall effect on the skin.

I therefore require permission to invite students to participate in my study should they meet my study's inclusion criteria. Your approval is highly appreciated, if you have any questions or concerns please contact me on 074 514 6116 or my supervisors, Mrs D Borg on (031) 373 2390 or via email on dorindab@dut.ac.za and Prof N Govender on (031) 373 2796 email nalinip@dut.ac.za

Kind regards

Miss Ronell Ganesh
074 514 6116/ (03 2756
ronellg@dut.ac.za

Appendix 3: Letter of Information and Consent – English



LETTER OF INFORMATION AND CONSENT

Title of the Research Study:

The effectiveness of lemon and sandalwood essential oils in the treatment of facial post-inflammatory pigmentation in females aged 18-35 in the EThekweni area

Principal Investigator/s/researcher: Miss Ronell Ganesh

Co-Investigator/s/supervisor/s: Mrs Dorinda Borg - supervisor (Med: Higher Education)
Dr Nalini Govender – co-supervisor

Brief Introduction and Purpose of the Study:

Pigmentation is a common dermatologic condition that is found in all skin types but is most prominent in skin of color. Any inflammation or injury to the skin can almost immediately be accompanied by in pigmentation. The treatment of post inflammatory pigmentation may be challenging as the goal is to reduce the pigmentation without causing additional irritation to the skin. A variety of topical treatments and ointments are available to treat hyperpigmentation, however, these treatments can interfere with the skin at several different levels due to high chemical levels within them. This has caused an increased need by consumers for safe, effective and affordable methods of treating this condition. Therefore the primary purpose of the study is to investigate the effectiveness of the lemon and sandalwood essential oils in the treatment of facial post inflammatory pigmentation in females aged 18-35 years. The secondary purpose of this research will investigate whether these oils improve the overall condition of the skin to the skin.

Outline of the Procedures:

In order to be included in this study, you will need to fulfil the following criteria:

- You must meet with the inclusion criteria of the study
- You must have **POST-INFLAMMATORY PIGMENTATION**. This will be diagnosed by the dermatologist based on images taken and information provided by you

The following criteria will exclude you from participation in this study:

- If you do not meet the inclusion criteria

You will be required to consult with the researcher for a total of five times during the period of the study, on the first consultation, photos will be taken and sent for diagnosing. If diagnosed with the above mentioned condition you will be included in the study. Follow up visits are included during these consultations. A detailed schedule will be handed to you which includes the procedures that will take place during these consultations. Each consultation will take between 20-30 minutes. Consultations will take place at the Somatology Clinic at the Durban University of Technology during operating times.

This is a double-blind placebo controlled study. What does this mean?

In this study, the placebo is a cream that looks similar as the treatment blend but contains no essential oil. Double-blind means that neither the researcher nor the participant knows whether the blend or placebo is allocated to you.

Thus there is a 33% chance that you will receive a blend of cream or the placebo. A total of 75 participants will take part in this study of which 25 participants will receive the lemon blend, 25 participants will receive the sandalwood blend and 25 participants will receive the placebo cream which will be aqueous cream. Participants allocation will be randomly assigned to the 3 groups.

Essential oils, when blended correctly are regarded as safe. However, sometimes, it is possible that you may react to the treatment. To eliminate the chances of this, I will perform a 24 hour allergy test. Please contact the researcher if you are concerned about any symptoms or reactions you may be experiencing further into the study.**Risks or Discomforts to the Participant:**

There will be no risk to you as an allergy test will be conducted prior to you participating in the study. A pilot study will be conducted prior to the study to eliminate any potential risk to you

Benefits:

Benefits to the participant: The blend of cream may improve the appearance of pigmentation on the participant. You will receive a sun block with an SPF 15

Benefits to the researcher: The accolade of a Masters degree in Somatology as well as potential publications in related Journals

Reason/s why the participant may be withdrawn from the study:

You may withdraw at any time from the research study, there will be no consequences for this.

Remuneration:

There is no direct remuneration for participation in the study. Participation in this study is voluntary. Completion of participating in this study will award you with a complimentary treatment at the Somatology clinic

Costs of the study:

There will be no costs for participation in the study

Confidentiality:

All information gathered by you will be kept strictly confidential and the results will be used for academic purposes only. Photos, images and information given by you will be viewed and assessed by a Dermatologist for diagnosis.

Research-related Injury:

To avoid any adverse reactions an allergy test will be conducted prior to you being included in the study

If you have any questions or enquiries related to the study, please contact the following personnel:

Principle Investigator: Ronell Ganesh

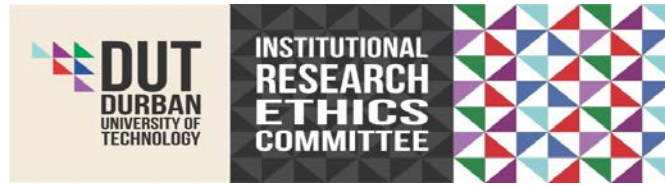Cell: 074 514 6116

Supervisor: Mrs Dorinda Borg

Tel: (031) 373 2390

Or the Institutional Research Ethics Administrator on (031) 373 2900. Complaints can be reported to the DVC: TIP, Prof F Otieno on (031) 373 2382 or dvctip@dut.ac.za

Appendix 4: Letter of Information and Consent – isiZulu



INCWADI YOLWAZI NEMVUME

Isihloko Socwangingo:

Ukusebenza kukalamula kanye namafutha emvelo e-sandalwood ekwelapheni ubuso obukade buvukela ebantwini besifazane abaphakathi kweminyaka eyi 18-35 endaweni yaseThekwini.

Um/abancwangingi : Nksz Ronell Ganesh

O/abasebenzisana nomcwangingi: Nkskz Dorinda Borg - supervisor (Med: Higher Education)
Dkt Nalini Govender – co-supervisor

Isingeniso esifushane kanye nenhloso yocwangingo

Ukushintsha kwebala lesikhumba isimo esejwayelekile esitholakala kuzozonke izinhlobo zesikhumba. Nomangabe ikuphi ukuvuvukala noma ukulimala okusesikhunjani kungalandelwa ukushintsha kwebala lesikhumba. Ukwelashwa kobekade evuvukalelwe isikhumba kungaba inselelo njengoba inhloso kungukwehlisa izinga lokushintsha kwebala lesikhumba ngale kokudala ezinye izinkinga zesikhumba. Kukhona izinhlobonhlobo zokwelashwa kwesimanjemanje kanye nokokugcoba ukwelapha ukushintsha kwebala lesikhumba, kodwa ke, lokhu kwelashwa kungaphazamisa isikhumba emazingeni ahlukahlukene ngenxa yamazinga amakhemikhali aphezulu. Ngakho ke inhloso ngqangi yocwangingo ukuphenya ngokusebenza kukalamula kanye namafutha emvelo e-sandalwood ekwelapheni ubuso obebuvukela futhi obushintshe ibala lesikhumba kwabesifazane abaneminyaka ephakathi kweyi 18-35. Enye inhloso yocwangingo ukuphenya ukuthi lamafutha asenza sibengcono yini isikhumba.

Uhlaka lwenqubo:

Ukuze ube ingxenye yalolu cwangingo, uzodinga lokhu okulandelayo:

- Kumele uhlangabezane nezidingo zocwangingo
- Kuzomele kube ukuthi **WAKE WABA NOBUSO OBUVUVUKELE**. Lokhu kuzovezwa udokotela wesikhumba ngezithombe ezathathwa kanye nasemininingwaneni ezobe ikhishwe uwe.

Lokhu okulandelayo kuzokwenza ukuthi ungabandakanywa kulolu cwangingo:

- Uma ungahlangabezani nezidingo zocwangingo

Uzocelwa ukuthi ubonane nomcwangingi izikhathi eziyisihlanu ngesikhathi socwangingo, uma nibonana okokuqala, kuzothathwa izithombe ezizobe sezihanjiswa ukuba ziyohlolwa. Uma zihlolwe kwatholakala ukuthi unalesimo esibalulwe ngenhla okuyobe sekusho ukuthi uzoba ingxenye yocwangingo. Ukuphinde ubonwe kubandakanywe kulezikhathi ezibaluliwe. Uzonikwa uhlelo oluchwazwe ngokuphelele ngenqubo ezolandelwa ngakho konke okuzobe kwenziwa uma nihlalanga. Konke ukuhlalanga kuzokwenzeka phakathi kwemizuzu eyi 20-30. Ukuhlalanga kuzokwenzeka eMtholampilo we-Somatology e-Durban University of Technology ngezikhathi zomsebenzi.

Lolu cwaningo lulawulwa i-double-blind placebo. Lokhu kusho ukuthini?

Kulolu cwaningo i-placebo ukhilimu ocishe ufane ne-treatment blend kodwa wona awunawo amafutha emvelo. Ukuthi double-blind kusho ukuthi kungenzeka ukuthi umcwaningi noma umbambiqhaza akazi ukuthi unayo yini i-blend noma i-placebo. Okusho ukuthi kunamathuba angama 33% okuthi uzothola ukhilimu we-blend noma we-placebo. Abantu abangama -75 abazobamba iqhaza kulolu cwaningo okungukuthi abangama-25 babo bazothola i-blend kalamula, abangama- 25 bazothola i-sandalwood bese kuthi abangama- 25 bathole ukhilimu we-placebo okuzobe kuyi-aqueous cream. Ukuhlukaniswa kwababambe iqhaza kulamaqoqo amathathu kuzobe kuxubile.

Amafutha emvelo, uma ethakwe kahle ayaye athathwe njengalawo angenabungozi. Kodwa ke, ngesinye isikhathi, kuyenzeka ukuthi ungazwani nokhilimu. Ukuze ngigweme lokhu, ngizokwenza I-allegly test yamahora angama -24. Sicela uthinte umcwaningi uma unokukhathazeka nganoma iziphi izimpawu ongazibona ngesikhathi kusaqhubka ucwaningo.

Ubungozi Kobambe Iqhaza

Akuzubakhona bungozi kuwe njengoba I-allegly test izokwenziwa ngaphambi kokuba ubambe iqhaza kulolu cwaningo. I-pilot study izokwenziwa ngaphambi kokuqala ucwaningo ukuze sigweme nanoma ibuphi ubungozi.

Izinzuzo:

Izinzuzo kobambe iqhaza: ukuxutshwa kokhilimu kungenza ngcono ukubukeka kwesikhumba ebesinebala elishintshile kobambe iqhaza. Uzothola okokuvikela ilanga okune-SPF 15
Inzuzo yomcwaningi: ukwethweswa kweziqu ze-Masters ezifundweni ze-Somatology kanye nokushicilelwa kocwaningo.

Isi/izizathu zo/sokuhoxa kobambe iqhaza ocwaningweni:

Ungakwazi ukuhoxa nanoma ingasiphi isikhathi kulolu cwaningo, akuzubakhona nhlawulo.

Ukukhokhelwa:

Akukho nokhelo eqondene ngqo nobambe iqhaza kulolu cwaningo. Uyazinikela ekubambeni iqhaza kulolu cwaningo. Ukubamba iqhaza luze luyophela ucwaningo kuzokwenza ukuthi uhlonyuliswe ngokwelashwa mahhala emtholampilo we-Somatology.

Imali yocwaningo:

Akuzukuba khona mali ekhokwayo ukuze ubambe iqhaza kulolu cwaningo

Imfihlo:

Yonke imininingwane eqoqwe uwe izogcinwa iyimfihlo ebese imiphumela isetshenziselwa ukufunda kuphela. Izithombe kanye nemininingwane oyikhiphile izohlolwa udokotela wesikhumba ukuze athole inkinga yesikhumba sakho.

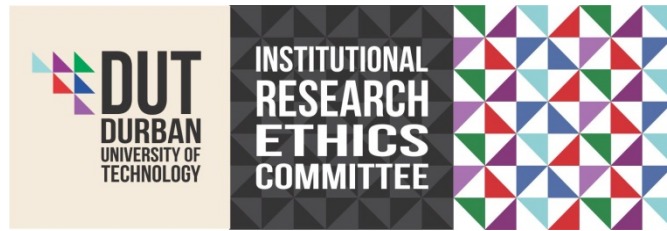Ukulimala okuhlobene nocwaningo

Ukuze ugweme ukulimala kwesikhumba sakho kulolu cwaningo, kuzokwenziwa I-allegly test ngaphambi kokuba ube ingxenye yocwaningo.

Uma unanoma imiphi imibuzo emayelana nocwaningo, sicela uthinte laba abalandelayo
Umcwaningi: Ronell Ganesh Umakhalekhukhwini: 074 514 6116
Olekelela umcwaningi: Nksz Dorinda Borg Ucingo: (031) 373 2390

Noma i- Institutional Research Ethics Administrator on (031) 373 2900. Ungathumela izikhalazo ku- DVC: TIP, Solwazi F Otieno on (031) 373 2382 or dvctip@dut.ac.za

Appendix 5: Consent form – English



CONSENT

Statement of Agreement to Participate in the Research Study:

- I hereby confirm that I have been informed by the researcher, Ronell Ganesh, about the nature, conduct, benefits and risks of this study - Research Ethics Clearance Number: _____,
- I have also received, read and understood the above written information (Participant Letter of Information) regarding the study.
- I am aware that the results of the study, including personal details regarding my sex, age, date of birth, initials and diagnosis will be anonymously processed into a study report.
- In view of the requirements of research, I agree that the data collected during this study can be processed in a computerised system by the researcher.
- I may, at any stage, without prejudice, withdraw my consent and participation in the study.
- I have had sufficient opportunity to ask questions and (of my own free will) declare myself prepared to participate in the study.
- I understand that significant new findings developed during the course of this research which may relate to my participation will be made available to me.

**Full Name of Participant
Thumbprint**

Date

Time

Signature / Right

I, Ronell Ganesh, herewith confirm that the above participant has been fully informed about the nature, conduct and risks of the above study.

Full Name of Researcher

Date

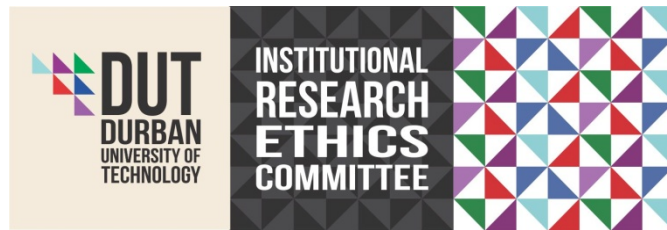Signature

Full Name of Witness (If applicable)

Date

Signature

Appendix 6: Consent form – isiZulu



IMVUME

Isitatimende sokuvuma ukuba ingxenye yocwangingo:

- Ngiyavuma ukuthi umcwangingi u- Ronell Ganesh ungazisile ngobunjalo bocwangingo, ukuziphatha, umhlomulo kanye nobungozi balolu cwangingo- iNombolo ye-Research Clearance: _____,
- Nginikiwe, ngafunda futhi ngaqondisa imininingwane ebhalwe ngenhla (Incwadi Yemininingwane yoMbambiqhaza) mayelana nocwangingo.
- Ngiyazi ukuthi imiphumela yocwangingo, okuhlanganisa imininingwane yami emayelani nobulili, iminyaka, usuku lokuzalwa, izinhlamvu zokuqala zamagama kanye nokubonwa kwezifo ezikumina kuzofakwa embikweni wocwangingo ngokungavezwa kwegama lami.
- Ngenxa yalokhu okudingwa ucwangingo, ngiyavuma ukuthi lemininingwane etholwe kulolu cwangingo ingasetshenziswa ifakwe kwimpyutha.
- Ngingakwazi ukuhoxa ekubambeni iqhaza kulolu cwangingo nanoma inini.
- Ngibe nethuba elanele lokubuza futhi (ngokuzithandela kwami) ngizivumele ukuthi ngikulungele ukubamba iqhaza kulolu cwangingo.
- Ngijaqondisa ukuthi konke okusha okuvelayo kulolu cwangingo okuqondene name ngingakwazi ukukuthola.

**Igama eliphelele lombambiqhaza
Isithupha sokunene**

Usuku

Isikhathi

Isiginisha

Mina, Ronell Ganesh, ngiyaqinisekisa ukuthi obambe iqhaza ongenhla waziswe ngokugcwele ngokohlobo, ukuziphatha nobungozi bocwangingo olungenhla.

Igama eliphelele lomcwangingi

Usuku

Isiginisha

Igama eliphelele lofakazi (uma kunesidingo) Usuku

Isiginisha



DO YOU HAVE FACIAL DISCOLOURATION OR UNEVEN SKIN TONE?

Have you had any recent change to your complexion and skin tone due to any scarring or blemishes? Is this affecting your self-esteem and confidence?

FACIAL TREATMENT

Is now available for females between 18-35 years that meet the study criteria

For more information please contact:

Ronell Ganesh –	Cell:	074 514 6116
	WhatsApp:	076 7000 611
	Email:	ronellg@dut.ac.za



NGABE UBUSO BAKHO
BUGQHUNQILE NOMA IBALA
LESIKHUMBA SAKHO ALIFANI?

Usuke waba nokushintsha kwebala
lesikhumba ngenxa yokulimala noma izisihla?
Ngabe lokhu kunomthelela ekuzethembeni
kwakho?

UKWELASHWA KOBUSO

Sekuyatholakala kubantu besifazane
abaphakathi kweminyaka eyi 18-35
abahlangabezana nezidingo zocwaningo

Ngeminye imininingwane sicela uxhumane no:

Ronell Ganesh –

Umakhalekhukhwini:

0745146116

u-WhatsApp:

076 7000 611

i-Email:

ronellg@dut.ac.za

Appendix 9: Questionnaire – English



QUESTIONNAIRE

Thank you once again for agreeing to complete this questionnaire. Please read through the questions below and answer to the best of your ability. Any information you provide will be kept strictly confidential.

1. GENERAL INFORMATION (please tick where applicable)

Participant no:					
Occupation:					
Age:	18-22 years	22-24 years	24-28 years	28-32 years	32-35 years
Race (for statistical purposes):	African	Coloured	Indian	White	Other (specify)

2. LIFESTYLE/ GENERAL HEALTH INFORMATION (please tick most applicable option)

2.1 How is your general health	Excellent		Good	Fair	Poor
2.2 Do you exercise? If yes, how often?	Yes	No	1-2 times a week	2-4 times a week	Everyday
2.3 Do you smoke cigarettes? If yes, how many do you smoke per day?	Yes	No	1-5 per day	5-8 per day	8 or more per day

2.4 Do you drink alcohol? If yes, how often?	Yes	No	1-2 times a week	More than 4 times a week	Everyday
2.5 Do you eat fruit and vegetables? If yes, how often?	Yes	No	1-3 per day	3-5 per day	5 or more per day
2.6 How much water do you drink?	Yes	No	1-3 glasses per day	3-6 glasses per day	6 or more glasses per day
2.7 Have you been diagnosed with any health related conditions?	Yes	No	If Yes, please specify:		

3. SKIN INFORMATION

3.1 Are you currently using any skin care products? If yes, please indicate the brand/make of the range and the reason for use of each product?

3.2 Does anything bother you regarding the condition of your skin. If yes, please specify

3.3 Have you either had or regularly go for any of the following skin care treatments (please tick)

Procedure/Treatment	Yes	No	If Yes, please specify how often
3.3.1 Waxing			

3.3.2 Threading			
3.3.3 Permanent hair removal			
3.3.4 Laser			
3.3.5 Peels			
3.3.6 Deep cleanse facials			
3.3.7 Advanced/specialized facials			
3.3.8 Bleaching			

3.3.9 Lightening/whitening treatments			
---------------------------------------	--	--	--

4.1 Please tick if you have previously used any of the following skin medications/preparations for pigmentation or uneven skin tone.

Medication/Preparation			If yes, how long you have been using the selected medication/preparation (Please tick)					
			0-3 months ago	0-6 months ago	6-9 months ago	9-12 months ago	12-18 months ago	More than 18 months
4.1.1 Roaccutane™	Yes	No						
4.1.2 Oratane®	Yes	No						
4.1.3 Retin A®	Yes	No						
4.1.4 Cortisone	Yes	No						
4.1.5 Antibiotics	Yes	No						
4.1.6 Vitamin supplements	Yes	No						
4.1.7 Thyroid	Yes	No						
4.1.8 Retinoids	Yes	No						
4.1.9 Hydroquinone	Yes	No						
4.1.10 Azelaic acid	Yes	No						
4.1.11 Other, please specify:								

*If none of the above is applicable to you, please proceed to question 5

5. GENERAL QUESTIONS

5.1 When did you first notice the appearance of this uneven skin tone?

5.2 Have you been exposed to any trauma or condition that may have resulted in this uneven tone?

5.2.1 If No, do you know what could be the cause of your uneven skin tone/pigmentation?

5.3 Does any member/s of your family have facial pigmentation?

5.4 Have you been treating your pigmentation? If yes, how?

5.5 If yes, do you think the pigmentation has worsened or improved over time? Please explain

Thank You

Appendix 10: Questionnaire – isiZulu



INHLOLOVO

Siyabonga kakhulu ngokuvuma ukugcwalisa le nhlobo. Sicela ufunde lemibuzo elandelayo ebese uyiphendula ngokusemandleni akho. Noma ngabe imiphi imininingwane ozoyiveza izoba imfihlo.

1. IMININGAWANE EJWAYELEKILE (sicela ufake lolu phawu (v) kokukhethayo)

Inombolo yobambe iqhaza:					
Uhlobo lomsebenzi:					
Iminyaka	18-22	22-24	24-28	28-32	32-35
	Weminyaka	Weminyaka	Weminyaka	Weminyaka	Weminyaka
Ubuhlanga (ngenhloso yezibalo)	umAfrika	Ikhaladi	owase Ndiya	Umlungu	Okunye (chaza)

2. INDLELA YOKUPHILA/ ULWAZI MGEZEMPILO (sicela ufake lolu phawu (v) kokukhethayo)

2.1 Injani impilo yakho?	Inhle kankhulu		Inhle	Kuyancengeka	Kuyabheda
2.2 Ngabe uyazivocavoca? Uma uthi yebo, kuba kangaki?	Yebo	Cha	1-2 ngeviki	2-4 ngeviki	Nsukuzonke

2.3 Ngabe uyawubhema ugwayi? Uma uthi yebo, ubhema ogwayi abangaki ngosuku?	Yebo	Cha	1-5 ngosuku	5-8 ngosuku	8 noma ngaphezulu ngosuku
2.4 Ngabe uyabuphuza utshwala? Uma uthi yebo, kuba kangaki?	Yes	Cha	1-2 ngeviki	Ngaphezu kokune ngeviki	Nsukuzonke
2.5 Uyazidla izithelo nezaqathi? Uma uthi yebo, kuba kangaki?	Yebo	Cha	1-3 ngosuku	3-5 ngosuku	5 noma ngaphezulu ngosuku
2.6 Mangakanani amanzi owaphuzayo?	Yebo	Cha	Ingilazi e-1-3 ngosuku	Izingilazi ezi-3-6 ngosuku	Izingilazi ezi-6 noma ngaphezulu ngosuku
2.7 Ngabe zikhona izimo zezempilo esezike zahlonzwa kuwe?	Yebo	Cha	Uma uthi yebo, sicela uchaze:		

3. ULWAZI NGESIKHUMBA

3.1 Ngabe bakhona okhilimu besikhumba obasebenzisazo? Uma uthi yebo, sicela usikhanyisele ngegama/ngohlobo lokhilimu nesizathu sokusebenzisa ukhilimu ngamunye?

3.2 Ngabe kukhona okukukhathazayo ngesimo sesikhumba sakho. Uma uthi yebo, sicela uchaze

3.3 Usume noma ujwayele ukusebenzisa okokunakekela isikhumba kulokhu okulandelayo (sicela ufake lolu phawu √)

Inqubo/ukwelashwa	Yebo	Cha	Uma uthi yebo, sicela uchaze ukuthi kuba kangaki
3.3.1 Ukususa iziboya			
3.3.2 Ukuncothulwa kwezinwele/iziboya ezingadingeki			
3.3.3 Ukususa izinwele unomphelo			
3.3.4 i-Laser			
3.3.5 Peels			
3.3.6 Imikhiqizo ekhethekile yokugeza ubuso			
3.3.7 Imikhiqizo ephambili esetshenziswa ebusweni			

3.3.8 Ukwenza ubuso bube nebala elimpofu			
3.3.9 Imikhiqizo eyenza isikhumba sikhanye ngebala			

4.1 Sicela ufake lolu phawu (√) uma usuke wasebenzisa eminye yemithi yebala lesikhumba noma yebala elingafani

Imithi/Ukulungiselela			Uma uthi yebo, usukusebenzise isikhathi esingakanani lokhu okukhethile (sicela ufake u-√)					Ngaphe zu kwezinyanga ezi-18
			izinyan ga ezi-0-3 ezedlule	izinyan ga ezi-0-6 ezedlule	izinyan ga ezi-6-9 ezedlule	izinyan ga ezi-9-12 ezedlule	izinyan ga ezi-12-18 ezedlule	
4.1.1 i- Roaccutane™	Yebo	Cha						
4.1.2 i-Oratane®	Yebo	Cha						
4.1.3 i-Retin®	Yebo	Cha						
4.1.4 i-Cortisone	Yebo	Cha						
4.1.5 Ama-Antibiotics	Yebo	Cha						

4.1.6	Amaphilisi amavithamini	Yebo	Cha						
4.1.7	i-Thyroid	Yebo	Cha						
4.1.8	Ama-Retinoids	Yebo	Cha						
4.1.9	i-Hydroquinone	Yebo	Cha						
4.1.10	i-Azelaic Acid	Yebo	Cha						
4.1.11 Okunye, sicela uchaze:									

*Uma kungekho okuqonqene nawe ngenhla, sicela uqhubekele esigabeni sesi-5 semibuzo

5. IMIBUZO EJWAYELEKILE

5.1 Uqale nini ukuqaphela ukubona ukungafani kwesikhumba?

5.2 Uke waba sesimeni sokuhlukomezeka noma isimo okungenzeka sibe nomphumela ekubeni nesikhumba esingafani?

5.2.1 Uma uthi cha, ngabe uyazi ukuthi senziwa yini isikhumba ukuthi sibe nombala ongafani?

5.3 Ngabe likhona ilunga noma amalunga omndeni wakho anenkinga yebala lobuso?

5.4 Ngabe usuke walapha inkinga yebala lesikhumba sakho? Uma uthi yebo, waselapha kanjani?

5.5 Uma uthi yebo, ucabanga ukuthi inkinga yebala isidlebelekile noma ibe ngcono ngokuhamba kwesikhathi? Sicela uchaze.

Ngiyabonga

Appendix 11: Agreement letter Prof. Mosam

Appendix 11



To: Whom it may concern
From: Professor A. Mosam (please add your achievements)
Date: 29 May 2015
RE: Diagnosis of participants for research study titled "The effectiveness of Lemon and Sandalwood essential oils in the treatment of facial post-inflammatory pigmentation in females aged 18-35 in the EThekweni area"

This serves to confirm that I, Professor A Mosam, have agreed to diagnose participants for facial post-inflammatory pigmentation in females for the above mentioned study. Diagnosis for this condition will be made according to the following information provided to me by the researcher (Miss R Ganesh):

- Photos (3 angles) that will be taken by the researcher according to requirements I have provided
- A case history form

A diagnosis will then be given according to the above.

I have also requested that photos be forwarded to me at 12 and 24 weeks for monitoring.

Please feel free to contact me should you require additional information

Yours sincerely

Prof A Mosam
MB ChB, FC Derm(SA), MMed(Derm), PhD(UKZN)
Associate Professor/Principal Specialist

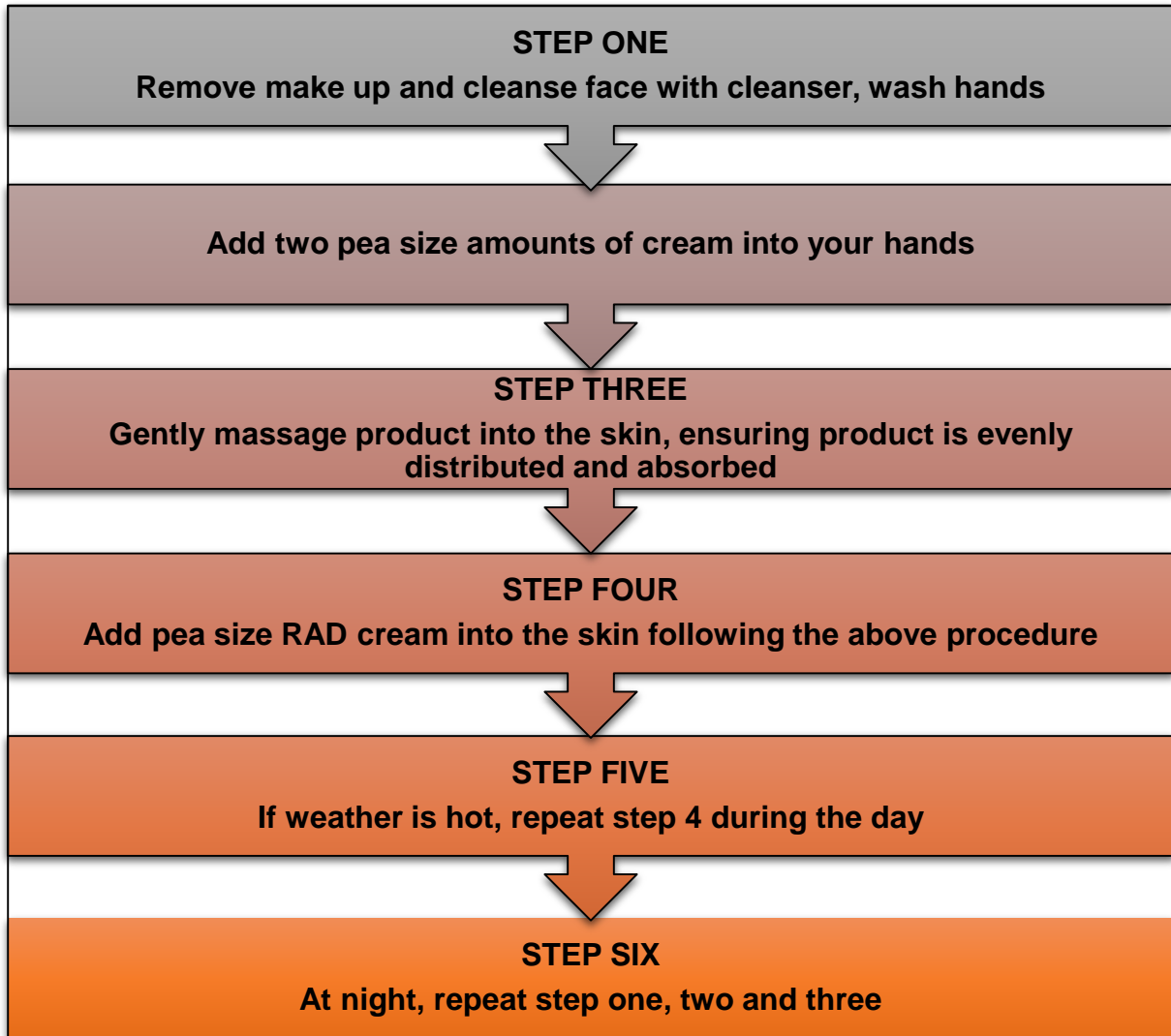Office of the Head of Department
Dermatology, School of Clinical Medicine
Postal Address: P/Bag X3, Congella, Durban, 4013, South Africa
Telephone: +27 (0) 31 260 4531/4565 Facsimile: +27 (0) 31 260 4434 Email: mosama@ukzn.ac.za Website: www.ukzn.ac.za

1910 - 2010
100 YEARS OF ACADEMIC EXCELLENCE

Founding Campuses: ■ Edgewood ■ Howard College ■ Medical School ■ Pietermaritzburg ■ Weehills

Appendix 12: Basic treatment usage instructions

BASIC INSTRUCTION ON TREATMENT USAGE



Appendix 13: Process of consultations

When participants respond to the advert, the following processes will take place:

1 ST CONSULTATION DAY ONE	2 ND CONSULTATION DAY TWO	3 RD CONSULTATION EIGHT WEEKS	4 TH CONSULTATION SIXTEEN WEEKS	5 TH CONSULTATION TWENTY-FOUR WEEKS (FINAL)
<p>The study will be briefly explained to the participant. If the participant wishes to pursue her participation, a questionnaire together with photographs will then be taken and sent to the dermatologist for clinical diagnosis 24 hour allergy test with the different blends of cream and sunblock will be conducted.</p>	<p>If the participant presents with no signs of an allergic reaction, she may be included in the study. If the participant shows signs of an allergic reaction, the area will be washed with cool, clean water and calamine lotion will be applied. The participant will then be referred to the DUT Isilempilo clinic for further medical attention. Following this, the information letter and informed consent will be completed. Thereafter the selected creams and sun protection will be randomly allocated to the participant. Basic instructions on how to use the cream and sun protection will be explained to the participant. images will be taken by the skin analyser</p>	<p>Participants skin will be cleansed. Images will be taken by the machine as well as follow up photos. The participant will be able to discuss any questions or enquiries with the researcher</p>	<p>Participants skin will be cleansed. Images will be taken by the machine as well as follow up photos. The participants will be able to discuss any questions or enquiries with the researcher</p>	<p>Images will be taken by the machine as well as final photos. The participant will need to complete a short questionnaire on the progress of their skin. Photos taken will be sent to the Dermatologist for final assessment and conclusions. A manual assessment sheet will also be completed by the researcher. The participant will qualify for a free treatment at the Somatology clinic, Durban University of Technology, for participating in the study.</p>

Appendix 14: Manuscript

Manuscript in preparation

Target Journal: Indian Journal of Dermatology, Venerology and Leprology

Title: The effectiveness of lemon and sandalwood essential oil in the treatment of post inflammatory pigmentation in females aged 18-35 years

Ronell Ganesh¹, Dorinda Borg¹, Anisa Mosam², Glenda Matthews³, Nalini Govender⁴

¹Dept of Somatology, Faculty of Health Sciences, Durban University of Technology, Durban, South Africa

²Dept of Dermatology, School of Clinical Medicine, Durban, South Africa

³Dept of Statistics, Faculty of Health Sciences, Durban University of Technology, Durban, South Africa

⁴Dept of Basic Medical Sciences, Faculty of Health Sciences, Durban University of Technology, Durban, South Africa

Keywords: Post inflammatory pigmentation, acne, essential oils, natural remedies

Corresponding author

Mrs Ronell Ganesh

ronellg@dut.ac.za

Word count:

Abstract

Background: Post inflammatory pigmentation (PIH) is a common dermatologic disorder prominent in darker skinned woman of childbearing age. It affects both the physical and physiological features of those affected, thereby altering their quality of life. The high costs and safety of treatment options available for PIH are questionable, thus creating an interest in the effects of natural remedies on PIH.

Objectives: To evaluate the effects of lemon and sandalwood essential oils on PIH in African females aged 18-35 years. It determined the progression of PIH using sandalwood and lemon essential oil using a Skin Analyser® machine. Comparisons were made between both oils to determine their effectiveness in PIH treatment.

Methods: This was a prospective, quantitative and double-blinded study with an experimental design, conducted at the Durban University of Technology. Black female students, 1aged 8-35 years, were randomly assigned to experimental and control groups. A pre-test post-test method was used and included follow up consultations at 0 weeks, 8, 16 and 24 weeks.

Results: Most participants were aged between 18-22 years, with 61.7% reporting the use of daily homecare treatments (cleansers and moisturisers). Fifty four (54%) reported a family history of pigmentation, and 52% reported acne concerns associated with low self-esteem. Waxing was identified as the preferred hair removal method. Physical skin improvements in facial spots, pore sizes, UV features, were noted for both oils. However, a statistically significant difference was demonstrated for sandalwood oil.

Conclusion: Our data highlights waxing as the preferred hair removal method. Waxing predisposes women to inflammation, blockage of pores and burns, and subsequent PIH development. The increased incidence of pigmentation may be associated with the higher usage of waxing. Overall, visible improvements were demonstrated in the skin for both oils. We observed significant physiological changes in the pore sizes for both oils, and improved pore conditions with fewer enlarged and blocked pores. Thus, both groups showed a reduction in the prevalence of acne. Our data thus suggests that both oils may have a potential role in decreasing the development of acne and PIH

Introduction

There has been a global regeneration in cosmeceutical markets for improved facial aesthetic appearance (Sharma and Sharma 2012). Whilst the biosafety of cosmetics were significantly acceptable in the early 1950s, concerns arose when skin lightening products showed links to harsh reactions (Nohynek et al. 2010). These concerns peaked when harmful side effects of various skin lightening chemicals in products such as arbutin, kojic acid and hydroquinone were reported (Zhu and Gao 2008; Huang et al. 2012). Such harmful effects include irritation, inflammation, thinning of skin, scarring, kidney, liver, or nerve damage (Shroff, Diedrichs and Craddock 2018), subsequently increasing access to natural products. Pigmentary disorders rank amongst the five common complaints amongst blacks, arabs and south Asians (Konda, Geria and Halder 2012). This has led to an increased usage of skin creams with bleaching properties amongst many black South African women (Dlova, Hendricks and Martincgh 2012). Those affected pursue treatment regimens that improve the appearance of pigmentation and overall skin tone (Swanson, Leo and Finlay 2014), predisposing them to poor self-confidence (Jiang et al. 2018). This subsequently affects their quality of life (Yadav 2018), which substantiates the exploration of natural cosmetics (Walters and Roberts 2008). Based on this premise, this study aimed to determine the effectiveness of lemon and sandalwood essential oils on post inflammatory pigmentation in African females.

Methods

This was a prospective, quantitative and double-blinded study with an experimental design. Participants were randomly assigned to experimental and control groups by the supervisor. The study was conducted at the Somatology clinic, Durban University of Technology, South Africa. A pre-test, post-test method was used. Participants were included or excluded from the study based on the following criteria.

Study Sampling and recruitment

The study population included African females aged between 18-35 years who met the inclusion criteria. Purposive sampling was used to identify and recruit participants. The sample size as determined by consultation with the biostatistician was forty five participants (n=45); Deepak 2014).

Recruitment was supported by the placement of advertisements [Appendix 7 (English); Appendix 8 (IsiZulu)] in both the Ritson and Steve Biko campuses, DUT as well as Durban and surrounding areas.

Participants who received confirmation of a clinical diagnosis from the consultant dermatologist, were then given a 24 hour allergy test. The test was done by the researcher and was used to determine the presence or absence of any allergies that participants may have to the selected blends of cream or the sunblock (SPF 15). The allergy test was done by the researcher on the inner elbow of all participants. Prior to the allergy test, the inner below was cleaned with hibitane and cotton wool, followed by the application of each blend of cream (lemon with aqueous), (sandalwood with aqueous) and the sunblock. The participants were asked to return after \pm 24 hours for an allergy assessment. None of the participants reacted negatively to the allergy testing. The experimental product was a fragrance and preservative free aqueous based cream. One hundred millilitre (100ml) cream was given to the participants, either independently (control) or combined with 50 drops lemon oil or sandalwood oil (experimental) which were 100% aromatherapy based oil. Following clinical diagnosis and allergy testing the participants were randomly allocated into group 1 (lemon), group 2 (sandalwood), group 3 (control).

Data analysis

Demographic data obtained from the questionnaire and clinical data obtained from the skin analyser[®] machine were analysed. This data was collected, coded and captured onto a spreadsheet using statistical analysis SPSS (Version 25.0). A p-value < 0.05 was considered a statistically significant result. Data was tested for normality and continuous data was summarised in terms of the mean, standard deviation, minimum and maximum. One-way analysis of variance (ANOVA) and sample t-test were completed on skin parameters. Findings from the study were triangulated. Data from the questionnaire and Skin Analyser[®] (LD6021) were analysed. The study was analysed using descriptive data obtained from the questionnaire, focusing on lifestyle and skincare data. Comparisons between the parameters and descriptive were presented. Open ended questions from the questionnaire was analysed for the triangulation of data. Changes in the parameters over time were presented graphically and repeated measures ANOVA was used to detect whether there was a significant change over time and if there were treatment differences.

Results

Demographic characteristics

The demographic profile of the study population is shown in Table 1. Of the 62 Black African females recruited, 61 were students, 87.1% were aged between 18-22 years, whilst 12.9% were aged 23-27 years. With regard to lifestyle characteristics, 75% reported the use of healthy diets and 38% reported the recommended daily water intake. Only 4 participants reported smoking and alcohol consumption. Based on these low numbers, this data was excluded from further analyses. Only 33.9% of the total sample reported waxing as an option of hair removal whilst 19.6% reported threading as a preference. Furthermore, 42.9% reported the regular use of deep cleanse facials, and 61.7% indicated the use of daily homecare treatments. In contrast, 17% reported the use of some form of pigmentation treatment, whilst 54.3% reported a family history of pigmentation. Of note, only 48 participants completed the follow-up consultations.

Photographic evidence

Physical changes of the skin were observed between treatment groups as shown in Figures 4.1-4.3 (a-f). An overall improvement was observed in skin pore sizes, texture as well as an overall reduction in PIH facial features amongst those who used the lemon oil (Figure 4.1) and sandalwood oil treatment (Figure 4.2). Improvements in skin pore sizes and texture was also observed amongst those who were in the control group (Figure 4.3). This could be attributed to the presence of SPF. Our data highlights a visible reduction in the appearance of skin pigmentation and acne in both experimental groups.

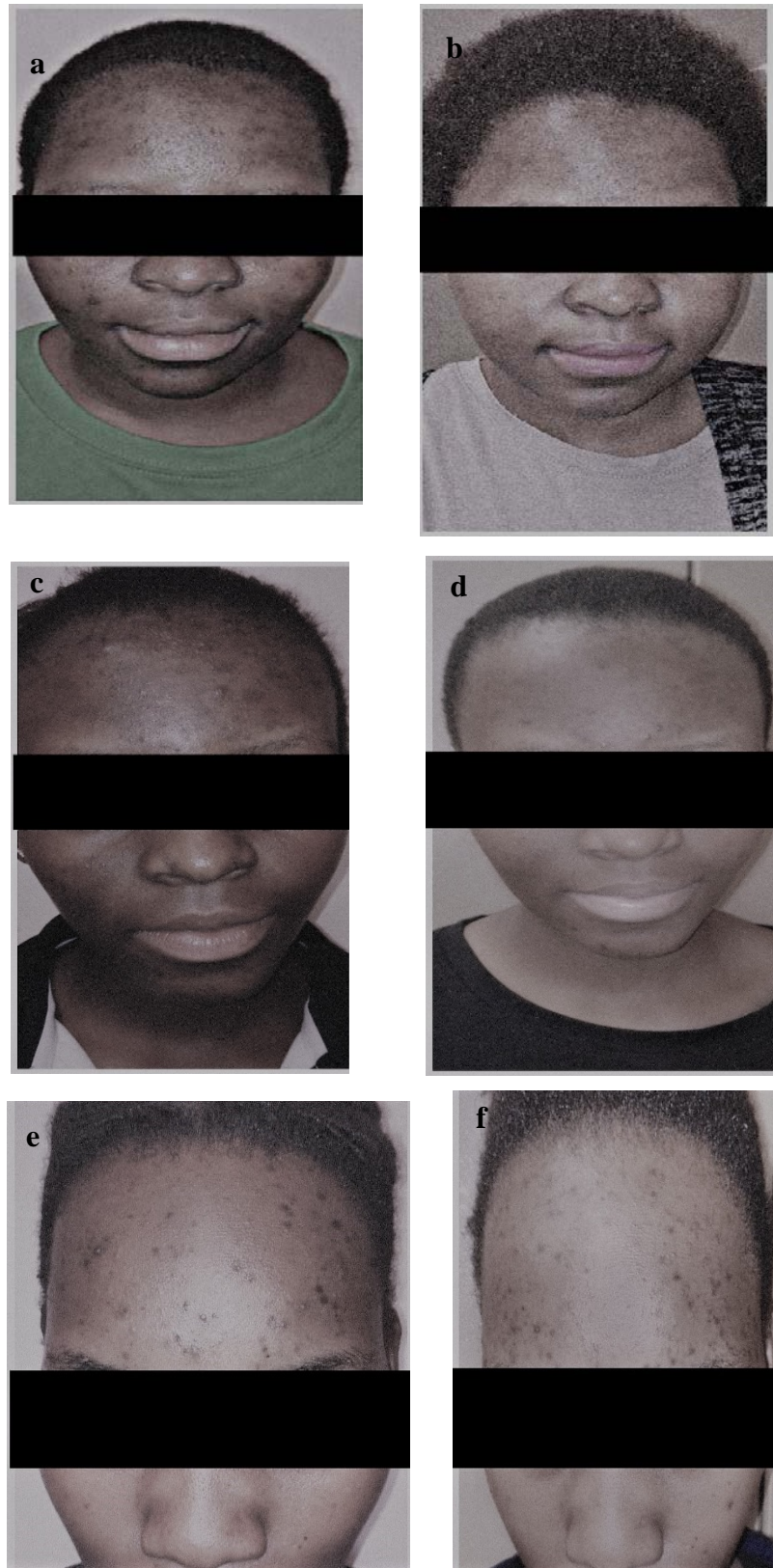

Figure 0.1: Physical changes in facial appearance for lemon oil at (a) baseline (0 weeks), (b) (24 weeks); for sandalwood oil at (c) baseline (0 weeks), (d) 24 weeks; and control with aqueous cream and SPF(e-f)

Descriptive analyses of the skin parameters

T-tests were used to provide before and after comparisons for the lemon and sandalwood study groups between 0 weeks (baseline) to 24 weeks (post treatment). The mean and standard deviation for lemon (Table 4.2) and sandalwood oil (Table 4.3) are displayed. Significant improvements was observed for facial spots amongst those who used the lemon treatment ($p = 0.05$) and sandalwood oil ($p = 0.05$). Similarly pore sizes were also significantly reduced in lemon oil ($p = 0.02$) and sandalwood oil ($p = 0.01$) in contrast to the control (Table 4.2 - 4.3). Statistically significant differences were noted on the UV spots ($p = 0.05$), facial wrinkles ($p = 0.01$), indicating a reduced appearance of wrinkles in those on lemon oil.

Table 0.1: Evaluation of skin parameters at baseline (0 weeks) and post treatment (24 weeks) amongst those using the lemon treatment (n = 15)

Parameter	Baseline mean \pm -SD (0 weeks)	Control (aqueous cream and SPF) mean \pm SD (0 weeks)	Control (aqueous cream and SPF) mean \pm SD (24 weeks)	Lemon essential oil mean \pm -SD (24 weeks)	<i>p</i> - value
Facial spot	68.67 \pm 21.24	64.60 \pm 20.85	58.67 \pm 22.68	59.06 \pm 20.61	0.047*
Pore size	70.94 \pm 17.12	73.60 \pm 15.88	68.80 \pm 18.17	62.56 \pm 19.87	0.021*
Skin roughness	87.17 \pm 19.44	84.47 \pm 25.70	87.20 \pm 15.85	87.94 \pm 17.04	0.772
Facial wrinkles	80.44 \pm 17.78	72.27 \pm 20.05	66.87 \pm 20.61	70.33 \pm 21.69	0.005*
UV acne	16.44 \pm 14.91	16.87 \pm 14.98	23.53 \pm 23.67	17.50 \pm 20.92	0.783
UV facial spot	81.72 \pm 23.20	88.73 \pm 15.32	83.33 \pm 18.48	76.28 \pm 25.45	0.345
UV moisture lev	93.61 \pm 7.95	95.53 \pm 0.743	91.93 \pm 10.07	93.22 \pm 7.04	0.816

* $p < 0.05$ was considered statistically significant

Table 0.2: Evaluation of skin parameters at baseline (0 weeks) and post treatment (24 weeks) amongst those using the sandalwood treatment (n = 15)

Parameter	Baseline mean \pm SD (0 weeks)	Control mean \pm SD (aqueous cream and SPF) (0 weeks)	Control mean \pm SD (aqueous cream and SPF) (24 weeks)	Sandalwood essential oil mean \pm SD (24 weeks)	p- value
Facial spot	63.67 \pm 25.92	64.60 \pm 20.85	58.67 \pm 22.68	53.53 \pm 22.37	0.050*
Pore size	83.80 \pm 12.92	73.60 \pm 15.88	68.80 \pm 18.17	73.07 \pm 13.68	0.009*
Skin roughness	90.93 \pm 13.19	84.47 \pm 25.70	87.20 \pm 15.85	85.33 \pm 11.88	0.166
Facial wrinkles	71.27 \pm 21.59	72.27 \pm 20.05	66.87 \pm 20.61	72.53 \pm 22.49	0.773
UV acne	18.27 \pm 17.61	16.87 \pm 14.98	23.53 \pm 23.67	15.40 \pm 8.95	0.561
UV facial spot	90.80 \pm 10.83	88.73 \pm 15.32	83.33 \pm 18.48	78.87 \pm 22.22	0.050*
UV moisture lev	94.07 \pm 6.79	95.53 \pm 0.743	91.93 \pm 10.07	85.07 \pm 18.53	0.088

* $p < 0.05$ was considered statistically significant

Changes in skin parameters over time among all groups

Variations in skin parameters among those treated with lemon oil, sandalwood oil and the control groups based at different consultations, are shown (Figure 4.3a-g). There was a statistical significant improvement noted in facial spots ($p=0.01$) with those on the sandalwood treatment in contrast to lemon oil. Similarly, a statistically significant difference was noted for pore size ($p = 0.001$) in those treated with sandalwood oil in comparison to those on lemon oil.

Sandalwood oil showed A statistically significant difference was observed for sandalwood in reducing skin roughness ($p = 0.001$) in comparison to those treated with lemon oil. Although lemon treatment oil was successful in demonstrating an overall improvement, skin roughness within this group increased over time. In contrast, facial wrinkles were significantly reduced among those on the lemon treatment ($p = 0.031$) compared to sandalwood oil. Significant quadratic changes were observed for all UV factors among those treated with sandalwood oil. Improvements were further noted in UV acne incidences ($p = 0.022$), while UV spots showed a significance difference ($p = 0.133$). UV moisture levels within the skin also displayed improvements ($p = 0.209$).

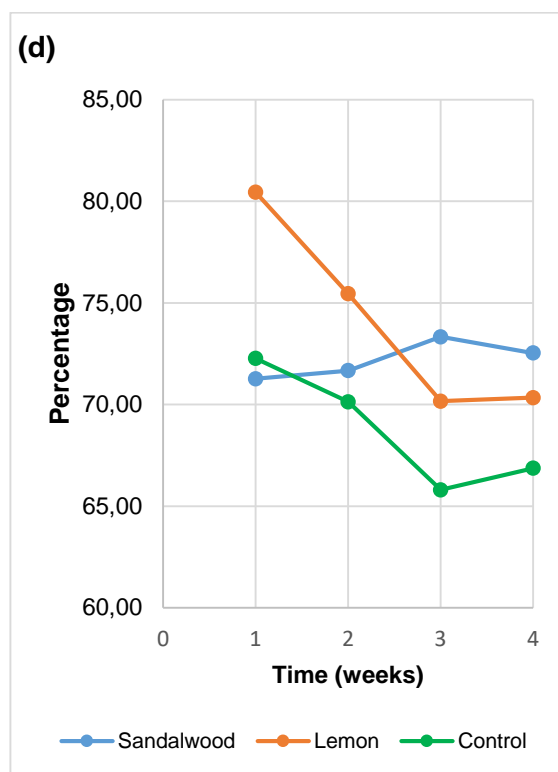
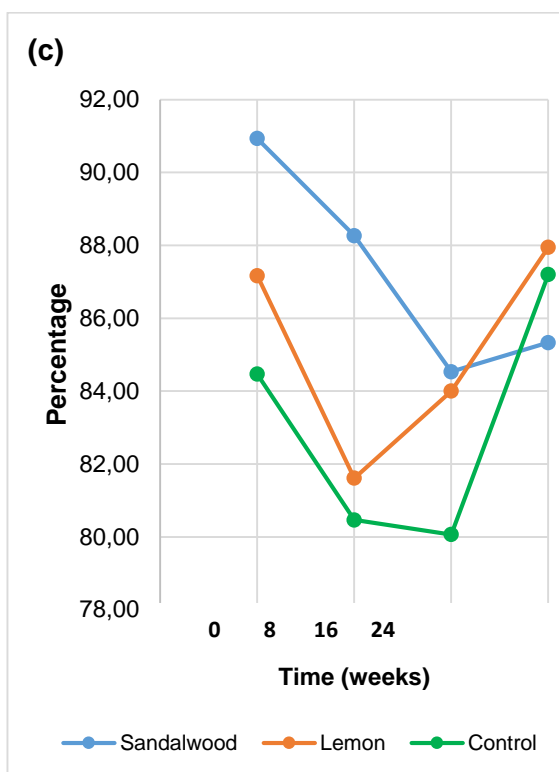
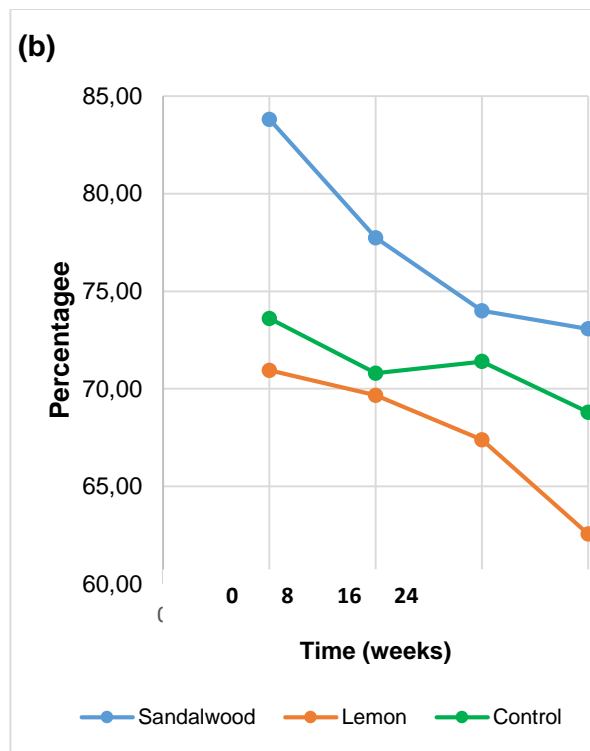
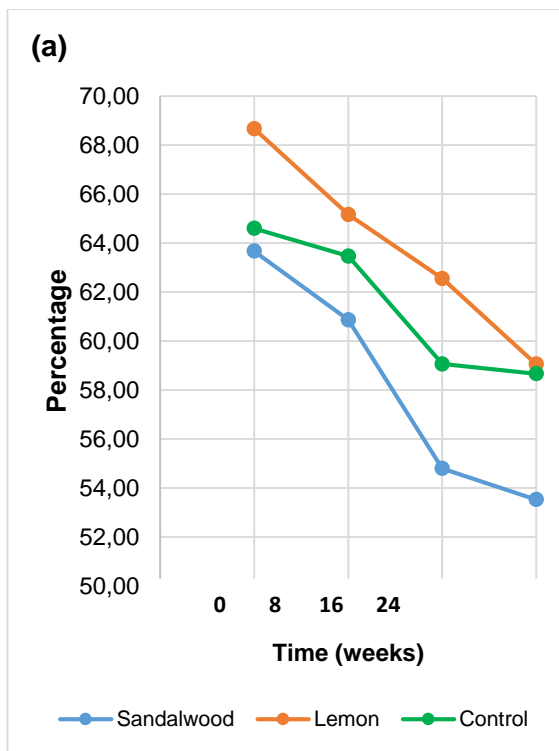


Figure 0.2: Images illustrating the changes in the percentages of the skin parameters over time in the treatment and control groups, (a) facial spot, (b) pore size, (c) skin roughness, and (d) facial wrinkles

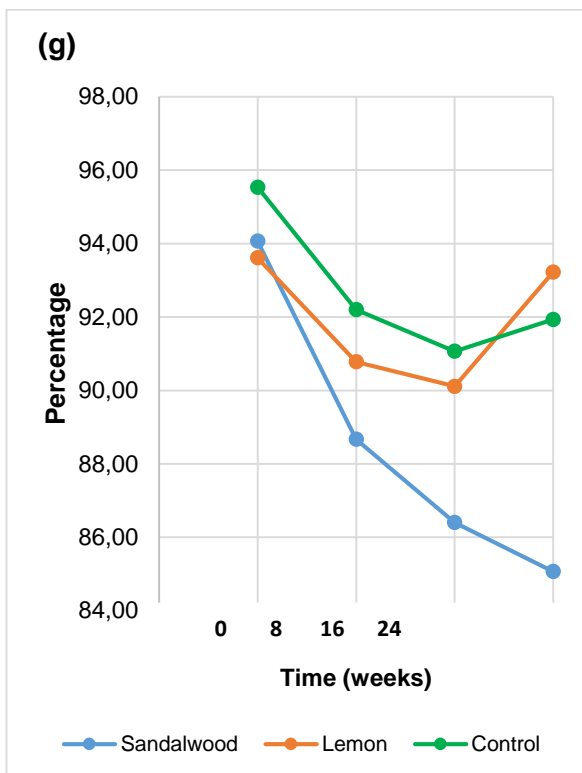
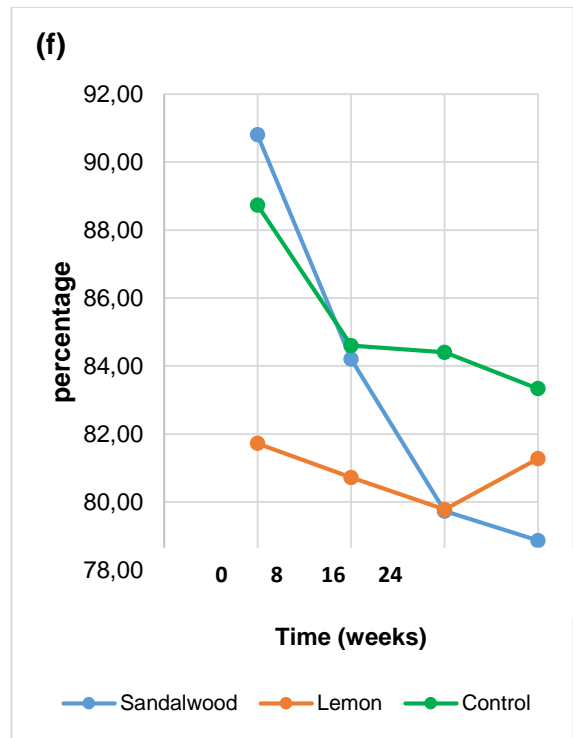
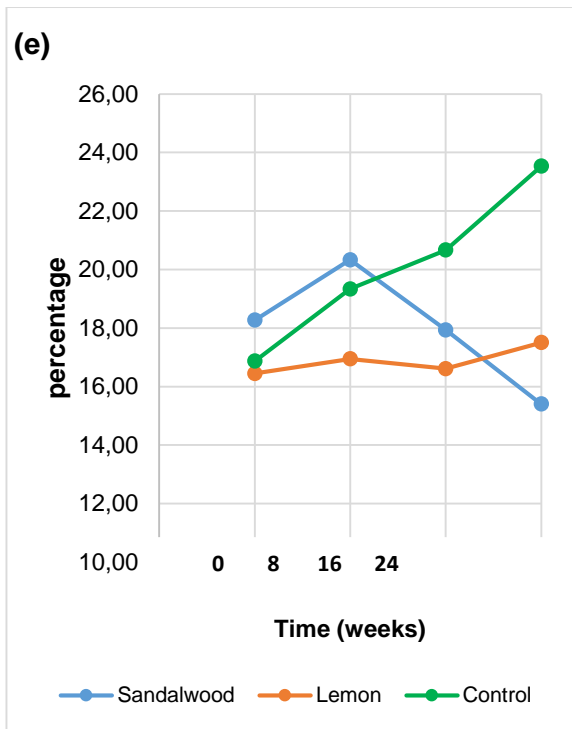


Figure 0.5: Images illustrating the changes in the percentages of the skin parameters over time in the treatment and control groups, (a) UV acne, (b) UV spot, (c) UV moisture

Discussion

Students enrolled at a university, average between 18-22 years, considered young mature aged, making up majority of the university population (Mallman and Lee 2017; Sitek, Źądzińska and Rosset 2012). Age, race and increased hormonal factors that influence PIH are high within this cohort, endorsing their susceptibility to PIH. The prevalence of acne was 83%. A key contributor to PIH development was acne. It affects over 90% adolescents, and persists into adulthood (Fabbrocini et al. 2010). A recent report suggested that both psychological and social outcomes affects almost 85% of people aged between 12-24 years are (Luqman 2019). A large proportion of our population presented with acne, which was similar to that reported by Sitek, Źądzińska and Rosset (2012). Sitek's group emphasised that career choice decisions combined with financial and family problems, are major contributors to PIH development and progression within this age group. This age group is also more vulnerable to being young parents and increased contraceptive use (Kubiak and Rotsztejn 2012). The use of contraceptives is associated with hormone replacements and increased melanin production, which consequently results in PIH development (Eliason et al. 2014). Others have also demonstrated increased melanin production as the contributing factor for various pigmentary disorders, including PIH (Mahdalena, Jusuf and Putra 2018; Natale et al. 2016). Hormones involved in pregnancy progression exerts similar effects on the non-pregnant female (Kubiak and Rotsztejn 2012), hence, pregnant woman and woman on contraception were excluded. 20% of participants were young mothers and presented with existing pigmentation.

Our study demonstrated a reduction in the appearance and features of UV acne among those that were on prior treatment in contrast to those that were not. Cutaneous injuries and inflammation such as acne often lead to PIH (Callender *et al.* 2011). Acne is characterised by large sebaceous glands and increased sebum production. Acne was found mainly around the face and on the upper trunk regions in our cohort. Our data concurs with Tanghetti *et al.* 2014 who found similar characteristics in their cohort.

Post-acne pigmentation and pigmented scars are usually outcomes of acne scarring (Al Qarqaz and Al-Yousef 2018). In our cohort, varying stages of acne and observable scarring was noted. Scarring, particularly on the facial regions is associated with reduced self-confidence which subsequently affects the quality of life. This consequently affects the morale of the affected individual resulting in low self-esteem and poor self-confidence (Thompson 2015).

Our study revealed sunburn as a possible main cause of PIH. Participants reported severe progression of their PIH when exposed to the sun. Exposure to the sun increases the production of vitamin D, which also depends on melanin for its production (Felton *et al.* 2016). Melanin synthesis occurs through the absorption and distribution of both UVA and UVB rays into the skin (Swalwell *et al.* 2014). Hence, increased melanin levels in dark skinned people predisposes them to absorb more vitamin D and UV rays (Bonilla *et al.* 2014). The effects of the blue light (modern technology) on skin pigmentation has recently emerged, however there is no literature supporting these effects.

The South African summer temperatures create unfavourable conditions for PIH patients (Wright *et al.* 2017). Ultraviolet radiation triggers uneven pigmentation in the skin (Young *et al.* 2009). Thus, it is possible that our participants who are mostly dark skinned may have been exposed to increased UV rays, which resulted in increased skin pigmentation. Sun protection is therefore highly recommended in the treatment of PIH, since it prevents its progression by protecting the skin against these harmful rays (Scheinfeld 2007). While the use of sun protection especially in the South African climate is well publicised, its awareness may be limited within the broader community. This lack of awareness may be a contributing factor in our cohort since many participants indicated an aggravation of their PIH during summer. However, it is also possible that those who may have used homecare remedies which potentially contained banned substances, increased their susceptibility to sunburn due to UV sensitivity.

Our data is in accordance with several others (Nordlund 2007; Moshammer, Simic and Haluza 2017) whose research showed that prohibited substances promote sunburn by thinning the outer layers of the skin, increasing sun exposure, thus promoting skin darkening. Others have also demonstrated that PIH is worsened among those not using sunblock, especially when exposed to the sun during summer months (Ruvolo *et al.* 2018), which is also consistent with our results. Our study found a high incidence of sunburn in the cohort of black African students. Dark skinned individuals are probably more susceptible to sunburn and PIH development. Several others report similar findings, suggesting that excess sun exposure results in severe sunburn and skin pigmentary disorders (Rodrigues and Pandya 2015, Nestor *et al.* 2014; Eimpunth, Wanitphadeedecha and Manuskiatti 2013). Incorporating SPF creams into daily regimens is essential in decreasing the progression of PIH. In our study, we provided RAD[®] (SPF 15), by Environ to all participants.

Our data highlighted that both lemon oil and sandalwood oil demonstrated an overall improved skin texture and appearance over time. While lemon oil positively improved the appearance of wrinkles, sandalwood significantly improved the sizes of facial spots and pore sizes. The presentation of skin roughness was also notably reduced for sandalwood oil in contrast to lemon oil. There was an overall improvement for all UV factors. Our results concur with others (Itoi-Ochi *et al.* 2016; Sharma *et al.* 2018; Reddy *et al.* 2011; Thakur, Negi and Kush 2013), who support the characteristics and actions of lemon and sandalwood in improving the overall skin appearance.

Limitations

High participant dropout rates due to the the study being conducted over a 24-week period. Participant were trusted to use the treatment daily and correctly as instructed. Due to the study being conducted within a university setting, almost all participants were students, hence lacking a variety of data received. The researcher did not take into the account the menstrual cycle of participants. Therefore, consultation results during this period would not be accurate and precise due to hormonal changes.

Conclusion

The prevalence of common factors that influence the onset of PIH such as age, race and increased hormonal factors are high within this cohort, endorsing their susceptibility to PIH development. Our data also highlights waxing as the preferred hair removal method. However, waxing predisposes women to inflammation, blockage of pores and burns, leading to PIH. Therefore the increased incidence of pigmentation in our study may be associated with the higher usage of waxing. Overall, visible improvements were demonstrated in the skin for both oils. We observed significant physiological changes in the pore sizes for both oils, and improved pore conditions with fewer enlarged and blocked pores. Thus, both groups showed a reduction in the prevalence of acne. Our data thus suggests that both oils may have a potential role in decreasing the development of acne and PIH.

Conflict of interest

The authors report no conflict of interest